ISSN 0976-6677

Kerala Journal of Ophthalmology

Editorial Board

Editor
Smita Narayanan

Associate Editor
Sinumol. S

Managing Editor
Rajiv Sukumaran

International Editors
Geeta Menon

Azim Siraj

Advisory Board
Anantharaman Giridhar

Sahsranamam V

Charles Skariah

Arup Chakrabarti

Mahadevan K

Section Editors
Sujatha N

Rani Balamurali

Manoj S

Natasha Radhakrishnan

Assistant Editors
Remya Raghavan

Ferzana Mohammed

Remya Edachery

Mentors
Ani Sreedhar

Minu Mathen

Ganesh V Raman

Elizabeth Joseph K

Thomas Cherian

Santosh G Honavar

Mahesh G

C V Anthrayose Kakkanatt

Somasheila Murthy

Emeritus Editors
Anantharaman Giridhar

Krishnankutty

NSD Raju

Ashok Nataraj

Mahadevan K

PI Mohan

Bastin VA

Mahesh G

Sudha V

Gopal S Pillai

Meena Chakrabarti

KE Eapen

Narayanankutty K

Cover Story:
'Butterfly Shaped' Old Retinal Detachment

Authors:
Dr. Prasanna Venkatesh Ramesh, Dr. Shruthy Vaishali Ramesh, Ms. Prajnya Ray, Mr. Aji Kunnath Devadas

Description:
The right eye (OD) fundus shows scattered subretinal pigmentary clumping of post retinal detachment (RD) flattened retina; in the structural form of a butterfly, which is usually seen in post exudative RDs. It is also known as leopard's spots, which is an uncommon but clinically distinct manifestation of various disorders. The causes need to be assessed and treated in a timely manner to prevent further secondary degeneration and vision loss.

Contributed by:
Dr. Prasanna Venkatesh Ramesh, Department of Glaucoma and Research Mahathma Eye Hospital Private Limited, Trichy, Tamil Nadu, India

Kerala Journal of Ophthalmology

Volume 34 Issue 1 January-April 2022

Contents

Editorial

KJO and the Ophthalmologists of Kerala
Smita Narayanan 1

Guest Editorials

Ushering in the era of MIGS in India
Vanita Pathak-Ray 3

How to minimize litigations and medical malpractice claims during ophthalmic practice?
Suresh K. Pandey 8

Review Article

Refractive Corneal surgeries: A Review
Jyothi Vengalil Menon 12

Ophtha Insta

Dense fibrin membrane mimicking anterior dislocated lens
Shivraj Tagare, Harsh Vardhan Singh, Iva Rani Kalita 19

Original Articles

Atropine in myopia – Does it reduce progression? Results of Phase 1 clinical trial in children attending a tertiary eye care center in South India
R. Neena, Ayshathu Nasheetha, Nimmy Prakash, Anantharaman Giridhar 21

Agreement of gonioscopy and anterior segment-optical coherence tomography in the assessment of the anterior chamber angle: A cross-sectional study
K. Jaseena, P. S. Rekha 27

Demographical and etiological diagnosis of infective corneal ulcer in a tertiary care center in West Bengal: A cross-sectional study
Garvita Joshi, Pinaki Sengupta, Anindya Gupta 32

Factors associated with poor prognosis in corneal ulcer: A clinical and epidemiological study
Mini Mathew, A. R. Arya, Ajith Cherian 37

A study on ocular symptomatology and clinical profile of coronavirus disease-19 positive patients admitted at a tertiary care institute in South India
Shruthi Bidari, Roshni Robert, B. Abhilash, Mahesh Babu, M. S. Mashitha 42

Spectrum of herpetic eye disease during COVID-19 pandemic
Shruti Bhat, Pallavi Joshi, Anand Balasubramaniam, Yash Gala 47

Case Series

Neuro-ophthalmic manifestations of central nervous system tuberculosis: Compilation of three diverse unique presentations
Harsha Sammer Pagad, Rishwa Hariyani, Akash Jain, Nita Shanbhag 51

Ethambutol-induced optic neuropathy: A case series
Anna Elias, R. Neena, A. Giridhar 55

Case Reports

Custard apple-induced toxic keratopathy
R. Sruthi, G. S. Kalaimathi, Vinay S. Pillai 62

A rare case of Vogt–Koyanagi–Harada disease presenting simultaneously with pituitary macroadenoma
Pradeep Kumar Panigrahi 65

Case of multiple sclerosis presenting as unilateral internuclear ophthalmoplegia
Aishwarya M. Angadi 68

Photo Essay

Pachychoroid disease mimicking pattern dystrophy
Soman Manoj, Sameer Iqbal, Padmanaban Meleth, Unnikrishnan Nair R 71

A white daisy on intraocular lens
Prateek Jain, Pooja Sah, Anshuman Pattnaik 74

Statistics Corner

Variables and risk
Smita Narayanan 76

Journal Reviews

Aishwarya Sadanand 79

Allen Mathew 81

PG Corner

Corneal biopsy
R. B. Radhika Krishnan 84

Letters to the Editor

Dilemma of diagnostic criteria
Anubhav Chauhan, Deepak Kumar Sharma 87

Continuing the service despite the pandemic: Ocular surgery on a COVID-19 patient
Karthikeyan Mahalingam, Somya Kumari, Monika Arora, Ramanjit Sihota 88

Kerala Journal of Ophthalmology

General Information

The journal
Kerala Journal of Ophthalmology (KJO), the official publication of Kerala Society of Ophthalmic Surgeons (KSOS) is published as print and online journal.

Abstracting and Indexing information
Baidu Scholar, CNKI (China National Knowledge Infrastructure), EBSCO Publishing's Electronic Databases, Ex Libris – Primo Central, Google Scholar, Hinari, Infotrieve, National Science Library, ProQuest, TdNet, Wanfang Data

The journal is indexed with, or included in, the following:

DOAJ

Information for Authors
There are no page charges for submissions to the journals. Please check http://www.kjophthal.com/contributors.asp for details.

All manuscripts must be submitted online at www.journalonweb.com/kjo.

Subscription Information
Copies are provided free of cost to members of KSOS. A subscription comprises of 3 issues every year. Please include postage.

Annual subscription rates for non-members

Institutional - INR 1200.00 for India and USD 100.00 for outside India
Personal - INR 600.00 for India and USD 50.00 for outside India
For mode of payment and other details, please visit www.medknow.com/subscribe.asp.

Claims for missing issues will be serviced at no charge if received within 60 days of the cover date for domestic subscribers, and 3 months for subscribers outside India. Duplicate copies cannot be sent to replace issues not delivered because of failure to notify publisher of change of address.

The journal is published and distributed by Wolters Kluwer India Private Limited. Copies are sent to subscribers directly from the publisher's address. It is illegal to acquire copies from any other source. If a copy is received for personal use as a member of the association/society, one cannot resale or give-away the copy for commercial or library use.

The copies of the journal to the members of the association are sent by ordinary post. The editorial board, association or publisher will not be responsible for non receipt of copies. If any member/subscriber wishes to receive the copies by registered post or courier, kindly contact the publisher's office. If a copy returns due to incomplete, incorrect or changed address of a member/subscriber on two consecutive occasions, the names of such members will be deleted from the mailing list of the journal. Providing complete, correct and up-to-date address is the responsibility of the member/subscriber.

Nonmembers: Please send change of address information to wkhlrpmedknow_subscriptions@wolterskluwer.com.

Advertising policies
The journal accepts display and classified advertising. Frequency discounts and special positions are available. Inquiries about advertising should be sent to Wolters Kluwer India Private Limited, advertise@medknow.com.

The journal reserves the right to reject any advertisement considered unsuitable according to the set policies of the journal.

The appearance of advertising or product information in the various sections in the journal does not constitute an endorsement or approval by the journal and/or its publisher of the quality or value of the said product or of claims made for it by its manufacturer.

Copyright
The entire contents of the Kerala Journal of Ophthalmology are protected under Indian and international copyrights. The Journal, however, grants to all users a free, irrevocable, worldwide, perpetual right of access to, and a license to copy, use, distribute, perform and display the work publicly and to make and distribute derivative works in any digital medium for any reasonable non-commercial purpose, subject to proper attribution of authorship and ownership of the rights. The journal also grants the right to make small numbers of printed copies for their personal non-commercial use.

Permissions
For information on how to request permissions to reproduce articles/information from this journal, please visit www.kjophthal.com

Disclaimer
The information and opinions presented in the Journal reflect the views of the authors and not of the Journal or its Editorial Board or the Publisher. Publication does not constitute endorsement by the journal. Neither the Kerala Journal of Ophthalmology nor its publishers nor anyone else involved in creating, producing or delivering the Kerala Journal of Ophthalmology or the materials contained therein, assumes any liability or responsibility for the accuracy, completeness, or usefulness of any information provided in the Kerala Journal of Ophthalmology, nor shall they be liable for any direct, indirect, incidental, special, consequential or punitive damages arising out of the use of the Kerala Journal of Ophthalmology. The Kerala Journal of Ophthalmology, nor its publishers, nor any other party involved in the preparation of material contained in the Kerala Journal of Ophthalmology represents or warrants that the information contained herein is in every respect accurate or complete, and they are not responsible for any errors or omissions or for the results obtained from the use of such material. Readers are encouraged to confirm the information contained herein with other sources.

Address
Editorial Office
Dr. Smita Narayanan
M S (Ophthalmology)
Regional Institute of Ophthalmology, Thiruvananthapuram, Kerala, India.
Email: drsmita.narendranath@gmail.com
Phone: 9446430633

Published by
Wolters Kluwer India Private Limited.
A-202, 2nd Floor, The Qube, C.T.S. No.1498A/2 Village Marol, Andheri (East), Mumbai - 400 059, India.
Phone: 91-22-66491818
Website: www.medknow.com

Printed at:
Nikeda Art Printers Pvt Ltd.
Bhandup (W), Mumbai, India.

Editorial

KJO and the Ophthalmologists of Kerala

Dear Friends,

A new Editorial team takes charge of this issue. A lot of our tasks have been made easier by the hard work of the previous teams, especially that of our immediate predecessor. Our team expresses its gratitude for the fine work done by all the previous editorial teams. The *Kerala Journal of Ophthalmology* has set new standards, be it in the cover design, quality of editing, or in the content it provides. It is heartening to know that a real interest in the journal has been generated in recent times.

However, a detailed evaluation of the submitted manuscripts in the past few years shows that the contribution of the 2000 and more practicing ophthalmologists of Kerala has been miniscule. This is a point all of us must ponder. Therefore, paraphrasing Thich Nhat Hanh, we need action that is rooted in a practice that responds to ophthalmologists' needs.[1] A cursory analysis of the reasons for such misalignment in a state which is highly active in scientific platforms reveals a few points which need to be debated upon.

POOR KNOWLEDGE ABOUT MANUSCRIPT WRITING AND STATISTICAL PRINCIPLES

There are many teachers, especially in educational institutions who did not learn research methodology, statistical principles, and manuscript writing during their postgraduation days. Hence, even though they conduct exemplary clinical work, they do not apply the same rigor to the research activities of their proteges. The result is therefore shoddy and mediocre and yet they are baffled by the rejections.

Our journal has been carrying out review articles on research methodology for the past many issues. We plan to simplify it further by bringing in small statistics modules. The Journal Club feature will be retained with a postgraduate student summing up the discussion. We all know that actual practice brings greater proficiency and hopefully, the new journal club in the KSOS website will ensure greater participation and spur the interest in scientific writing.

RELUCTANCE OR RESISTANCE TO SHARE CLINICAL RESEARCH WITH OTHERS

We now know more and base our treatment guidelines on the research work of our neighboring states than ours. There is scarce documentation about pertinent and ophthalmologically relevant material concerning Kerala. As William J Dupps Jr rightly said,

"You don't know what you don't know."[2]

This reluctance for sharing knowledge will lead to speculations and impair the quality of crucial data. It is important that we network with fellow ophthalmologists and researchers because, finally, it will help us individually and help our institutions grow. Collaboration among scientists, medical professionals, and technical experts will help big data analytics, machine learning, artificial intelligence, and ophthalmological clinical research to come together to benefit our patients.[3]

IMMENSE WORKLOAD AND LESSER TIME TO DO CLINICAL RESEARCH

Many of our institutions are neck-deep in work and COVID-19 has made matters worse. However, there are others who are thirsting for work. We need to come out with solutions to address this dichotomy. Most importantly, we need to come out of our complacency and comfort zones and convert the concept of clinician-researcher into reality. A notebook to jot down clinically important observations daily will help us to select topics for clinical research. Documenting findings is another important process. Even if a topic has been already reported upon, we can write about our own experience and down the line when a few others from our state publish on the same topic, another one of us can perform a meta-analysis and present the findings particular to our state.

THE KJO ADVANTAGE

Scientific inquiry requires us to create a hypothesis, obtain data on the variables in the hypothesis, revise the hypothesis if needed, and conduct peer review. This process of scientific rigor, especially the peer review process is very important to obtain meaningful scientific literature and one should not get overwhelmed by it. Let us go back to the old-fashioned way of not taking shortcuts and utilize our own journal to the maximum. KJO will try to simplify the process of manuscript submission and decrease the duration of the article cycle even further. We also request further suggestions in this regard in the forms of Letters to Editor.

© 2022 Kerala Journal of Ophthalmology | Published by Wolters Kluwer - Medknow

"Only a few know, how much one must know to know how little one knows."

Werner Heisenberg

VISION FOR EVERYONE

In a landmark "first-ever resolution on vision," the UN General Assembly has unanimously adopted a resolution designed to tackle eye disease and enhance global efforts to help at least 1.1 billion people who have vision impairment and who currently lack access to eye care services they need. Its 193 member nations have committed themselves to ensure eye care for everyone by 2030. The resolution calls for new targets on eye care to be included in the UN's Sustainable Development Goals at its next review.[4]

The assembly has further called upon member states and other stakeholders to include persons with disabilities including those with visual impairment in all stages of policymaking and decision-making as well as to eliminate barriers and discrimination against persons with disabilities. This is a very important decision in a world body.

Since this resolution has a target that is not too far, a more concerted effort to promote eye health will more likely be adopted. The idea to link vision to other development priorities is commendable. This is because about 90% of preventable vision loss occurs in developing countries, of which more than half of it affects women and girls. The concerted action of the UN, the governments of the member countries, donors, and the civil and scientific community will help in reducing the loss of social and economic opportunities for people around the world due to eye conditions.

Smita Narayanan
Additional Professor, Regional Institute of Ophthalmology, Thiruvananthapuram, Kerala, India

Address for correspondence: Dr. Smita Narayanan, Regional Institute of Ophthalmology, Thiruvananthapuram, Kerala, India.
E-mail: drsmita.narendranath@gmail.com

REFERENCES

1. Hanh NT. At Home in the World. UK: Penguin Random House; 2016: p. 40-2.
2. Dupps WJ Jr. You don't know what you don't know. JCRS 2019;45:1057-8.
3. Wu X, Huang Y, Liu Z, Lai W, Long E, Zhang K, *et al.* Universal artificial intelligence platform for collaborative management of cataracts. Br J Ophthalmol 2019;103:1553-60.
4. Available from: https://www.iapb.org/advocate/eye-health-and-sdgs/united-nations-general-assembly-resolution-on-vision. [Last accessed on 2022 Jan 19].

This is an open access journal, and articles are distributed under the terms of the Creative Commons Attribution-NonCommercial-ShareAlike 4.0 License, which allows others to remix, tweak, and build upon the work non-commercially, as long as appropriate credit is given and the new creations are licensed under the identical terms.

Submitted: 27-Jan-2022 **Revised:** 28-Jan-2022
Accepted: 28-Jan-2022 **Published:** 21-Apr-2022

Access this article online	
Website: www.kjophthal.com	Quick Response Code
DOI: 10.4103/kjo.kjo_15_22	

How to cite this article: Narayanan S. KJO and the ophthalmologists of Kerala. Kerala J Ophthalmol 2022;34:1-2.

Guest Editorial

Ushering in the era of MIGS in India



ABSTRACT

Incisional filtration surgery with bleb formation has been the mainstay of glaucoma surgery for decades and is particularly useful in progressing or advanced glaucoma. However, the flipside of these procedures is the sight-threatening complications that may occur. Minimally Invasive Glaucoma Surgery has made in-roads in the past two decades – these are known to be high on the safety aspect and therefore can be used much earlier on in the disease spectrum. Some of these relatively new devices and procedures are now available in India also.

Keywords: Cycloablation, endoscopic cyclophotocoagulation, gonioscopy-assisted transluminal trabeculotomy, iStent, micropulse diode, MIGS, minimally invasive glaucoma surgery, trabecular meshwork, trabeculotomy

INTRODUCTION

Glaucoma encompasses a heterogeneous group of diseases that are identified by a characteristic chronic optic neuropathy with correlating visual field defect/s. Although several risk factors are known, intraocular pressure (IOP) is the most important one as it is the only modifiable one. Therefore, all management modalities – medical, laser, or surgical, are directed toward IOP alone. Medical management is the mainstay of treatment for the majority, but a significant proportion of glaucoma patients require a surgical procedure for the control of the disease. Up until recently, surgical procedures that were available included only those that drained in the subconjunctival space [Figure 1A] (trabeculectomy and glaucoma drainage devices). Although efficacious, it is precisely this manner of drainage with the creation of a bleb that is responsible for either failure due to fibrosis or long-term sight-threatening sequelae (hypotony, leakage, infection, etc.) or both. It is perhaps this morbidity associated with these procedures which is the prime determinant of its use mostly in medically resistant, refractory, and usually advanced glaucoma. However, over the past two decades, several innovative procedures and devices[1,2] have spawned out of a concern for increased safety in glaucoma surgery such that it can be offered to the patient much earlier on in the disease spectrum, especially in combination with cataract surgery. These are called minimally or microinvasive glaucoma surgery (MIGS). Minimally invasive procedures are the way forward not only in ophthalmology (extracapsular

Vanita Pathak-Ray

Centre for Sight, Hyderabad, Telangana, India

Address for correspondence: Dr. Vanita Pathak-Ray, Centre for Sight, Road No. 2 Banjara Hills, Hyderabad - 500 034, Telangana, India.
E-mail: vpathakray@gmail.com

Submitted: 03-Feb-2022 **Revised:** 27-Feb-2022
Accepted: 03-Mar-2022 **Published:** 21-Apr-2022

Access this article online	
Website: www.kjophthal.com	Quick Response Code
DOI: 10.4103/kjo.kjo_13_22	

This is an open access journal, and articles are distributed under the terms of the Creative Commons Attribution-NonCommercial-ShareAlike 4.0 License, which allows others to remix, tweak, and build upon the work non-commercially, as long as appropriate credit is given and the new creations are licensed under the identical terms.

For reprints contact: WKHLRPMedknow_reprints@wolterskluwer.com

How to cite this article: Pathak-Ray V. Ushering in the era of MIGS in India. Kerala J Ophthalmol 2022;34:3-7.

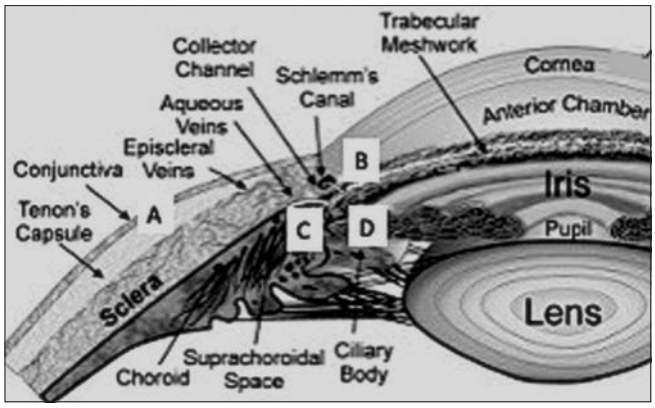

Figure 1: Section of the eye showing subconjunctival drainage (A) and through the trabecular meshwork (B) along with suprachoroidal space (C) as well as the ciliary body (D)

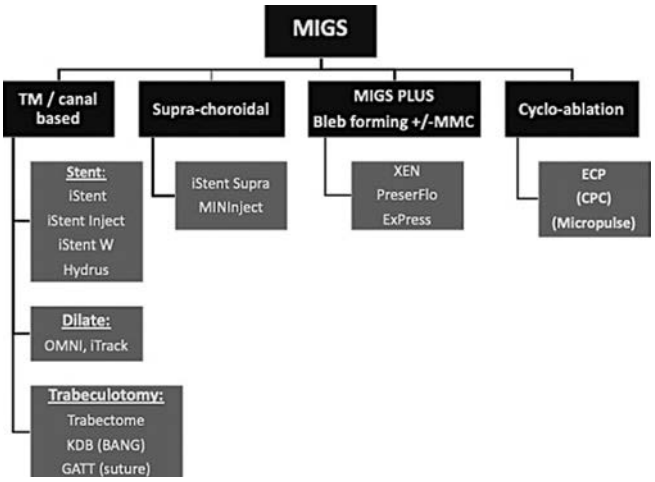

Figure 2: Classification of minimally invasive glaucoma surgery

cataract surgery being replaced by microincisional cataract surgery, Descemet membrane endothelial keratoplasty vs. penetrating keratoplasty, etc.) but also in other surgical specialties too. For instance, in spinal surgery, conventional fusion techniques have now been replaced with prostheses with better outcomes, even though it comes at a much greater cost.

WHAT IS MIGS?

"MIGS" is a term applied to a wide range of implants, devices, and techniques that lower IOP with less surgical risk than the more established bleb-forming procedures (trabeculectomy, glaucoma drainage devices viz. Ahmed glaucoma valve, Aurolab aqueous drainage implant).

Such a surgery usually tends to have the following characteristics: less or minimally invasive or traumatic to the conjunctiva (there are exceptions – e.g., XEN, PreserFlo), usually "ab-interno," usually bleb-independent, usually combined with cataract surgery with reduced surgical time, rapid visual recovery, and high safety profile. These latter characteristics along with the fact that they are cosmetically more acceptable too, make these procedures very patient-friendly.

The Food and Drug Administration or FDA (of the USA) described MIGS as "a type of IOP-lowering device used to lower IOP using an outflow mechanism with either an ab-interno or ab-externo approach, associated with little or no scleral dissection and minimal or no conjunctival manipulation."[3]

WHAT ARE THE TYPES OF MIGS?

MIGS devices and procedures utilize the hitherto surgically untapped pathways of drainage including the trabecular meshwork (TM) [Figure 1B], suprachoroidal space [Figure 1C], and also targets the seat of aqueous production – the ciliary body (CB) itself [Figure 1D]. While the former two pathways need an open angle, the cycloablative procedures targeting the CB can be used independent of angle status. Therefore, the devices and procedures [Figure 2] may be categorized as those that increase trabecular outflow through the Schlemm's canal (SC) – which can be stented with iStent®, iStent® Inject, or iStent® Inject W (all Glaukos Corp, CA, USA) or with the Hydrus (Alcon, Tx, USA). Or it can be dilated with OMNI (Sight Sciences Inc. CA, USA) and iTrack (Nova Eye Medical, SA). Or a trabeculotomy can be done with several devices and procedures – Trabectome (NeoMedix Corporation, CA, USA), Kahook Dual Blade (New World Medical, CA, USA), or a 360° trabeculotomy can be performed by doing a gonioscopy-assisted transluminal trabeculotomy (GATT) with an OMNI device. Devices that can be placed in the suprachoroidal space are iStent® Supra (Glaukos Corp, CA, USA), MINIject (iStar Medical, Belgium), etc. Cycloablation or cyclophotocoagulation can be done either by directly viewing and targeting the CB with the assistance of an endoscope (Beaver-Visitec International, MA, USA) or through the transscleral route with the micropulse diode (Iridex, CA, USA) causing less collateral thermal damage compared to the conventional continuous-wave one.

There is another group of devices categorized as MIGS-Plus as they do not strictly satisfy all criteria of MIGS because they drain into the subconjunctival space creating a bleb and therefore can demonstrate all complications related to this type of drainage. These include the XEN (Allergan, Dublin, Ireland) and PreserFlo (Santen, Osaka, Japan).

WHAT ARE THE INDICATIONS OF MIGS?

Mild-to-moderate open-angle glaucoma – be it primary open-angle glaucoma or pseudoexfoliation glaucoma or even

pigment dispersion syndrome. It is generally not indicated in primary angle-closure glaucoma unless the angle opens up post laser peripheral iridotomy. Intolerance to topical medications and other barriers for continued usage of antiglaucoma medications (AGMs), for example, allergy, poor compliance and adherence, concerns about lifelong cost of therapy, etc., are also indications for MIGS procedures.

WHAT IS THE EFFICACY OF MIGS?

Randomized control trials (RCTs)[4,5] and systematic reviews and meta-analyses[6-9] of several of these procedures, with or without cataract surgery, indicate that the IOP lowering efficacy lies in the range of 25%–40% at around 1-5 years follow-up and a reduction of medication of approximately 40%–50%. Generally, the subconjunctival bleb-forming devices have a greater reduction in IOP but also required more bleb-management in the postoperative period. Another systematic review[10] concluded that although MIGS is efficient in the reduction of both IOP and AGM and demonstrate a good safety profile but the evidence is mainly derived from noncomparative studies and that further good quality RCTs are warranted.

A recent overview of Cochrane systematic reviews[11] and network meta-analysis of MIGS in open-angle glaucoma reported that some MIGS may afford patients greater drop-free disease control than cataract surgery alone.

A position paper on MIGS[12] published by the American Glaucoma Society favored patient access to these procedures and also those efforts that permit the clinician and patient to decide jointly which intervention(s) along the entire spectrum of care are best for them based on their unique circumstances.

WHAT ARE THE COMPLICATIONS OF MIGS?

Complications associated with MIGS are usually infrequent and mostly transient due to the less-invasive approach compared to trabeculectomy and tube shunt surgery.[13] Hyphema due to reflux occurs commonly after TM procedures (up to 70%); acutely elevated IOP has been observed in 2%–21%, peripheral anterior synechiae and Descemet's membrane detachment have also been described. However, shallow or flat anterior chamber and hypotony are usually transient and choroidal effusion rarely occurs.

HOW IS MIGS DIFFERENT TO THE CURRENT GOLD STANDARD?

As stated before, there are several advantages of MIGS procedures and devices. As most of these devices and procedures are bleb-independent, risk of hypotony is low; other bleb-related complications and side-effects are also avoided, with the exception of subconjunctival filtering MIGS-Plus devices (XEN, PreserFlo). Thus, early and late bleb leak, blebitis, bleb-associated endophthalmitis, and bleb dysesthesia are all avertible. However, quite such as trabeculectomy, failure of bleb due to episcleral fibrosis is a real concern in subconjunctival MIGS-Plus filtering devices.

Other advantages include – shorter operating time, can be easily combined with phaco surgery, rapid recovery, and early visual rehabilitation without need for increased frequency of postoperative visit/s. Furthermore, they can be offered earlier on in the disease, rather than the need to wait for the disease to progress or become uncontrollable and/or advanced. Reduction in the use of AGM has the added advantage of increased compliance and adherence with improved quality of life. Being atraumatic to the conjunctiva, trabeculectomy can still be performed, should it be required in future.

The main disadvantage of these MIGS procedures is its modest ability to reduce IOP. There appears to be a downstream resistance to flow below 16 mmHg in the SC drainage routes – this presents a potential limitation of trabecular restoration in patients with glaucoma in the presence of normal aqueous inflow.[14] Further lowering requires additional aqueous suppression treatment, which can be a real disadvantage if low target IOP is indicated or medication use is to be avoided.

It is therefore generally not recommended in advanced disease, nor in situations where IOP is uncontrolled despite maximally tolerated medications. Furthermore, they require the additional skill of intraoperative gonioscopy. The cost of these devices can also be a barrier to its uptake.

TIPS FOR A SUCCESSFUL MIGS PROCEDURE

Successful implantation of a MIGS device (or procedure) demands a new set of skills, hitherto not taught or

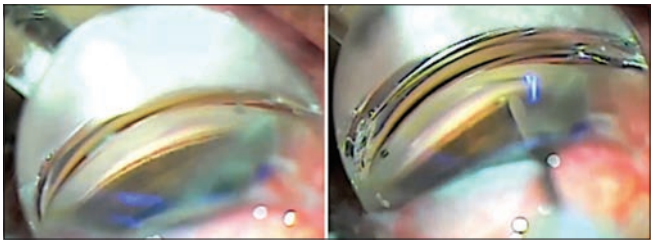

Figure 3: Intraoperative gonioscopy with wide open-angle and "en-face" visibility of the trabecular meshwork (left) and iStent® trabecular micro-bypass being implanted (right)

sparingly imparted in our training programs. The single most important aspect is the practice of intraoperative gonioscopy with a direct gonio lens and the familiarization of the angle structures under high magnification, and the ability to demonstrate forward-facing or "en-face" view of the TM [Figure 3, left]. For this purpose and for best visualization, the microscope needs to be rotated 35° toward the surgeon and the patient's head (and eye) has to be turned 35° away from the surgeon. Furthermore, a temporal approach is best suited for MIGS procedures. Preprocedure, preplanned intraoperative gonioscopy in this manner in several routine temporal incision phaco alone procedures go a long way in the preparedness for the actual procedure.

HOW RELEVANT IS MIGS IN INDIA?

Poor and variable availability of specialized health care, late access and presentation, affordability, and greater occurrence of angle-closure disease when compared to developed nations are all factors that contribute to increased glaucoma-related morbidity in a country like ours. Even though MIGS procedures are desirable as they are bleb-independent with a better safety profile, on the face of it, for all the reasons stated, its use in our population may appear to be limited. However, a significant proportion of ocular hypertensives or early glaucoma patients, who are on multiple AGM and are due to undergo cataract surgery may be offered MIGS along with it. Another group of patients seem to be emerging – those that are intolerant to multiple AGM – they too will benefit from conjunctiva-sparing procedures, as blebs tend to fail in such eyes. In any case, a bleb-producing invasive procedure may seem excessive in both these scenarios. Furthermore, as conjunctiva is not disturbed, MIGS do not compromise future filtration, if required.

However, the expense may be a major consideration, especially in developing countries. Furthermore, with the exception of cyclophotocoagulation, these devices and procedures do not have relevance in synechiae angle closure. Nonetheless, when seen from the perspective of the patient, it not only improves their quality of life with none or fewer AGM but also lesser postoperative visits and faster visual rehabilitation postsurgery.

Currently, there is limited availability of MIGS devices and procedures in India when compared to the Western world. The MIGS that is available consist of mainly those that target the TM to unroof the SC or those that ablate the CB. Most of the MIGS that target the TM are the low-cost versions of their Western counterparts – use of prolene suture in GATT for 360° unroofing of SC versus OMNI and use of a bent needle in BANG or Bent-needle Ab-interno Goniectomy instead of KDB (regulatory approvals not yet granted in India) to perform a trabeculotomy. The Trabectome is available in some centers, but the electrocautery probe is disposable in nature and incurs a recurrent cost, even after the capital expenditure (capex) is made for the acquisition of the machine.

The cycloablative diode procedures – endoscopic or transscleral micropulse diode – require capex too; the former utilizes a reusable probe obviating recurrent cost, but not the latter.

The newest entrant in the world of MIGS in India is the iStent® and iStent® Inject (Glaukos Corp, CA, USA) – the very first procedure was done in September 2021 [Figure 3, right]. These are the smallest devices known to humankind and are considered trabecular micro-bypass.

There is a paucity of data related to MIGS procedures in Indian eyes, few are available but mainly in cycloablative procedures. Endoscopic cycloablation can be considered the "original" MIGS, as it was described by Uram[15] in the early 1990s. It has achieved moderate success in open-angle glaucomas[16] (and refractory too) but its value seems to be in primary angle-closure disease, the real scourge of our country, where it may prove to be a game changer.[17-22] Micropulse diode may also prove beneficial[23,24] but there is a need to build up more evidence in primary glaucomas.

In summary, due to its enhanced safety profile, even though IOP control is modest, MIGS devices are designed to address the treatment gap that exists between medical therapy and the more aggressive traditional surgical options. They also help to decrease the AGM burden and therefore impact positively on compliance and adherence issues in glaucoma therapy. MIGS devices are expensive largely due to the research and development costs being recouped by the industry that developed them. On the other hand, ophthalmologists tend to be dismissive of it primarily citing the cost, without actually performing a single procedure of MIGS. For the purpose of bridging the gap between medical therapy and the leap to incisional surgery, ophthalmologists providing glaucoma care will need to overhaul current practices in the management of the disease and invest time and effort in the learning of intraoperative gonioscopy-based MIGS procedures. Therefore, the cost may not be the greatest limiting factor in the widespread adoption of MIGS in a country like ours.

Financial support and sponsorship
Nil.

Conflicts of interest

There are no conflicts of interest.

REFERENCES

1. Saheb H, Ahmed II. Micro-invasive glaucoma surgery: Current perspectives and future directions. Curr Opin Ophthalmol 2012;23:96-104.
2. Pathak-Ray V. Advances in glaucoma surgery: Paradigm shift in management. Oman J Ophthalmol 2016;9:1-2.
3. Premarket Studies of Implantable Minimally Invasive Glaucoma Surgical (MIGS) devices: Guidance for Food and Drug Administration Staff. US Food and Drug Administration. Available from: https://bit.ly/2L95zwp. [Last accessed on 2015 Dec 15].
4. Ventura-Abreu N, García-Feijoo J, Pazos M, Biarnés M, Morales-Fernández L, Martínez-de-la-Casa JM. Twelve-month results of ab interno trabeculectomy with Kahook Dual Blade: An interventional, randomized, controlled clinical study. Graefes Arch Clin Exp Ophthalmol 2021;259:2771-81.
5. Samuelson TW, Chang DF, Marquis R, Flowers B, Lim KS, Ahmed II, *et al*. HORIZON investigators. A schlemm canal microstent for intraocular pressure reduction in primary open-angle glaucoma and cataract: The HORIZON study. Ophthalmol 2019;126:29-37.
6. Healey PR, Clement CI, Kerr NM, Tilden D, Aghajanian L. Standalone iStent trabecular micro-bypass glaucoma surgery: A systematic review and meta-analysis. J Glaucoma 2021;30:606-20.
7. Gillmann K, Mansouri K. Minimally invasive glaucoma surgery: Where is the evidence? Asia Pac J Ophthalmol (Phila) 2020;9:203-14.
8. Guo CY, Qi XH, Qi JM. Systematic review and meta-analysis of treating open angle glaucoma with gonioscopy-assisted transluminal trabeculotomy. Int J Ophthalmol 2020;13:317-24.
9. Kaplowitz K, Bussel II, Honkanen R, Schuman JS, Loewen NA. Review and meta-analysis of ab-interno trabeculectomy outcomes. Br J Ophthalmol 2016;100:594-600.
10. Lavia C, Dallorto L, Maule M, Ceccarelli M, Fea AM. Minimally-Invasive Glaucoma Surgeries (MIGS) for open angle glaucoma: A systematic review and meta-analysis. PLoS One 2017;12:e0183142.
11. Bicket AK, Le JT, Azuara-Blanco A, Gazzard G, Wormald R, Bunce C, *et al*. Minimally invasive glaucoma surgical techniques for open-angle glaucoma: An overview of cochrane systematic reviews and network meta-analysis. JAMA Ophthalmol 2021;139:983-9.
12. Fellman RL, Mattox C, Singh K, Flowers B, Francis BA, Robin AL, *et al*. American Glaucoma Society Position Paper: Microinvasive glaucoma surgery. Ophthalmol Glaucoma 2020;3:1-6.
13. Yook E, Vinod K, Panarelli JF. Complications of micro-invasive glaucoma surgery. Curr Opin Ophthalmol 2018;29:147-54.
14. Overby D. Basic science behind trabecular meshwork surgeries. Acta Ophthalmol 2013. [doi: 10.1111/j.1755-3768.2013.1734].
15. Uram M. Combined phacoemulsification, endoscopic ciliary process photocoagulation, and intraocular lens implantation in glaucoma management. Ophthalmic Surg 1995;26:346-52.
16. Francis BA, Berke SJ, Dustin L, Noecker R. Endoscopic cyclophotocoagulation combined with phacoemulsification versus phacoemulsification alone in medically controlled glaucoma. J Cataract Refract Surg 2014;40:1313-21.
17. Francis BA, Pouw A, Jenkins D, Babic K, Vakili G, Tan J, *et al*. Endoscopic Cycloplasty (ECPL) and lens extraction in the treatment of severe plateau iris syndrome. J Glaucoma 2016;25:e128-33.
18. Hollander DA, Pennesi ME, Alvarado JA. Management of plateau iris syndrome with cataract extraction and endoscopic cyclophotocoagulation. Exp Eye Res 2017;158:190-4.
19. Lin MM, Rageh A, Turalba AV, Lee H, Falkenstein IA, Hoguet AS, *et al*. Differential efficacy of combined phacoemulsification and endocyclophotocoagulation in open-angle glaucoma versus angle-closure glaucoma. J Glaucoma 2019;28:473-80.
20. Pathak-Ray V. Intermediate results of phaco-endocycloplasty in an exclusive cohort of angle closure glaucoma: Potential for change. Int Ophthalmol 2019;39:2257-65.
21. Pathak-Ray V, Choudhari N. Phaco-endocycloplasty versus Phacotrabeculectomy in primary angle-closure glaucoma: A prospective randomized study. Ophthalmol Glaucoma 2020;3:434-42.
22. Pathak-Ray V. Protocol for titrated endocycloplasty when combined with phacoemulsification in an exclusive cohort of angle closure glaucoma. J Glaucoma 2019;28:e177-8.
23. Ariga M, Nivean, Nivean PD, Madanagopalan VG, Mohan S. Micropulse trans-scleral diode laser cyclophotocoagulation in refractory glaucoma: An initial experience in Indian eyes. Int Ophthalmol 2021;41:2639-45.
24. Pathak Ray V. Micropulse transscleral cyclophotocoagulation Cyclo G6 laser at low energy levels: Initial results in Indian eyes with advanced glaucoma treated in a single session. Indian J Ophthalmol Case Rep 2021;1:292-6.

Guest Editorial

How to minimize litigations and medical malpractice claims during ophthalmic practice?



ABSTRACT

The health profession is considered to be one of the noblest professions in the world. While Indian medical infrastructure is being noticed and praised on the global map, on the contrary, the doctor-patient relationship is deteriorating, our internal medical setup is facing extensive problems with consumer cases/medical litigation fast becoming one of the most serious of all issues. The number of cases against ophthalmologists for malpractice is increasing. While very few cases may be legitimate and based on clinical negligence exercised by the doctors, most medical professionals are wrongfully accused because of the lack of public understanding. The eye care professionals must communicate empathetically, emphasize diligent service delivery and also maintain proper records about the patient history, examination, consent, treatment and follow-up, and referral. Eye camp surgery should be done only in the operation theater of the hospital set up and the permissible number of cataract-IOL surgery can be done following all checklist/protocols and precautions. Lawsuits for medical negligence in ophthalmic practice can be minimized or avoided by following surgical checklists, protocols, proper documentation (maintaining medical records), taking informed consent, communication about the cost and outcome of the procedure or treatment, timely referral of the patient (in case of any complication), and obtaining adequate professional liability insurance.

Keywords: Deteriorating doctor-patient relationship, Consumer Cases in Medical Practice, Medical Litigation,

"Medicine has become the art of managing extreme complexity and a test of whether such complexity can, in fact, be humanly mastered."

~ Dr. Atul Gawande, The Checklist Manifesto: How to Get Things Right

The medical profession is considered to be one of the noblest professions in the world. While Indian medical infrastructure is being noticed and praised on the global map, on the contrary, the doctor-patient relationship is deteriorating, our internal medical setup is facing extensive problems with medical litigation fast becoming one of the most serious of all issues. We live in a culture in which displeased patients have increasingly turned to litigation as a means of obtaining redress from perceived deficiencies in the quality of care received from their physicians. Exaggerated claims of miracle cures and widespread media publicity hinting at the wonders of newly developed medical technology have resulted in

Suresh K. Pandey

SuVi Eye Institute and Lasik Laser Center, Kota, Rajasthan, India

Address for correspondence: Dr. Suresh K. Pandey,
SuVi Eye Institute and Lasik Laser Center, C 13 Talwandi,
Kota - 324 005, Rajasthan, India.
E-mail: suresh.pandey@gmail.com

Submitted: 28-Jan-2022 **Revised:** 28-Jan-2022
Accepted: 29-Jan-2022 **Published:** 21-Apr-2022

Access this article online	
Website: www.kjophthal.com	Quick Response Code
DOI: 10.4103/kjo.kjo_17_22	

This is an open access journal, and articles are distributed under the terms of the Creative Commons Attribution-NonCommercial-ShareAlike 4.0 License, which allows others to remix, tweak, and build upon the work non-commercially, as long as appropriate credit is given and the new creations are licensed under the identical terms.

For reprints contact: WKHLRPMedknow_reprints@wolterskluwer.com

How to cite this article: Pandey SK. How to minimize litigations and medical malpractice claims during ophthalmic practice? Kerala J Ophthalmol 2022;34:8-11.

unrealistic patient expectations, and this combined with diminishing trust in doctors has fueled the development of our litigious society. Many doctors are accused of lack of diligence, leading to litigations in the consumer courts and civil or criminal courts.

According to a published study,[1] more than 250,000 people in the United States die every year because of medical mistakes, making it the third leading cause of death after heart disease and cancer. Of the hundreds of thousands of medical mistakes that occur each year in hospitals and other medical settings, the most common preventable medical errors that may lead to medical malpractice claims include misdiagnosis, surgical errors, failure to treat, birth injuries, prescription drug errors, etc.

In the Consumer Courts, one of the highest number of medico-legal cases in India are against obstetrics-gynaecologists, followed by other sub-specialities such as orthopedics and pediatrics, etc. Ophthalmology, in this respect, is no different from other medical sectors. Being one of the most complex and high-tech specialties, even the slightest error from the ophthalmologists' end can lead to severe consequences, including lifetime blindness and visual impairment of the patient.[2,3]

A retrospective review in ophthalmology examined 10 years of closed medical professional liability claims (90,743 total) against ophthalmologists and other specialties and found that just 2.6% (2,325) of closed claims and 2.2% of paid claims (564/24,670) were filed against ophthalmologists. Ninety percent of ophthalmic liability claims that received verdicts were favorable to the ophthalmologist.[4] Cataract and corneal surgeries were the most prevalent and costly claims.

Another review looked at 159 litigated cornea and refractive surgery cases from 1964 to 2014. Ninety-three of these (58.5%) went to jury trials, 21.5% of the trials yielded plaintiff's verdicts with a mean adjusted jury award of $588,896. Another 11.9% of those jury trials ended in settlements with a median adjusted indemnity of $782,533.[5] Data from the Ophthalmic Mutual Insurance Company (OMIC) have shown a threefold increase in LASIK claims and suits between 1998 and 2001. Medical and surgical retina specialists, representing 17% of those insured, paid US $4,972,000 at an average of US$248,600 per case. Pediatric ophthalmologists, however, representing only 4.39% of those insured, paid the most, an average of US $874,600. Failure to diagnose retinopathy of prematurity, by either a pediatric ophthalmologist or a medical retina specialist, incurred some of the greatest losses, more than US $1 million in four cases.

If we talk about the situation in India, several cases have been reported against ophthalmologists and decisions have been taken by the National Consumer Disputes Redressal Commission (NCDRC). It is reported that 942 cases of medical negligence were decided by the NCDRC from 2002 to 2018, and out of these cases, 30 were related to ophthalmology. A total of 73.3% of the alleged cases of medical negligence in ophthalmology were proved, and compensation for the cases ranged between Rs. 200,000 and Rs. 10 million.[6]

WHY LITIGATIONS ARE INCREASING IN OPHTHALMOLOGY?

A good quality vision is must to drive, to do activities of daily life including reading news paper and watching TV or using mobile phone. Severe visual impairment/blindness is ranked third as a major fear after cancer and heart disease. Cataract-intraocular implant surgery is advertised as "no patch", "no stitch", "no pain surgery",with immediate gain of vision that can be performed in ten minutes on day care basis. The same is true for laser vision correction. This type of message may have played some role to increase the chances of litigations carried out against ophthalmologists. With increasing patient's expectations and increasing cost of treatment, ophthalmologists are more vulnerable towards getting complaints registered against them.

HOW TO MINIMIZE MEDICAL ERROR(S) BY FOLLOWING THE "CHECKLISTS" AND "PROTOCOLS"?

The WHO surgical safety checklist is a prominent example of a surgical checklist intended to ensure safe surgery and minimize complications.[7] Train your entire ophthalmic team to follow the checklists and protocols. Examine each and every patient very carefully. Ask for the previous medical records and never forget to take a complete history of systemic illness, drug allergy, previous surgery, trauma, etc. Perform a comprehensive ocular examination as well as relevant investigations (such as indirect ophthalmoscopy, optical coherence tomography, specular endothelial cell count, topography, or B scan ultrasound in presence of media opacities). Always document your findings in clear words (without abbreviations) with date, time and signature. Never hesitate to refer a patient for second opinion and complex cases (requiring multiple surgeries) can be referred to higher ophthalmic institutes for the best management.

It is important to counsel and explain each and every patient about the surgery, cost, visual outcome, need for follow-up, and possible complications. The preoperative stage entails taking valid informed consent (video consent in all high-risk cases) of the patient for executing the proposed treatment, taking

and recording the history of the patient, carrying out a proper examination, diagnosis, and investigations, pre-anesthetic check-up, detailed counseling, complete systemic and ophthalmic investigations and then proceeding with treatment.

Always take the help of an anesthesiologist for monitoring vital parameters after taking patients in the operation theater. The surgeon and entire team should be vigilant to minimize the complications encountered during the surgery in the operation theater, accidents, and mishaps experienced while operating, (for example surgery in the wrong eye, implanting wrong IOL), death during operation, and other similar incidents. Always document all operative notes, follow-up advice, detailed instructions about using the medications/eye drops, and communication about the postoperative complications, etc. Ophthalmologists like doctors of other specialties use abbreviations and short forms instead of detailed notes, and this needs to be minimized, specially in the instructions for the patients.

TRAINING OF THE OPERATION THEATER STAFF

Periodical training/checking your staff members and operation theater team is a must to ensure they follow the checklist and protocols to minimize any error (s) when the patient is taken for eye surgery. Double-check the patient records, investigation reports, consent signed by the patient, site of operation, and medical records related to systemic illness, etc. Before taking the patient to the operation theater, check the IOL type and its power, carefully inspect the irrigating solution for any floating particles, always cross-check the date of expiry of drugs and devices. Train your operation theater team to always follow the practice to minimize postoperative endophthalmitis such as the application of adhesive drapes, preoperative cleaning of the eye and periocular area with 5% povidone-iodine solution, and instillation of one drop of povidone-iodine solution after completion of intraocular surgery.

MINIMAL TALKING DURING SURGERY

Exercising utmost care while performing eye surgery or giving intravitreal injections is important as the patient is actively listening to all conversations and may (wrongly) correlate negligence in case of lack of desired results. Most of the eye surgeries are done under topical or local anesthesia with the doctor speaking to their staff or anesthetists and the patient hearing everything.

FOLLOW A STRICT PROTOCOL FOR FREE EYE CAMPS SURGERY:

In India, the prevalent tradition of providing free service has also resulted in a lowering of guard by eye surgeons. These mass cataract-IOL surgery assemblies popularly called "free eye camps" have seen millions of people benefit. But recently there have been cases where an exorbitant penalty has been imposed by the courts, on ophthalmic surgeons for any deficiency in service or complications (such as cluster endophthalmitis), and this has destroyed the careers of many young ophthalmologists. 2, 3 With huge compensations being awarded even where cataract surgeries have been done free of cost or on a discounted basis, the eye camp surgery should be done only in the operation theater of the hospital set up and the permissible number of cataract surgery can be done following all protocols and precautions.

POST-OP COUNSELING & COMMUNICATION:

Despite the best intentions and practices, some complications are bound to occur, and at these times, effective communication with the patients and attendants is the key to avoid these complications from becoming lawsuits. While communicating with these patients, we need to be honest and sympathetic, but not overly defensive. It helps to clearly admit that a problem has occurred rather than being evasive. However, the responsibility doesn't end with good communication, we need to do our best to ensure that the complications are handled well, or are referred to the right place. Support the patient at this time, by explaining the attendants, helping to take the patients elsewhere etc. The right attitude and communication at this crucial time can make a huge difference to the reaction of the patients and avoid litigation despite unfavorable outcome.

SHOULD "DR. GOOGLE" BE BLAMED FOR MALPRACTICE?

The main factor behind increased penalties against doctors/ ophthalmologists concerning medical negligence is greater consumer awareness as well as information (including incomplete/false information) about diseases and treatment available on Internet ("Dr. Google"). The patients are now more aware of their consumer rights and are provided forums and legal means to pursue their claims against the doctors. This awareness has led many ophthalmologists to unnecessary legal charges, and the decision against doctors are published by the media houses prominently encouraging other patients to follow the same route.

NEVER CRITICIZE YOUR COLLEAGUE

Never criticize or disapprove of treatment or surgery done by your professional colleague in front of patients or relatives as it can provoke them to file malpractice lawsuits. The increased cost of service delivery has ultimately led the

consumers to have higher expectations from the medical providers. Combined with the increased awareness and the availability of means to vocalize their grievances, patients can highlight cases of negligence even for the smallest deficiency in the service.

PROFESSIONAL LIABILITY INSURANCE

Ophthalmologists must cover themselves under professional liability insurance. One may take the help of ophthalmic societies for bulk purchase and to reduce the premium. Ophthalmologist should take an indemnity insurance of at least Rs 50 lacs. A group of doctors can always negotiate better terms with the insurer than any individual. If the insurance company is being changed, one should always insist on retroactive cover. It is also better if two insurances of 2 million and 3 million are taken from the same insurer rather than one single policy of 5 million.

CONCLUSION

The number of cases against eye care professionals for malpractice is increasing because of the increased awareness among patients. While very few cases may be legitimate and based on clinical negligence exercised by the doctors, most doctors are wrongfully accused because of the lack of public understanding. The eye care professionals must communicate empathetically, emphasize diligent service delivery and also maintain proper records about the patient history, consent, and treatment. This practice will bring down the incidents of malpractice and will protect the doctors from allegations and fake lawsuits.

It is imperative to take substantial measures to ensure due diligence while performing surgical procedures, follow the provided guidelines, and take all necessary measures before performing any eye surgery in the hospital, avoid doing cataract surgeries in remote areas during eye camps. Following surgical checklists, protocols, proper documentation (maintaining medical records), taking informed consent, communication about the outcome of the procedure or treatment, timely referral of the patient (in case of any complication), and obtaining adequate professional liability insurance are a few important tips to minimize the risk of litigation against ophthalmologists.

Financial support and sponsorship
Nil.

Conflicts of interest
There are no conflicts of interest.

REFERENCES

1. Anderson JG, Abrahamson K. Your health care may kill you: Medical errors. Stud Health Technol Inform 2017;234:13-7.
2. Nagpal N, Nagpal N. When the ophthalmologists turn blind. Indian J Ophthalmol 2019;67:1520-3.
3. Pandey SK, Sharma V. Commentary: Increasing cases of litigations against ophthalmologists: How can we minimize litigations during ophthalmic practice? Indian J Ophthalmol 2019;67:1527-30.
4. Thompson AC, Parikh PD, Lad EM. Review of ophthalmology medical professional liability claims in the United States from 2006 through 2015. Ophthalmology 2018;125:631-41.
5. Englehard SB, Shah CT, Sim AJ, Reddy AK. Malpractice litigation in cornea and refractive surgery: A review of WestLaw database. Cornea 2018;37:537-41.
6. Yadav M, Bansal MK, Garg P. Ophthalmology medical negligence cases decided by NCDRC: Retrospective study. Indian Internet J Forensic Medicine Toxicology 2018;16:64-8.
7. Haynes AB, Weiser TG, Berry WR, Lipsitz SR, Breizat AH, Dellinger EP, *et al.* A surgical safety checklist to reduce morbidity and mortality in a global population. N Engl J Med 2009;360:491-9.

Review Article

Refractive Corneal surgeries: A Review



ABSTRACT

Refractive corneal surgeries are procedures for correction of refractive errors. Modern keratorefractive procedures include laser *in situ* keratomileusis, surface ablation, relatively newer refractive lenticule extraction, and corneal inlays. This article aims to present an overview of currently performed refractive corneal procedures. Basic aspects of patient selection, principles, advantages, limitations, complications, and clinical outcomes are discussed.

Keywords: Laser *in situ* keratomileusis, photorefractive keratectomy, refractive lenticule extraction, femtosecond lenticule extraction, small incision lenticule extraction

INTRODUCTION AND METHODS

Refractive corneal surgeries modify the contour of the cornea to correct the refractive error. This can be done by using excimer laser ablation with or without flap, by femto laser, or by inserting corneal inlays. The field of refractive surgery has seen tremendous advances in the last two decades in terms of refinement in surgical techniques, advances in instrumentation, availability of newer diagnostic tools, and better understanding of corneal biomechanics.[1] This article aims to give an outline of the cornea-based options available in the armamentarium of refractive surgeon. Several studies have shown that modern keratorefractive procedures are efficient, safe, predictable, and stable for correction of refractive errors.[2,3] Complications, though infrequent, can be further minimized by diligent patient selection and strict adherence to safety protocols.

Studies used in this article were obtained from PubMed search from January 2000 to January 2022. The filters applied were "abstract available," "meta-analysis," "randomized control trials," "review," and "systematic review." The keywords used for search were "Refractive corneal surgery," "Keratorefractive surgery," "LASIK," "PRK," "Surface ablation," "Refractive Lenticule Extraction," "Presbyopia treatment," and "Radial Keratotomy."

PATIENT SELECTION

To be a candidate for refractive corneal surgery, patients must be above 18 years of age with stable refraction and normal corneal topography. However, there are specific indications (albeit controversial) for performing refractive surgery in patients below 18 years. Studies have shown that refractive surgery improves visual acuity and stereopsis in children with anisometropic amblyopia and strabismus.[4,5]

Submitted: 29-Jan-2022 **Revised:** 30-Jan-2022
Accepted: 31-Jan-2022 **Published:** 21-Apr-2022

Access this article online	
Website: www.kjophthal.com	Quick Response Code
DOI: 10.4103/kjo.kjo_21_22	

Jyothi Vengalil Menon
Jyothi The Lasik Vision Centre, Bengaluru, Karnataka, India

Address for correspondence: Dr. Jyothi Vengalil Menon, Villa 141, Ferns Habitat, Doddenakundi, Bengaluru - 560 037, Karnataka, India.
E-mail: jyothi.vengalil@gmail.com

This is an open access journal, and articles are distributed under the terms of the Creative Commons Attribution-NonCommercial-ShareAlike 4.0 License, which allows others to remix, tweak, and build upon the work non-commercially, as long as appropriate credit is given and the new creations are licensed under the identical terms.

For reprints contact: WKHLRPMedknow_reprints@wolterskluwer.com

How to cite this article: Menon JV. Refractive corneal surgeries: A review. Kerala J Ophthalmol 2022;34:12-8.

The question remains as to the age at which to perform surgery and eligibility criteria to qualify for pediatric refractive surgery.

CONTRAINDICATIONS

The contraindications for performing refractive surgeries as per the FDA guidelines are discussed below.[1,6]

Ocular contraindications

They include unstable refractive error, corneal ectatic disorders, herpetic keratitis, Avellino corneal dystrophy, cataract, and uncontrolled glaucoma. Patients with ocular allergies and dry eye are also relative contraindications.

Systemic contraindications

Pregnancy and lactation are absolute contraindications for refractive surgery. Patients on isotretinoin for acne must stop medication for at least 6 months prior to keratorefractive procedure. Uncontrolled diabetes mellitus or diabetes mellitus with ocular or systemic complications is a contraindication.[7]

Autoimmune disorders such as rheumatoid arthritis, Sjogren's syndrome, and SLE are relative contraindications. There are several studies indicating that patients with well-controlled autoimmune disorders have undergone refractive corneal surgeries with good visual outcomes.[8,9] Primary Sjogren's disease is an exception to this. More studies are needed to address the role of laser refractive surgeries in patients with auto immune disease.

Preoperative evaluation for corneal refractive procedures

A comprehensive eye examination must be performed. Contact lens wearers must discontinue lenses for a minimum period of 2 weeks for soft lenses and 6 weeks for RGP lenses and longer in the presence of corneal warpage.

Special attention must be paid to deep set eyes and small palpebral fissure which can interfere with placement of speculum and microkeratome resulting in flap-related complications.

Accurate refraction must be performed both after cycloplegia and subjective correction. UCVA and BCVA must be recorded. Patients in presbyopia age group must be informed about near vision requirement after laser procedure and options for the same must be discussed.

Blepharitis and meibomanitis must be treated prior to surgery to avoid diffuse lamellar keratitis and infective keratitis.

Tear film evaluation is done. Several studies have documented that laser refractive surgeries can adversely affect tear film. Laser *in situ* keratomileusis (LASIK) is the worst offender in causing iatrogenic dry eye.[10,11]

Corneal scars must be carefully looked for since they can cause artifacts on corneal imaging and interfere with creation of femto flaps.

Detailed posterior segment evaluation is performed and predisposing retinal lesions must be identified and treated.

Mesopic pupil size must be recorded, and the ablation zone must be bigger than mesopic pupil to avoid glare and haloes.[12,13] Various pupillometers such as Colvard pupillometer are commercially available and give accurate pupil size in standard illumination conditions.[2]

Keratometry readings must be noted. It is important not to steepen the cornea more than 50D or flatten the cornea less than 35D as it can induce ocular aberrations. During microkeratome LASIK, cornea steeper than 46D is at risk for flap buttonholes and cornea flatter than 42D is at risk for free flap.

Tonometry must be recorded as patients with glaucoma pose a special challenge to refractive surgeons. Suction during flap creation can increase IOP. Reduction in corneal thickness can give fallacious IOP readings post refractive surgery. Steroids used postoperatively can increase IOP in steroid responders. All these factors must be considered prior to performing refractive surgery in a patient with glaucoma.[14-16]

Corneal pachymetry is measured using ultrasonic pachymetry or Orbscan or Pentacam. It is mandatory to leave a minimum residual stromal bed of 250 microns to maintain corneal stability. Current practice is to maintain residual stromal bed of 300 microns or 50% of original pachymetry whichever is higher. Percentage of tissue altered (PTA) is a recent metric used in screening patients considering flap thickness, ablation depth, and central corneal thickness. PTA higher or equal to 40% should be considered as a higher risk for post laser ectasia.[17,18]

Corneal topography

Abnormal corneal morphology is by far the commonest cause of post-LASIK ectasia. Placido-based corneal topography is an excellent diagnostic tool to map anterior corneal surface and rule out conditions such as keratoconus and pellucid marginal degeneration. Orbscan is a hybrid system that uses Placido-based system and scanning slit system while Pentacam uses Scheimpflug imaging to scan the cornea. Both Orbscan and Pentacam give anterior and posterior

corneal maps along with point-to-point pachymetry. These devices help to evaluate posterior elevation changes which are often the earliest changes in keratoconus. Belin Ambrosio display in Pentacam is a useful software to detect ectatic corneal conditions early.

Corneal biomechanics

Ocular response analyzer and Corvis ST are two systems that give an idea of corneal biomechanics indicated by corneal hysteresis (CH) and corneal resistance factor (CRF). A weaker cornea is more prone to ectasia following refractive procedure.[19]

Aberrometers (Wavefront analyzers) can measure higher order aberrations of the optical system of the eye which can be incorporated into the laser machine for correction.

OCT

Anterior segment OCT can give pachymetry and flap thickness which is useful while planning enhancements.

KERATOREFRACTIVE PROCEDURES

Laser *in situ* keratomileusis

LASIK procedure consists of two steps: creation of corneal flap and excimer laser ablation.

Corneal flap can be created using a microkeratome or femto laser.[3]

Microkeratomes are manual or automated, geared or gearless, preassembled or assembled on the eye. Newer automated, gearless microkeratomes have increased the ease and safety of flap creation. Flap thickness can be 140, 160, 180, or 200 microns depending on the depth plate of microkeratome. Thinner flaps are safer due to increased residual stromal bed.

Flaps can also be created in a bladeless manner using water jet microkeratome.

In femto LASIK, femto laser creates the flap and refractive ablation is by excimer laser. Femto laser can make customized flaps of varying shape, thickness, and hinge position. Studies have indicated that femto flaps are more planar and predictable as compared to microkeratome flaps. However, the final visual outcomes after microkeratome LASIK and femto laser-assisted LASIK procedure appear to be similar.[20]

Excimer laser which corrects the refractive error has evolved from conventional broad-beam lasers to slit beam and finally modern flying spot lasers with spot size ranging from 0.5 to 0.9 mm. Smaller spot size produces a smoother stromal bed with a better ablation profile and translates into better outcome.

Eye trackers:

Excimer lasers have built in eye trackers that compensates for eye movements in X- and Y-axis during ablation. Modern eye trackers come with dynamic eye tracking, higher frequencies, and cyclotorsion control to actively track the pupil and ensure optimum centration during ablation with improved visual outcomes.

Types of laser in situ keratomileusis procedures

Depending upon patient's preexisting refractive parameters, LASIK procedure can be conventional, wavefront optimized, wavefront guided, or topography guided.

Conventional laser in situ keratomileusis surgery

Excimer laser does refractive ablation to correct refractive errors. During this process, prolate shape of cornea becomes oblate. This can induce higher order aberrations impacting the quality of vision in conventional LASIK procedure.

Wavefront-optimized laser in situ keratomileusis

In order to reduce the induced higher order aberrations, the laser spots are delivered in a predetermined and optimized manner on the cornea to reduce induced aberrations. This is known as wavefront-optimized LASIK and is a refinement over conventional LASIK.

Wavefront-guided laser in situ keratomileusis

The preexisting HOA of eye can be measured using aberrometers. Wavefront-guided LASIK (WFG) is customized to correct the patient's preexisting higher order aberrations. Studies have indicated that WFG LASIK appears to be better than conventional LASIK for treating eyes with higher order aberrations more than 0.30, in re-treatments, and in patients with large scotopic pupil size.[21,22]

Topography-guided laser in situ keratomileusis

In patients with astigmatism, irregular cornea, decentered ablations, and preexisting corneal pathology, most of the aberrations arise from the cornea. In such eyes, it is difficult to capture reliable wavefront maps. The data obtained from corneal topography are used to perform[4] topography-guided LASIK to smoothen the irregular corneal surface and improve the quality of vision.[23,24]

LASIK can be used to correct myopia up to 12D hyperopia up to 6D and astigmatism up to 6D, provided patient's keratometry and pachymetry values permit.

Sub-Bowman's keratomileusis

This procedure is thin-flap LASIK using 90-micron flap. It combines safety of photorefractive keratectomy (PRK) with minimum pain and speedy recovery of LASIK. Thinner flaps increase residual stromal bed, but they are difficult to handle and are prone for flap striae.[25]

Post laser in situ keratomileusis enhancements

Post LASIK enhancements can be treated by flap recut or lifting the flap and doing relaser, provided adequate RSB is present. Flap lift is preferred to flap cut. PRK is also an option. Some studies have shown that relifting the flap may result in more accurate refractive outcome as compared to PRK, but epithelial ingrowth is a risk.[26-29]

Surface ablation

There has been a resurgence of surface ablation due to better pain control and use of mitomycin C. Surface ablation has less impact on corneal biomechanics as compared to LASIK with and no flap-related complications.[30] The epithelium is removed, and laser is applied on the bed consisting of Bowman's layer and anterior corneal stroma. 0.02% mitomycin C is applied on the corneal stroma. Epithelium may or may not be replaced. A bandage contact lens is placed to promote epithelial healing and to reduce pain. The following methods are used to separate epithelium

Photorefractive keratectomy

Mechanical scraping of epithelium is done in conventional PRK.

Laser-assisted subepithelial keratomileusis (LASEK)

Epithelium is removed using 20% alcohol and replaced after refractive ablation.

Epi-laser in situ keratomileusis

Microkeratome is used with a blunt blade to remove the epithelium that can be replaced.

With the use of bandage contact lens, studies have not conclusively demonstrated significant advantage with epithelium on or epithelium off methods.[31]

Trans-photorefractive keratectomy

Excimer laser is used to remove the epithelium followed by refractive ablation. This can be done in two ways. In "two-step trans-PRK," epithelium is removed first by laser ablation followed by refractive ablation. In "one-step trans-PRK," the epithelium removal and refractive ablation occurs sequentially as a single step significantly reducing the time taken.[32]

Surface ablation can be conventional, wavefront optimized, wavefront guided, or topography guided. Studies have shown that surface ablation with WFG treatment has better visual outcomes as compared to LASIK with WFG treatment.[33]

Advantages and limitations

Surface ablation is preferred in patients with deep set eyes, small palpebral fissures, flat or steep cornea, thin cornea, and in patients actively involved in contact sports. However, in patients actively involved in outdoor activities, there is an increased risk of haze due to ultraviolet light exposure. Problems faced in surface ablations are delayed visual recovery, postoperative pain, and early or late haze formation, especially with higher ablation depth. Pain can be managed by using bandage contact lens and oral NSAID. Application of 0.02% MMC after laser ablation on the stromal bed reduces haze allowing treatment of higher powers. Studies have shown that mitomycin at a concentration on 0.02% is safe for use on stromal bed after excimer laser ablation. While there is consensus on dose of mitomycin at 0.02%, there is no consensus on time of application which can vary from 12 s to 2 min. Doses less than 0.02% are less effective in preventing haze.[34,35]

Refractive lenticule extraction

Refractive lenticule extraction is an all-femtosecond laser-based refractive technique. This procedure uses femto laser for refractive lenticule extraction. Two methods used are femtosecond lenticule extraction (FLEx) and small incision lenticule extraction (SMILE). FLEx requires the creation of a flap to remove the lenticule. SMILE is a flapless and minimally invasive procedure that extracts the lenticule from a small cornea incision. Currently, SMILE is used to correct myopia unto 10D and myopic astigmatism up to 6D. Studies have shown that SMILE has similar efficiency, predictability, and safety as compared to femtosecond LASIK. SMILE is minimally invasive with minimum pain and postoperative discomfort.[36-39] Studies have indicated that SMILE may have a lesser impact on corneal biomechanics, and tear film as compared to LASIK.[40] Infrequent complications of SMILE include suction loss, lenticule tears, incision tears, epithelial ingrowth, diffuse lamellar keratitis, and residual refractive error. Surface ablation or CIRCLE procedure can be used for retreatment. In CIRCLE procedure, the lenticule is converted into a flap and laser is performed to correct the residual power.[41-43]

Presbyopia correction

Exciting developments are taking place in presbyopia correction, and various methods are currently available.[44]

The dominant eye is corrected for distance and non-dominant eye is corrected for near in presbyopia patients, when

correcting for their refractive errors. The near vision correction by +1.5D is well tolerated.

PresbyLASIK is another option. PresbyLASIK is performed mono ocularly on the nondominant eye. In this procedure, in-built algorithms are used to make cornea multifocal to correct near vision. Mono-ocular biaspheric PresbyLASIK is reported to give good results in presbyopes.[45]

Corneal inlay is a new treatment modality for presbyopia. Corneal inlays are implanted in the anterior corneal stroma of the nondominant eye beneath the flap or beneath laser-created pockets. They improve the near vision by increasing the depth of focus. Synthetic and allogenic inlays have been described. Flexivue microlens, Kamra, and Raindrop inlays are some of the corneal inlays available.[46,47]

Conductive keratoplasty

This is a laser-independent procedure used for correction of presbyopia and hyperopia. Radio frequency of 350 Hz is delivered into the peripheral corneal stroma to cause steepening of central cornea. Studies have shown conductive keratoplasty to be safe and effective for low-to-moderate hyperopia, hyperopic astigmatism, and presbyopia.[48,49]

Radial keratotomy

Radial keratotomy (RK) was used to correct myopia by using corneal incisions to alter the shape of the cornea. Centripetal or centrifugal radial incisions are made in the cornea avoiding the central optical zone. The drawbacks of RK are variability in results and fluctuating vision. With the advent of lasers, RK has become outdated. Both LASIK and PRK with mitomycin C are useful in post RK residual errors.

Astigmatic keratotomy and limbal relaxing incisions

Astigmatic keratotomy (AK) is another technique used to correct corneal astigmatism usually prior to cataract surgery by placing corneal incision on the steep axis. Limbal relaxing incisions are made in the peripheral cornea just inside the limbus and are less likely to induce irregular corneal astigmatism. Femtosecond can be utilized for AK.

Intacs

Intacs are intracorneal ring segments. They are useful in correcting low myopia in patients with thin cornea or forme fruste keratoconus who are otherwise unsuitable for laser refractive procedure. Intacs are inserted creating corneal pockets using a mechanical technique or by creating channels using the femtosecond laser.

Complications of keratorefractive procedures

Cornea-based refractive surgeries have been refined over past two decades to yield safe, predictable, and excellent visual outcomes. Complications are infrequent and can happen during operative, immediate postoperative, and late postoperative period and can range from mild to vision threatening.

In microkeratome LASIK, flap complications such as suction loss with flap tear, free caps, buttonholes, flap striae, and rarely flap melt can occur. Decentered ablation and central islands can degrade the quality of vision.

Postoperative complications include residual refractive error, diffuse lamellar keratitis, and infectious keratitis epithelial ingrowth.

Dry eye can be troublesome and may need punctal plugs.

Femto procedure complications include vertical break through, opaque bubble layer, and transient light sensitivity.

In surface ablations, postoperative pain can make patients anxious. Delayed epithelial healing can occur. Corneal haze formation can degrade visual outcome.

Corneal ectasia

One of the dreaded complications of corneal refractive surgery is corneal ectasia. The cornea progressively becomes ectatic with reduction in best-corrected visual acuity. To a large extent, ectasia can be prevented by careful patient selection.

Risk factors for corneal ectasia

Abnormal corneal topography, high myopia, ablation depth above 75 microns, thin cornea, less residual stromal bed due to increased ablation, or thicker flap can lead to keratectasia.[50-52]

Studies have shown that postoperative corneal ectasia occurs at a lower rate in eyes undergoing PRK than LASIK and least of all in SMILE.[53] However, there are some recent reports of post SMILE ectasia.

CLINICAL OUTCOMES

There are several studies and reviews on the safety, predictability, stability, and efficacy of various refractive surgeries. Most of these studies indicate excellent visual outcome with a few complications following laser vision correction. LASIK, PRK, and SMILE give safe, predictable, and comparable visual outcomes. Based on the current data, it is difficult to comment on the superiority of one technique over the other in terms of long-term visual outcomes.[54-60]

CONCLUSION

Corneal refractive surgeries have come a long way from inception and provide excellent options to spectacle free vision. Various procedures are available to correct refractive errors. A thorough knowledge is essential to achieve best results and minimize complications. The results are encouraging, and the best is yet to come.

Financial support and sponsorship

Nil.

Conflicts of interest

There are no conflicts of interest.

REFERENCES

1. Ang M, Gatinel D, Reinstein DZ, Mertens E, Alió Del Barrio JL, Alió JL. Refractive surgery beyond 2020. Eye (Lond) 2021;35:362-82.
2. Wen D, McAlinden C, Flitcroft I, Tu R, Wang Q, Alió J, *et al*. Postoperative efficacy, predictability, safety, and visual quality of laser corneal refractive surgery: A network meta-analysis. Am J Ophthalmol 2017;178:65-78.
3. Sakimoto T, Rosenblatt MI, Azar DT. Laser eye surgery for refractive errors. Lancet 2006;367:1432-47.
4. Fecarotta CM, Kim M, Wasserman BN. Refractive surgery in children. Curr Opin Ophthalmol 2010;21:350-5.
5. Donahue SP. Long-term outcomes of photorefractive keratectomy for anisometropic amblyopia in children. Ophthalmology 2006;113:167-8.
6. Bower KS, Woreta F. Update on contraindications for laser-assisted *in situ* keratomileusis and photorefractive keratectomy. Curr Opin Ophthalmol 2014;25:251-7.
7. Simpson RG, Moshirfar M, Edmonds JN, Christiansen SM. Laser *in-situ* keratomileusis in patients with diabetes mellitus: A review of the literature. Clin Ophthalmol 2012;6:1665-74.
8. Chen TY, Chu DS. Refractive surgery for the patient with autoimmune diseases. Curr Opin Ophthalmol 2020;31:247-52.
9. Simpson RG, Moshirfar M, Edmonds JN, Christiansen SM, Behunin N. Laser *in situ* keratomileusis in patients with collagen vascular disease: A review of the literature. Clin Ophthalmol 2012;6:1827-37.
10. Denoyer A, Landman E, Trinh L, Faure JF, Auclin F, Baudouin C. Dry eye disease after refractive surgery: Comparative outcomes of small incision lenticule extraction versus LASIK. Ophthalmology 2015;122:669-76.
11. Toda I. Dry eye after LASIK. Invest Ophthalmol Vis Sci 2018;59:S109-15.
12. Salz JJ, Trattler W. Pupil size and corneal laser surgery. Curr Opin Ophthalmol 2006;17:373-9.
13. Fan-Paul NI, Li J, Miller JS, Florakis GJ. Night vision disturbances after corneal refractive surgery. Surv Ophthalmol 2002;47:533-46.
14. Shrivastava A, Madu A, Schultz J. Refractive surgery and the glaucoma patient. Curr Opin Ophthalmol 2011;22:215-21.
15. Bashford KP, Shafranov G, Tauber S, Shields MB. Considerations of glaucoma in patients undergoing corneal refractive surgery. Surv Ophthalmol 2005;50:245-51.
16. Ahmad M, Chocron I, Shrivastava A. Considerations for refractive surgery in the glaucoma patient. Curr Opin Ophthalmol 2017;28:310-5.
17. Santhiago MR. Percent tissue altered and corneal ectasia. Curr Opin Ophthalmol 2016;27:311-5.
18. Santhiago MR, Smadja D, Gomes BF, Mello GR, Monteiro ML, Wilson SE, *et al*. Association between the percent tissue altered and post-laser *in situ* keratomileusis ectasia in eyes with normal preoperative topography. Am J Ophthalmol 2014;158:87-95.e1.
19. Moshirfar M, Motlagh MN, Murri MS, Momeni-Moghaddam H, Ronquillo YC, Hoopes PC. Advances in biomechanical parameters for screening of refractive surgery candidates: A review of the literature, part III. Med Hypothesis Discov Innov Ophthalmol 2019;8:219-40.
20. Chen S, Feng Y, Stojanovic A, Jankov MR 2nd, Wang Q. IntraLase femtosecond laser vs. mechanical microkeratomes in LASIK for myopia: A systematic review and meta-analysis. J Refract Surg 2012;28:15-24.
21. Smadja D, Reggiani-Mello G, Santhiago MR, Krueger RR. Wavefront ablation profiles in refractive surgery: Description, results, and limitations. J Refract Surg 2012;28:224-32.
22. Alió JL, Piñero D, Muftuoglu O. Corneal wavefront-guided retreatments for significant night vision symptoms after myopic laser refractive surgery. Am J Ophthalmol 2008;145:65-74.
23. Ramamurthy S, Soundarya B, Sachdev GS. Topography-guided treatment in regular and irregular corneas. Indian J Ophthalmol 2020;68:2699-704.
24. Holland S, Lin DT, Tan JC. Topography-guided laser refractive surgery. Curr Opin Ophthalmol 2013;24:302-9.
25. Slade SG. Thin-flap laser-assisted *in situ* keratomileusis. Curr Opin Ophthalmol 2008;19:325-9.
26. Parikh NB. Management of residual refractive error after laser *in situ* keratomileusis and photorefractive keratectomy. Curr Opin Ophthalmol 2014;25:275-80.
27. Moshirfar M, Jehangir N, Fenzl CR, McCaughey M. LASIK enhancement: Clinical and surgical management. J Refract Surg 2017;33:116-27.
28. Chan C, Lawless M, Sutton G, Hodge C. Re-treatment in LASIK: To flap lift or perform surface ablation. J Refract Surg 2020;36:6-11.
29. Solaiman KA, Fouda SM, Bor'i A, Al-Nashar HY. Photorefractive keratectomy for residual myopia after myopic laser *in situ* keratomileusis. J Ophthalmol 2017:8725172. doi:10.1155/2017.
30. Taneri S, Zieske JD, Azar DT. Evolution, techniques, clinical outcomes, and pathophysiology of LASEK: Review of the literature. Surv Ophthalmol 2004;49:576-602.
31. Kalyvianaki MI, Kymionis GD, Kounis GA, Panagopoulou SI, Grentzelos MA, Pallikaris IG. Comparison of Epi-LASIK and off-flap Epi-LASIK for the treatment of low and moderate myopia. Ophthalmology 2008;115:2174-80.
32. Gadde AK, Srirampur A, Katta KR, Mansoori T, Armah SM. Comparison of single-step transepithelial photorefractive keratectomy and conventional photorefractive keratectomy in low to high myopic eyes. Indian J Ophthalmol 2020;68:755-61.
33. Moshirfar M, Schliesser JA, Chang JC, Oberg TJ, Mifflin MD, Townley R, *et al*. Visual outcomes after wavefront-guided photorefractive keratectomy and wavefront-guided laser *in situ* keratomileusis: Prospective comparison. J Cataract Refract Surg 2010;36:1336-43.
34. Majmudar PA, Schallhorn SC, Cason JB, Donaldson KE, Kymionis GD, Shtein RM, *et al*. Mitomycin-C in corneal surface excimer laser ablation techniques: A report by the American Academy of Ophthalmology. Ophthalmology 2015;122:1085-95.
35. Thornton I, Xu M, Krueger RR. Comparison of standard (0.02%) and low dose (0.002%) mitomycin C in the prevention of corneal haze following surface ablation for myopia. J Refract Surg 2008;24:S68-76.
36. Kim P, Sutton GL, Rootman DS. Applications of the femtosecond laser in corneal refractive surgery. Curr Opin Ophthalmol 2011;22:238-44.
37. Marino GK, Santhiago MR, Wilson SE. Femtosecond lasers and corneal surgical procedures. Asia Pac J Ophthalmol (Phila) 2017;6:456-64.
38. Ganesh S, Brar S, Arra RR. Refractive lenticule extraction small incision lenticule extraction: A new refractive surgery paradigm. Indian J Ophthalmol 2018;66:10-9.
39. Sachdev GS, Ramamurthy S. Decade – Long journey with small incision lenticule extraction: The learnings. Indian J Ophthalmol

2020;68:2705-10.
40. Kobashi H, Kamiya K, Shimizu K. Dry eye after small incision lenticule extraction and femtosecond laser-assisted LASIK: Meta-analysis. Cornea 2017;36:85-91.
41. Asif MI, Bafna RK, Mehta JS, Reddy J, Titiyal JS, Maharana PK, *et al*. Complications of small incision lenticule extraction. Indian J Ophthalmol 2020;68:2711-22.
42. Siedlecki J, Luft N, Mayer WJ, Siedlecki M, Kook D, Meyer B, *et al*. CIRCLE enhancement after myopic SMILE. J Refract Surg 2018;34:304-9.
43. Moshirfar M, Shah TJ, Masud M, Linn SH, Ronquillo Y, Hoopes PC Sr. Surgical options for retreatment after small-incision lenticule extraction: Advantages and disadvantages. J Cataract Refract Surg 2018;44:1384-9.
44. Stival LR, Figueiredo MN, Santhiago MR. Presbyopic excimer laser ablation: A review. J Refract Surg 2018;34:698-710.
45. Chan TC, Kwok PS, Jhanji V, Woo VC, Ng AL. Presbyopic correction using monocular bi-aspheric ablation profile (PresbyMAX) in hyperopic eyes: 1-year outcomes. J Refract Surg 2017;33:37-43.
46. Moshirfar M, Desautels JD, Wallace RT, Koen N, Hoopes PC. Comparison of FDA safety and efficacy data for KAMRA and Raindrop corneal inlays. Int J Ophthalmol 2017;10:1446-51.
47. Moarefi MA, Bafna S, Wiley W. A review of presbyopia treatment with corneal inlays. Ophthalmol Ther 2017;6:55-65.
48. Huang B. Update on nonexcimer laser refractive surgery technique: Conductive keratoplasty. Curr Opin Ophthalmol 2003;14:203-6.
49. Du TT, Fan VC, Asbell PA. Conductive keratoplasty. Curr Opin Ophthalmol 2007;18:334-7.
50. Ambrósio R Jr. Post-LASIK ectasia: Twenty years of a conundrum. Semin Ophthalmol 2019;34:66-8.
51. Soundarya B, Sachdev GS, Ramamurthy S, Dandapani R. Ectasia after keratorefractive surgery: Analysis of risk factors and treatment outcomes in the Indian population. Indian J Ophthalmol 2020;68:1028-31.
52. Moshirfar M, Tukan AN, Bundogji N, Liu HY, McCabe SE, Ronquillo YC, *et al*. Ectasia after corneal refractive surgery: A systematic review. Ophthalmol Ther 2021;10:753-76.
53. Shah R. History and results; indications and contraindications of SMILE compared with LASIK. Asia Pac J Ophthalmol (Phila) 2019;8:371-6.
54. Lee JK, Chuck RS, Park CY. Femtosecond laser refractive surgery: Small-incision lenticule extraction vs. femtosecond laser-assisted LASIK. Curr Opin Ophthalmol 2015;26:260-4.
55. Han T, Shang J, Zhou X, Xu Y, Ang M, Zhou X. Refractive outcomes comparing small-incision lenticule extraction and femtosecond laser-assisted laser *in situ* keratomileusis for high myopia. J Cataract Refract Surg 2020;46:419-27.
56. Hamam KM, Gbreel MI, Elsheikh R, Benmelouka AY, Ouerdane Y, Hassan AK, *et al*. Outcome comparison between wavefront-guided and wavefront-optimized photorefractive keratectomy: A systematic review and meta-analysis. Indian J Ophthalmol 2020;68:2691-8.
57. Vestergaard AH. Past and present of corneal refractive surgery: A retrospective study of long-term results after photorefractive keratectomy and a prospective study of refractive lenticule extraction. Acta Ophthalmol 2014;92 Thesis 2:1-21.
58. Zhang J, Feng Q, Ding W, Peng Y, Long K. Comparison of clinical results between trans-PRK and femtosecond LASIK for correction of high myopia. BMC Ophthalmol 2020;20:243.
59. Han T, Xu Y, Han X, Zeng L, Shang J, Chen X, *et al*. Three-year outcomes of small incision lenticule extraction (SMILE) and femtosecond laser-assisted laser *in situ* keratomileusis (FS-LASIK) for myopia and myopic astigmatism. Br J Ophthalmol 2019;103:565-8.
60. Gulmez M, Tekce A, Kamıs U. Comparison of refractive outcomes and high-order aberrations after small incision lenticule extraction and wavefront-guided femtosecond-assisted laser *in situ* keratomileusis for correcting high myopia and myopic astigmatism. Int Ophthalmol 2020;40:3481-9.

Dense fibrin membrane mimicking anterior dislocated lens

A 40-year-old male diagnosed case of right eye uveitic glaucoma presented with flare-up. Slit lamp examination gave a first impression of anterior dislocated cataractous lens [Figure 1a]. However, after dilatation, on careful examination, lens was found to be in its normal anatomical position with dense fibrin membrane anterior to it, mimicking the crystalline lens [Figure 1b]. B-scan of the concerned eye showed lens in normal position but vitreous membrane in the posterior segment. The patient was started on oral prednisolone and topical dexamethasone in tapering dose. Along with these antiglaucoma medications, topical antibiotic and topical cycloplegics were given.

CLINICAL SIGN/FINDING: DENSE FIBRIN MEMBRANE/ FIBRINOID SYNDROME

- Seen in
  1. Dense pupillary fibrin membranes are found following intraocular surgeries[1,2]
  2. Fibrinoid syndrome is found in proliferative diabetic retinopathy (PDR) patients following vitreoretinal surgeries.[3]

- Described by
  "Fibrinoid syndrome" was first described by Sebestyen in 1982 for patients with PDR and those who developed dense retropupillary/vitreous fibrin bands after undergoing multiple surgical procedures for diabetic-related complications.[3]

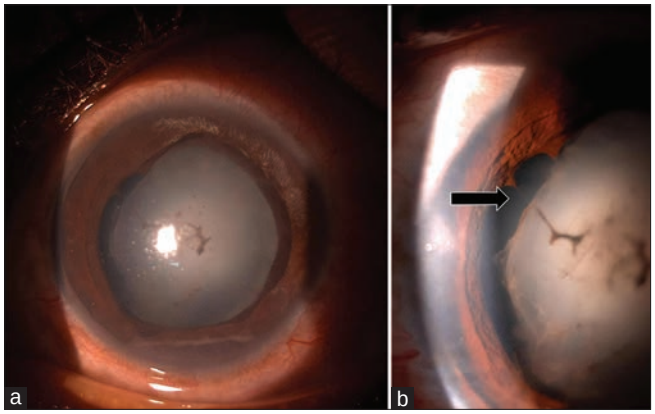

Figure 1: (a) Preliminary slit lamp evaluation giving impression of anterior subluxated cataractous lens, (b) further examination confirmed the presence of natural crystalline lens with dense fibrin membrane anteriorly mimicking cataractous lens

CARDINAL DIAGNOSTIC FEATURES

It occurs most commonly in patients undergoing pars plana vitrectomy for diabetic tractional detachments or patients with chronic retinal detachment. But has also been reported in patients undergoing cataract surgery with certain predisposing factors such as uveitis, glaucoma, or PES.[2,4]

It presents as dense fibrin reaction commonly occurring either anterior or posterior to iris with most of the time having a history ocular surgery done 1–2 weeks before development of fibrinoid reaction.

PATHOPHYSIOLOGY

Although the exact pathophysiology of fibrinoid syndrome is unclear, the common proposed mechanisms include

Shivraj Tagare, Harsh Vardhan Singh[1], Iva Rani Kalita[2]

DNB Resident, Departments of [1]Retina-Vitreous and [2]Paediatrics and Strabismus, Aravind Eye Hospital, Puducherry, India

Address for correspondence: Dr. Iva Rani Kalita, Department of Paediatric and Strabismus, Aravind Eye Hospital, Puducherry - 605 007, India.
E-mail: kalitaiva3@gmail.com

Submitted: 11-Apr-2021 **Revised:** 15-Apr-2021
Accepted: 25-Apr-2021 **Published:** 21-Apr-2022

Access this article online	
Website: www.kjophthal.com	Quick Response Code
DOI: 10.4103/kjo.kjo_84_21	

This is an open access journal, and articles are distributed under the terms of the Creative Commons Attribution-NonCommercial-ShareAlike 4.0 License, which allows others to remix, tweak, and build upon the work non-commercially, as long as appropriate credit is given and the new creations are licensed under the identical terms.

For reprints contact: WKHLRPMedknow_reprints@wolterskluwer.com

How to cite this article: Tagare S, Singh HV, Kalita IR. Dense fibrin membrane mimicking anterior dislocated lens. Kerala J Ophthalmol 2022;34:19-20.

endothelial dysfunction and increased vascular permeability because of underlying inflammation.[3] Idiosyncratic reaction, or sterile, and noninfectious reactions to intravitreal medications and pharmacologic alteration of blood–brain barrier have also been proposed.[5-7] In our patient, the flare-up of anterior uveitis may have contributed to the development of fibrinoid/fibrinous-like reaction.

What else to examine (associated clinical signs – ocular or systemic): It is important to differentiate this syndrome from toxic anterior segment syndrome and endophthalmitis and to initiate appropriate treatment. The fibrin bands tend to be exquisitely sensitive to topical steroids and resolves within few weeks of treatment initiation without any sequelae.

- The signs of fibrin or fibrinoid reaction can range from the presence of a few fibrin strands to a dense pupillary membrane in the anterior chamber[2]
- It is most commonly associated with diabetes, pseudoexfoliation, glaucoma, and extracapsular cataract extraction.[8]

Declaration of patient consent

The authors certify that they have obtained all appropriate patient consent forms. In the form, the patient has given his consent for his images and other clinical information to be reported in the journal. The patient understands that his name and initials will not be published and due efforts will be made to conceal their identity, but anonymity cannot be guaranteed.

Financial support and sponsorship

Nil

Conflicts of interest

There are no conflicts of interest.

REFERENCES

1. Heiligenhaus A, Schilling H, Schilling M, Mellin KB. Treatment with tissue plasminogen activator (tPA) in risk patients with fibrin reactions after cataract operations. Ophthalmologe 1996;93:49-53.
2. Wålinder PE, Olivius EO, Nordell SI, Thorburn WE. Fibrinoid reaction after extracapsular cataract extraction and relationship to exfoliation syndrome. J Cataract Refract Surg 1989;15:526-30.
3. Sebestyen JG. Fibrinoid syndrome: A severe complication of vitrectomy surgery in diabetics. Ann Ophthalmol 1982;14:853-6.
4. Petraevsky AV, Gndoyan IA, Kushtareva LB. Prediction of operational complications based on assessment neurocirculatory and trophic changes in the anterior segment of the eye with pseudoexfoliation syndrome. Ophthalmosurgery 2009;1:9-13.
5. Chiang A, Reddy S, Tsui I, Hubschman JP. Vitreous web after pars plana vitrectomy and bevacizumab with fluid-air exchange. Semin Ophthalmol 2011;26:25-7.
6. Jabbur NS. Excessive fibrin after cataract surgery associated with aminocaproic acid use. J Cataract Refract Surg 2003;29:1636-7.
7. Miyake K, Miyake Y, Maekubo K. Increased aqueous flare as a result of a therapeutic dose of mannitol in humans. Graefes Arch Clin Exp Ophthalmol 1992;230:115-8.
8. Baltatzis S, Georgopoulos G, Theodossiadis P. Fibrin reaction after extracapsular cataract extraction: A statistical evaluation. Eur J Ophthalmol 1993;3:95-7.

Original Article

Atropine in myopia – Does it reduce progression? Results of Phase 1 clinical trial in children attending a tertiary eye care center in South India

ABSTRACT

Aim: The aim of this study was to analyze the effectiveness of low-dose atropine (0.01%) in reducing the progression of myopia in Indian children. **Materials and Methods:** This was a clinical trial of Indian children with axial myopia from January 2018 to May 2019, who were prescribed low-dose atropine (0.01%) to reduce progression. Parameters studied before and after starting low-dose atropine were as follows: visual acuity for distance and near, cycloplegic refraction, ocular alignment for distance and near, near point of accommodation (NPA), near point of convergence, axial length (AXL), pupil diameter (PDM), lens thickness (LT), anterior chamber depth (ACD), adverse reaction, compliance, and dropouts. Patients were evaluated at the initiation of treatment, at 1 month, and thereafter 6 monthly with a minimum follow-up of 6 months. Any increase in spherical equivalent (SE) of myopia was taken as progression and rapid progression of myopia was considered if there was a 0.5 DS increase in SE of myopia within 6 months. **Results:** Seventy-one eyes of 36 children who opted for low-dose atropine (18 males and 18 females) and 37 eyes of 19 age-matched children (10 females and 9 males) were included in the final study and control groups, respectively. The mean age was 8.31 years (standard deviation [SD] =1.191) in the cases compared to 9.68 years (SD = 3.606) in the controls. Progression of myopia was noted in 40 eyes (56.338%) in the study group as compared to 35 eyes (94.59%) in the control group ($P = 0.00$). Rapid progression was noted in 23 eyes (32.39%) in the study group as compared to 23 eyes (62.16%) in the control group ($P = 0.003$). The mean SE of myopia increased by 0.28 D (as compared to 0.63 D increase among the controls) ($P = 0.01$), and the mean AXL increased by 0.14 mm (as compared to 0.25 mm among the controls) in the study group at the end of 6 months ($P = 0.01$). There was also a statistically significant increase in mean PDM by 0.83 mm ($P = 0.01$) and receding of mean NPA by 1.14 cm in cases ($P = 0.03$). However, these changes were clinically insignificant. No significant changes were noted in ACD, LT, NPC, and ocular alignment. No adverse reactions were reported. **Conclusion:** Low-dose atropine (0.01%) therapy was able to reduce the progression of myopia in the study group as compared to the controls with a good tolerance and no change in the vision-related quality of life. Long-term follow-up is, however, needed for extrapolation into the general population.

Keywords: Children, low-dose atropine, myopia

MYOPIA: PREVALENCE AND GLOBAL IMPACT

Myopia is an abnormal condition breaking the emmetropization process progressing rapidly from onset at an early age and continuing until early adulthood. The most common definition of myopia is spherical equivalence −0.5 D or greater. Myopia is very common and a major cause of visual impairment in both developed and developing countries.[1-3] The prevalence of myopia is increasing and varies by country, age, and ethnic group. In East Asia, the prevalence of myopia is very high, particularly in Japan,[4] South Korea,[5] Singapore,[6]

R. Neena, Ayshathu Nasheetha[1], Nimmy Prakash[2], Anantharaman Giridhar[3]

Pediatric Ophthalmology, Strabismus and Neuro-ophthalmology Services, [1]Department of Optometry, [2]Department of Biostatistics, [3]Vitreo-Retina Services, Giridhar Eye Institute, Kochi, Kerala, India

Address for correspondence: Dr. R. Neena, Giridhar Eye Institute, Kadavanthara, Kochi - 682 020, Kerala, India.
E-mail: neenamed@gmail.com

Submitted: 25-Jul-2021 **Revised:** 15-Aug-2021 **Accepted:** 24-Aug-2021 **Published:** 21-Apr-2022

Access this article online	
Website: www.kjophthal.com	Quick Response Code
DOI: 10.4103/kjo.kjo_167_21	

This is an open access journal, and articles are distributed under the terms of the Creative Commons Attribution-NonCommercial-ShareAlike 4.0 License, which allows others to remix, tweak, and build upon the work non-commercially, as long as appropriate credit is given and the new creations are licensed under the identical terms.

For reprints contact: WKHLRPMedknow_reprints@wolterskluwer.com

How to cite this article: Neena R, Nasheetha A, Prakash N, Giridhar A. Atropine in myopia – Does it reduce progression? Results of Phase 1 clinical trial in children attending a tertiary eye care center in South India. Kerala J Ophthalmol 2022;34:21-6.

Taiwan,[7] Hong Kong,[8] and China.[9] Lower rates are reported from South Asia and India.[10-12] In India, urban children had a myopia prevalence of 4.7%, 7.0%, and 10.8% in 5-, 10-, and 15-year olds. In rural children, it was 2.8%, 4.1%, and 6.7% in 7-, 10-, and 15-year olds, respectively.[10,11] A recent study by Saxena *et al*. evaluated the prevalence of myopia in Delhi. Among total of 9884 schoolchildren screened, the prevalence of myopia was 13.1% with one-fourth wearing appropriate spectacles.[13] Myopia has become a global health problem associated with vision impairment and blinding complications and also a significant economic burden.[14] In Singapore, the mean annual cost of myopia for a child is $148.[14] In the US, the annual direct cost of correcting distance vision impairment due to refractive errors is between US$3.9 and US$7.2 billion.[15]

Progression and high myopia

Myopia progression in East Asian children is high (−1 diopter [D] per year)[7,8] and is rapid than in Western children.[16] It is estimated that in 2050, half the global population (5 billion people) would be myopic and one-fifth of those (1 billion) would be high myopic.

Complications

High myopia is associated with sight-threatening conditions such as presenile cataracts, glaucoma, retinal detachment, myopic choroidal neovascularization, foveoschisis, staphyloma, macular atrophy, and blindness. Early onset of myopia in childhood is associated with high myopia in adult life. The ultimate goal of myopia control therapy would be to slow myopic progression during years of active eye growth so that the eventual level of myopia is lower than if the eye was allowed to grow naturally.

Atropine in myopia

Atropine eye drops have been used for myopia control for some years. The Atropine for the Treatment of Myopia 1 (ATOM 1) showed that atropine 1% eye drops slowed myopia progression significantly.[17] In Phase 1 of the 5-year clinical trial on ATOM 2, atropine 0.01% was almost as effective in reducing myopia progression as higher concentrations.[18] With fewer side effects and rebound after drop cessation, the low concentration of 0.01% atropine had a better treatment-to-side effect ratio.[18] Atropine nonselectively blocks muscarinic receptors in human ciliary muscle, retina, and sclera, inhibiting thinning or stretching of sclera, and thereby eye growth. This eye growth possibly involves a series of biochemical steps and atropine inhibits one or more steps along this pathway, creating changes in feedback mechanisms.[18] Almost all studies on efficacy of low-dose atropine have been carried out in East Asian children, and there are very little data on its effect in other ethnic populations. Therefore, we decided to evaluate the efficacy and safety of low-concentration atropine eye drops in Indian children with progressive myopia.

Aim

The aim of this study was to analyze the efficacy of low-dose atropine (0.01%) in reducing the progression of myopia in Indian children.

MATERIALS AND METHODS

This was a prospective case − control study of all children between 6 and 16 years, of Indian ethnicity with documented increase of myopic refraction, who were prescribed low-dose atropine (0.01%) to reduce progression. The study was conducted at a tertiary eye care center in South India from the period of January 2018 to May 2019. The parents or guardians were given the option of choosing low dose atropine therapy after explaining about the drug usage,tests required and possible adverse reactions. Informed consent was obtained from parents or guardians, and verbal consent was obtained from all participants. The study was conducted in accordance with the Declaration of Helsinki and was approved by the appropriate institutional review board and ethics committee.

Inclusion criteria

(1) Myopic refraction ≥ −0.5 D, (2) documented progression of myopia ≥0.5 D in the last 6 months, (3) astigmatism <2.00 D, and (4) willingness for regular follow-up were included in this study.

Exclusion criteria

(1) Coexisting ocular diseases such as cataract, glaucoma, retinal diseases, and nystagmus; (2) systemic diseases such as cardiac, endocrine, neurologic, and respiratory diseases; (3) history of ocular surgery in the past; (4) allergy to atropine; (5) previous use of atropine; and (6) use of other optical methods for myopia control such as bifocals/orthokeratology lens were excluded from this study.

Variables studied before and after starting low-dose atropine were as follows: (1) best-corrected visual acuity (BCVA) for distance and near; (2) ocular alignment for distance and near; (3) near point of accommodation (NPA); (4) near point of convergence (NPC); (5) axial length (AXL); (6) photopic pupil diameter (PDM); (7) lens thickness (LT); (8) anterior chamber depth (ACD); (9) spherical equivalent (SE) of myopia from cycloplegic refraction; and (10) adverse reactions, compliance, and dropouts.

Patients were evaluated at the initiation of treatment, at 1 month, and thereafter every 6 months with the above

parameters. The minimum follow-up was of 6 months. BCVA for distance was measured in logarithm of the minimum angle of resolution (logMAR), with Early Treatment Diabetic Retinopathy Study chart. Near visual acuity was tested using spectacle correction with a reduced logMAR chart placed at 33 cm. Ocular alignment for distance and near was evaluated with cover/uncover tests over spectacle correction. The NPA and NPC were measured using a Royal Air Force (RAF) rule with spectacle correction in place. AXL, PDM, LT, and ACD were measured using A Scan Biometer (LENSTAR LS 900-HAAG STREIT USA) before cycloplegic refraction. Cycloplegic refraction was done with CTC drops (1 drop of cyclopentolate 1%, 1 drop of tropicamide 1%, and 1 drop of cyclopentolate 1% instilled 10 min apart) and performed 30 min after the last drop, using an autorefractor (Topcon KR-800). SE of each eye was calculated as spherical power plus half of the cylinder power. Participants were prescribed glasses and asked to instill atropine 0.01% eye drops (MYOPIN-Appasamy Associates or MYATRO-Entod Pharmaceuticals Ltd) every day at bedtime and report any adverse reactions at 1 month of usage and thereafter every 6 months. Compliance was assessed as good if the parents reported instilling low-dose atropine drops at bedtime at least 5 days a week and poor if they defaulted more than 2 days a week.

The parents and the children were verbally asked for any difficulty in daily activities indoors at school and outdoors at each visit. The primary outcome was progression of myopia, defined as change in SE over Phase 1 (6 months). An increase in SE of myopia was taken as progression. Rapid progression of myopia was considered if there was a ≥0.5 DS increase in SE of myopia within 6 months. All the study variables were compared with those of age-matched normals which formed the control group. Statistical analysis was performed using Minitab 19 version and SPSS (2007) for Windows, Version 16.0. (Chicago, IL, USA). 16.0 version, and *P* values were calculated using Z-test, Wilcoxon signed-rank test, paired *t*-test, two-sample *t*-test, and Mann–Whitney U-test.

RESULTS

Out of the 62 children who were enrolled for the low-dose atropine therapy, only 71 eyes of 36 children (18 males and 18 females) were included in the study group as the rest were lost for follow-up or excluded due to poor compliance to the drops. Similarly, fifty children who chose not to use low-dose atropine were enrolled as the control group, but only 37 eyes of 19 children were included in the final control group. The mean age was 8.31 years (standard deviation [SD] =1.191) in the cases compared to 9.68 years (SD = 3.606) in the controls. The mean SE of myopia in the study group was −5.38 D initially as compared to −5.35 D in the control group and increased by 0.28 D to −5.66 D in the study group as compared to 0.63 D increase (−5.98 D) among the controls ($P = 0.01$) at the end of 6 months [Figure 1]. Progression of myopia was noted in 40 eyes (56.338%) in the study group as compared to 35 eyes (94.59%) in the control group ($P = 0.00$) [Table 1]. Rapid progression was noted in 23 eyes (32.39%) in the study group as compared to 23 eyes (62.16%) in the control group ($P < 0.0001$) and this was statistically significant ($P = 0.003$) [Table 2]. The mean AXL increased by 0.14 mm in the study group as compared to 0.25 mm among the controls ($P = 0.01$) at the end of 6 months [Figure 2]. There was also a statistically significant increase in mean PDM by 0.83 mm ($P = 0.01$) [Figure 3] and receding of mean NPA by 1.14 cm in the study group ($P = 0.03$) [Figure 4], however, there was no change or loss in distance or near BCVA and these changes were clinically insignificant. No significant changes were noted in ACD, LT, NPC, distance and near BCVA, and ocular alignment in the study and control groups. No adverse reactions were reported.

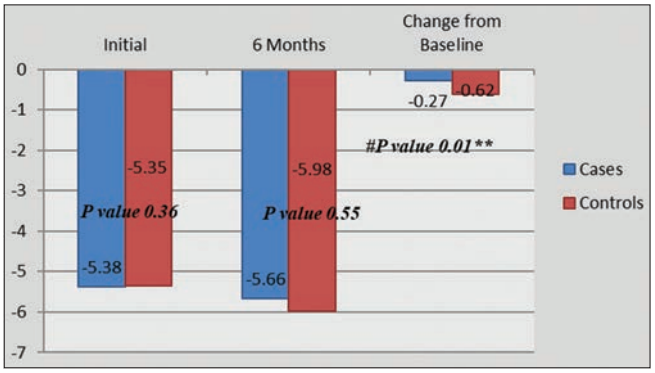

Figure 1: Mean spherical equivalent across two groups. #Mann–Whitney U-test used to find the *P* value, **Statistically significant

Table 1: Progression of myopia at 6 months (cases and controls)

	n	Progression at 6 months, *n* (%)	*P*$
SE: Controls	37	35 (94.59)	0.00**
SE: Cases	71	40 (56.338)	

** $P<0.05$, Statistically significant, $Z-test was used to find the *P* value. SE – Spherical equivalent

Table 2: Rapid progression of myopia at 6 months (cases and controls)

	n	Progression at 6 months, *n* (%)	*P*$
SE: Controls	37	23 (62.16)	0.003**
SE: Cases	71	23 (32.39)	

**Statistically significant, $Z-test was used to find the *P* value. SE – Spherical equivalent

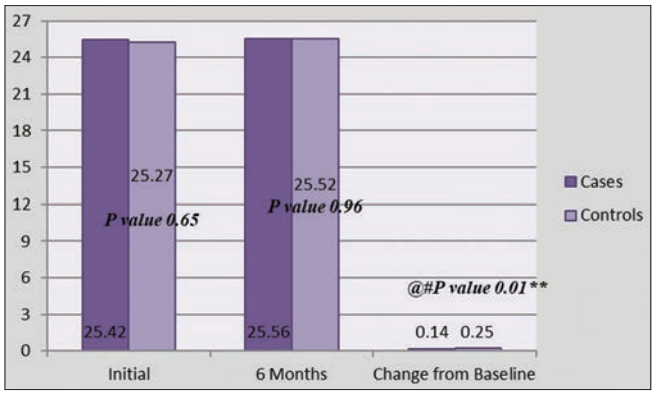

Figure 2: Mean axial length across two groups. @Two-sample *t*-test, #Mann–Whitney U-test used to find the *P* value, **Statistically significant

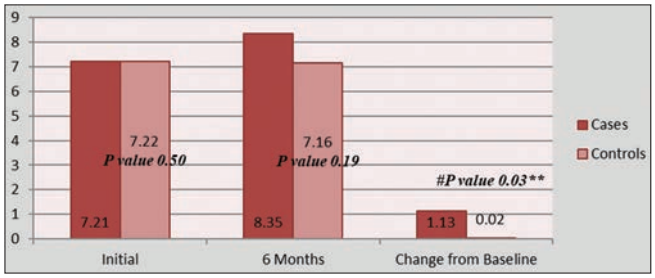

Figure 3: Mean near point of accommodation across two groups. #Mann–Whitney U-test used to find the *P* value, **Statistically significant

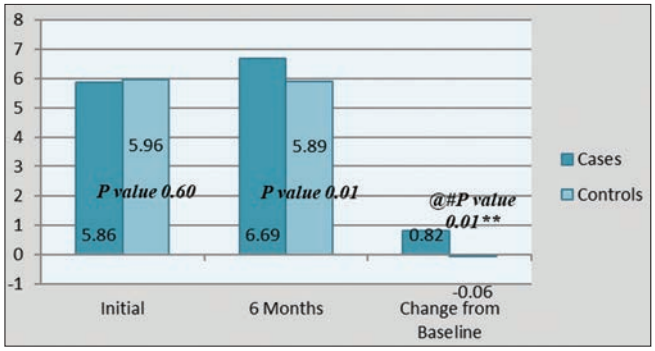

Figure 4: Mean pupil diameter across two groups. @Two-sample *t*-test, #Mann–Whitney U-test used to find the *P* value, **Statistically significant

DISCUSSION

In this clinical trial of low-dose atropine in 71 eyes of 36 children, there were statistically significant changes from baseline in SE of myopia, AXL, PDM, and NPA in cases at the end of 6 months. Despite low-dose atropine therapy, myopia progressed in 56.338% of eyes and rapid progression happened in 32.39% of eyes in the study group, however, this increase was much lower than age-matched controls, in whom 94.59% progressed and rapid progression occurred in 62.16% of eyes. AXL elongation also was much more among controls than in the study group. Low-dose atropine was well tolerated by all children despite pupil dilatation and accommodation loss. The vision-related quality of life was not affected. BVCA for distance and near was well preserved and no adverse reactions were reported at the end of 6 months.

Several studies have shown that atropine eye drops are effective in slowing myopia progression in young children. In a randomized controlled trial involving 400 children aged 6–12 years, ATOM 1, it was found that over a 2-year period, atropine 1% eye drops slowed myopia progression to −0.28+-0.92 compared with −1.20+−0.69 D in the placebo group, with a 77% reduction in myopia progression with no axial elongation.[17] However, the associated blurred near vision, photophobia, and risk of increased ultraviolet exposure deter parents from widely adopting the treatment. In the ATOM 2 trial, 0.5%, 0.1%, and 0.01% atropine slowed myopia progression to −0.3+−0.60 D, −0.38+−0.60 D, and −0.49+−0.63 D, respectively, over 2 years.[18] Overall, myopia progression and change in axial elongation at the end of 5 years were lowest in the 0.01% group (−1.38+−0.98 D and 0.75+−0.48 mm, respectively). Atropine 0.01% also caused minimal pupil dilation (0.8 mm), minimal loss of accommodation (2–3 D), and no near visual loss compared with higher doses. We too got statistically significant less progression of myopia (−0.28+−0.47 D) in the study group as compared to controls (−0.63+−0.6 D) and less AXL elongation in cases (0.14+−0.129 mm) as compared to controls (0.25+−0.22 mm). The mean increase in photopic PDM was 0.82+−1.357 mm and the mean loss of accommodation was 1.89 D in the study group, which were comparable to ATOM 2. ATOM 2 was limited by the lack of a control group, but we had an age-matched control group. In another randomized, double-blinded, placebo-controlled trial of 0.05%, 0.025%, and 0.01% atropine eye drops in myopia control, called the Low-Concentration Atropine for Myopia Progression (LAMP 1) study,[19] the mean SE change was −0.59+−0.61 D and −0.81+−0.53 D in the 0.01% atropine groups and placebo groups, respectively ($P < 0.001$), after 1 year, with a respective mean increase in AL of 0.36+−0.29 mm and 0.41+−0.22 mm ($P < 0.001$), which were comparable to our results [Table 3]. The accommodation amplitude loss was 0.26+−3.04 D in 0.01% atropine and 0.32+−2.91 D in placebo in LAMP study and was lower than ATOM 2 and our study. The photopic pupil sizes increased, respectively, by 0.49+−0.80 mm in the 0.01% atropine group and 0.13+−1.07 mm in the placebo group ($P < 0.001$) and again were lower than ATOM 2 and our study. Visual acuity and vision-related quality of life were not affected in each group. Kothari and Rathod studied the efficacy of 1% atropine eye drops for myopia in Indian eyes and found that baseline rate of progression was reduced from −0.6 D/year to −0.2 D/year after 1% atropine therapy

Table 3: Comparison with other published studies

	ATOM 2		LAMP 1		AIM (our study)	
	ATOM 2 cases	ATOM 2 control	LAMP cases	LAMP control	AIM cases	AIM control
Duration (years)	5	5	1	1	0.5	0.5
SE of myopia (D)	−1.38+−0.98		−0.59+−0.61	−0.81+−0.53	−0.28+−0.47	−0.63+−0.6
AXL (mm)	0.75+−0.48		0.36+−0.29	0.41+−0.22	0.14+−0.129	0.25+−0.22
PDM (mm)	0.8		0.49+−0.8	0.13+−1.07	0.82+−1.357	−0.006+0.44
Accommodation loss (D)	2-3				1.89	+0.116 (gain)

ATOM – Atropine for the Treatment of Myopia, LAMP – Low-Concentration Atropine for Myopia Progression, SE – Spherical equivalent, AXL – Axial length, PDM – Pupil diameter, AIM – Atropine in myopia

although progressive addition photo Gray lenses had to be prescribed to avoid photophobia.[20] The only published study in the Indian population with 0.01% atropine, the recent I-ATOM[21] study, noted a significant reduction of 54% reduction in mean SE progression with 0.01% atropine. Ours is probably the only other case – control trial to provide good evidence of efficacy and safety of low-concentration atropine in retarding myopia progression in Indian eyes.

The fact that, despite good compliance in our study, 56.338% of study eyes progressed with 32.39% showing rapid progression raises some relevant questions:

(1) Is 0.01% ideal for all ages and ethnicities? (2) Is the effect different in differently pigmented eyes and in different races? (3) How to manage the rapid progressors? (4) Can we stop after the peak effect is got in the 2nd year as per ATOM studies? (5) Should we abruptly stop or taper the drops?

There are very few studies on the use of low dose atropine use in Indian eyes and almost all studies published are from East Asia. Only few studies have analysed the changes in axial length,pupil size,accomodation,convergence,lens thickness,ocular alignment along with the change in spherical equivalent of myopia in low dsoe atropine users; which in turn help us in understanding the vision related quality of life with low dose atropine use. The drawbacks of our study are the possibility of selection and reporting bias due to the nonmasked, nonrandomized nature of the trial, small sample size, and shorter duration. The mean age in our study group was 8.306 years as compared to 9.68 in the control group, and this age difference may be clinically significant in the context of myopia and may have affected the evaluation. We hope to get more cases, longer follow-up, and solutions to unanswered questions as the study progresses to Phase II (1 year).

CONCLUSION

Low-dose atropine (0.01%) therapy was able to reduce the progression of myopia in the study group as compared to the controls with a good tolerance and no change in the vision-related quality of life. Long-term follow-up is, however, needed for extrapolation into the general population.

Financial support and sponsorship

Nil.

Conflicts of interest

There are no conflicts of interest.

REFERENCES

1. Morgan IG, Ohno-Matsui K, Saw SM. Myopia. Lancet 2012;379:1739-48.
2. Pan CW, Ramamurthy D, Saw SM. Worldwide prevalence and risk factors for myopia. Ophthalmic Physiol Opt 2012;32:3-16.
3. Vitale S, Sperduto RD, Ferris FL. Increased prevalence of myopia in the United States between 1971–1972 and 1999–2004. Arch Ophthalmol 2009;127:1632-9.
4. Matsumura H, Hirai H. Prevalence of myopia and refractive changes in students from 3 to 17 years of age. Surv Ophthalmol 1999;44 Suppl 1:S109-15.
5. Yoon KC, Mun GH, Kim SD, Kim SH, Kim CY, Park KH, *et al.* Prevalence of eye diseases in South Korea: Data from the Korea National Health and Nutrition Examination Survey 2008–2009. Korean J Ophthalmol 2011;25:421-33.
6. Saw SM, Tong L, Chua WH, Chia KS, Koh D, Tan DT, *et al*. Incidence and progression of myopia in Singaporean school children. Invest Ophthalmol Vis Sci 2005;46:51-7.
7. Lin LL, Shih YF, Hsiao CK, Chen CJ. Prevalence of myopia in Taiwanese schoolchildren: 1983 to 2000. Ann Acad Med Singap 2004;33:27-33.
8. Lam CS, Lam CH, Cheng SC, Chan LY. Prevalence of myopia among Hong Kong Chinese schoolchildren: Changes over two decades. Ophthalmic Physiol Opt 2012;32:17-24.
9. You QS, Wu LJ, Duan JL, Luo YX, Liu LJ, Li X, *et al*. Prevalence of myopia in school children in greater Beijing: The Beijing Childhood Eye Study. Acta Ophthalmol 2014;92:e398-406.
10. Dandona R, Dandona L, Srinivas M, Sahare P, Narsaiah S, Muñoz SR, *et al.* Refractive error in children in a rural population in India. Invest Ophthalmol Vis Sci 2002;43:615-22.
11. Murthy GV, Gupta SK, Ellwein LB, Muñoz SR, Pokharel GP, Sanga L, *et al.* Refractive error in children in an urban population in New Delhi. Invest Ophthalmol Vis Sci 2002;43:623-31.
12. Pokharel GP, Negrel AD, Munoz SR, Ellwein LB. Refractive error study in children: Results from Mechi Zone, Nepal. Am J Ophthalmol 2000;129:436-44.
13. Saxena R, Vashist P, Tandon R, Pandey RM, Bhardawaj A, Menon V, *et al*. Prevalence of myopia and its risk factors in urban school children in Delhi: The North India Myopia Study (NIM Study). PLoS One 2015;10:e0117349.

14. Lim MC, Gazzard G, Sim EL, Tong L, Saw SM. Direct costs of myopia in Singapore. Eye (Lond) 2009;23:1086-9.
15. Vitale S, Cotch MF, Sperduto R, Ellwein L. Costs of refractive correction of distance vision impairment in the United States, 1999-2002. Ophthalmology 2006;113:2163-70.
16. Wu PC, Huang HM, Yu HJ, Fang PC, Chen CT. Epidemiology of myopia. Asia Pac J Ophthalmol 2016;5:386-93.
17. Chua WH, Balakrishnan V, Chan YH, Tong L, Ling Y, Quah BL, *et al*. Atropine for the treatment of childhood myopia. Ophthalmology 2006;113:2285-91.
18. Chia A, Chua WH, Cheung YB, Wong WL, Lingham A, Fong A, *et al*. Atropine for the treatment of childhood myopia: Safety and efficacy of 0.5%, 0.1%, and 0.01% doses (ATOM2). Ophthalmology 2012;119:347-54**.**
19. Yam JC, Jiang Y, Tang SM, Law AK, Chan JJ, Wong E, *et al*. Low-concentration atropine for myopia progression (LAMP) study. Ophthalmology 2019;126:113-24.
20. Kothari M, Rathod V. Efficacy of 1% atropine eye drops for myopia in Indian eyes. Indian J Ophthalmol 2017;65:1178-81.
21. Saxena R, Dhiman R, Gupta V, Kumar P, Matalia J, Roy L, *et al*. Atropine for treatment of childhood myopia in India (I-ATOM): Multicentric randomized trial. Ophthalmology 2021;128:1367-9.

Original Article

Agreement of gonioscopy and anterior segment-optical coherence tomography in the assessment of the anterior chamber angle: A cross-sectional study

ABSTRACT

Purpose: The aim of the study was to evaluate the inter instrument agreement between gonioscopy and anterior segment optical coherence tomography (AS-OCT) in the assessment of the anterior chamber angle (ACA) in eyes with all Van Herick's grades. **Methods:** A single examiner performed AS-OCT and gonioscopy with a Goldman single mirror for all study patients. An angle opening distance at 500 μm from the scleral spur in the AS-OCT was considered as the quantitative parameter to assess the ACA. A closed ACA on AS-OCT was defined by the presence of any contact between the iris and angle wall anterior to scleral spur. The agreement between gonioscopy and AS-OCT of the nasal and temporal angles was estimated using the Kappa statistic and the concordance between the instruments using the Lin's concordance coefficient. **Results:** The mean age of the seventy participants in the study was 52.11 ± 5.37 years. Five (15.15%) of nasal angles and 4 (12.12%) of temporal angles identified as closed by gonioscopy were called as open by AS-OCT. The Kappa statistic (0.59), pairwise correlation (0.60), and Lin's concordance correlation coefficient (0.59) showed only moderate agreement and concordance between AS-OCT and gonioscopy. AS-OCT had a moderate sensitivity (73%) and better specificity (86.4%). **Conclusion:** The results of our study show that AS-OCT can be used as a clinical diagnostic test but has limited use as a screening test for ACA. The significant proportion of subjects with a mismatch in the categorization of open and closed ACA and the moderate agreement highlights the need for better objective diagnostic criteria for closed ACA.

Keywords: Agreement, anterior chamber angles, concordance, glaucoma, gonioscopy, optical coherence tomography

INTRODUCTION

Glaucoma is a major cause for blindness and vision impairment worldwide. An estimated 237 million people worldwide have moderate-to-severe vision impairment in 2020 that includes 4.5 million people with glaucoma.[1] Blindness is prevalent in an estimated 38.5 million people worldwide in 2020 that includes 3.2 million people with glaucoma.[1] An estimated 11.76 million individuals (32.65% of the global blindness) were blind, and 61.19 million individuals (28.3% of the global total) had moderate-to-severe vision impairment in south Asia in 2015. Glaucoma was a leading cause of both blindness (5.81%) and moderate-to-severe vision impairment (1.09%) in South Asia.[2] Population-based studies from south India have reported a prevalence of 0.5%–4.3% for primary angle closure glaucoma[3-6] and 1.62%–3.51% for open angle glaucoma.[7,8]

Glaucoma is categorized as two broad categories – open and closed – based on the structure of the anterior chamber angle (ACA). The determination of the structure of the angle is an important consideration in the management of glaucoma. Aqueous humor outflow through the trabecular meshwork can be impaired by partial or complete closure of the ACA and lead to elevated intraocular pressure (IOP) and glaucomatous optic neuropathy. Gonioscopy is the current gold standard

K. Jaseena, P. S. Rekha[1]

Department of Ophthalmology, Government Medical College, Thrissur, [1]Department of Ophthalmology, Government Medical College, Manjeri, Kerala, India

Address for correspondence: Dr. P. S. Rekha,
Assistant Professor, Department of Ophthalmology, Government Medical College, Manjeri, Malappuram, Kerala.
E-mail: drrekhaps@gmail.com

Submitted: 20-Apr-2021 **Revised:** 01-May-2021
Accepted: 10-May-2021 **Published:** 21-Apr-2022

Access this article online	
Website: www.kjophthal.com	Quick Response Code
DOI: 10.4103/kjo.kjo_91_21	

This is an open access journal, and articles are distributed under the terms of the Creative Commons Attribution-NonCommercial-ShareAlike 4.0 License, which allows others to remix, tweak, and build upon the work non-commercially, as long as appropriate credit is given and the new creations are licensed under the identical terms.

For reprints contact: WKHLRPMedknow_reprints@wolterskluwer.com

How to cite this article: Jaseena K, Rekha PS. Agreement of gonioscopy and anterior segment-optical coherence tomography in the assessment of the anterior chamber angle: A cross-sectional study. Kerala J Ophthalmol 2022;34:27-31.

to determine the structure of the ACA and is widest inferior, narrowest superior with the temporal and nasal sectors being intermediate in width.[9-11] Anterior segment optical coherence tomography (AS-OCT) is a noncontact imaging method that measures optical reflections to assess the anterior segment and its structures through the acquisition of cross-sectional images.[12] Noncontact examination techniques are preferred during the COVID-19 pandemic and can provide an alternate to assess the ACA compared to gonioscopy which is a contact technique. We designed a cross-sectional study to quantify the concordance and agreement for AS-OCT with the gold standard gonioscopy to assess the nasal and temporal ACA among patients attending a glaucoma outpatient unit at a tertiary care public sector teaching hospital in central Kerala.

METHODS

The institutional ethics committee approved the study protocol, and informed consent was obtained from all eligible participants before enrollment in the study. The study recruited subjects from the outpatient and glaucoma units of the department of ophthalmology at the study institute. Patients aged >20 years, presenting with any ophthalmic complaint, who could sit comfortably for a gonioscopy examination and provided informed consent were enrolled consecutively in the study after obtaining informed consent. The study excluded subjects with corneal pathology or corneal endothelial decompensation or with a history of previous intraocular surgery. The sample size was estimated as 75 eyes using the R software, a precision of 20%, and an anticipated kappa of 0.5%.

A comprehensive ophthalmic examination included visual acuity assessments, refractive status, slit-lamp assessment of the anterior segment, applanation tonometry for IOP assessments, and posterior segment assessments. A single examiner performed AS-OCT and gonioscopy for all patients enrolled in the study. Gonioscopy was performed using Goldman single mirror with the eye in the primary position of gaze. The ideal testing condition included a dim room illumination, minimal intensity of slit-lamp illumination, and without application of any pressure on the eye with the gonioscope. ACA in each of the quadrant was graded by Schaffer's grading system. AS-OCT was performed in a dark room by a single operator for all patients. We considered the angle opening distance (AOD) at 500 μm from the scleral spur as the quantitative parameter to assess the ACA. A closed ACA on AS-OCT was defined by the presence of any contact between the iris and angle wall anterior to scleral spur.

Data were initially entered in an MS Excel spreadsheet and subsequently exported to the STATA statistical software (STATA V13.0, College Station, Tx, USA) for analysis. The normal distribution of data was assessed using the Shapiro–Wilk test which showed normality of data. The mean, median, and interquartile ranges of age and IOPs were determined. The ACA determined by gonioscopy and AS-OCT was assessed for overall correlation, and correlation in the nasal and temporal segments using a pairwise correlation test. The Lin's concordance correlation coefficient was determined to further explore agreement between the two instruments.[13] The concordance correlation coefficient combines measures of both precision and accuracy to determine how far the observed data deviate from the line of perfect concordance.[13] Lin's coefficient increases in value as a function of the nearness of the data's reduced major axis to the line of perfect concordance (the accuracy of the data) and of the tightness of the data about its reduced major axis (the precision of the data).[13] The Pearson correlation coefficient, the bias correction factor, and the equation of the reduced major axis show these components. The concordance correlation coefficient is expressed as the product of the measure of precision and the measure of accuracy. A concordance coefficient of 0 indicates no concordance and a coefficient of 1 indicates perfect concordance.[13] The Bland and Altman's Limits of agreement were also determined to examine patterns of disagreement between gonioscopy and AS-OCT.[14] The correlation between difference and mean was also assessed as a part of the concordance correlation coefficient estimation and a value near zero implies concordance.[15] A Bradley Blackwood *F*-test of equality of means and variances was used; a nonsignificant *P* value indicates concordance.[16] We also estimated the overall agreement between gonioscopy and AS-OCT and by nasal and temporal segments and estimated a kappa statistic for agreement.[17] A one-way analysis of variance (ANOVA) test was used to compare the mean AOD by grade of ACA in both the nasal and temporal segments. The diagnostic effectiveness of AS-OCT compared to gonioscopy was assessed using sensitivity, specificity, predictive values, likelihood ratios, and area under receiver operator characteristic curve (AUROC).

RESULTS

The study included seventy eyes. The mean ± standard deviation (SD) age of participants in the study was 52.11 ± 5.37 years (median: 51.0 years; inter quartile range: 48–60 years). Forty-six (65.71%) patients were females. The mean ± SD age of IOP was 14.86 ± 2.98 mmHg (median: 14.00 mmHg, interquartile range: 12–16 mmHg). Table 1 shows the distribution of Van Hericks grade in the study population. Table 2 shows the assessment of ACAs by gonioscopy and AS-OCT. AS-OCT agreed with the grading

of the ACA in 84.85% of nasal angles and 87.88% of temporal angles identified as closed by gonioscopy and 75.67% of nasal angles and 70.27% of temporal angles identified as open by gonioscopy. Five (15.15%) of nasal angles and 4 (12.12%) of temporal angles identified as closed by gonioscopy were called as open by AS-OCT. Table 3 presents the agreement and concordance between gonioscopy and AS-OCT. The broader examination of agreement and concordance between AS-OCT and gonioscopy suggested good results; however, further examination with the Kappa statistic (0.59), pairwise correlation (0.60), and Lin's concordance correlation coefficient (0.59) showed only moderate agreement and concordance between AS-OCT and gonioscopy [Table 3]. Table 4 presents the AOD by van Hericks grades in the nasal and temporal segments with a change in the AOD in both the nasal and temporal ACA (both $P < 0.001$, one-way ANOVA). Table 5 presents the diagnostic effectiveness of AS-OCT compared to gonioscopy as the gold standard for the assessment of ACA. The sensitivity (73%, 95% confidence interval [CI]: 61.4%, 82.6%) of AS-OCT was moderate with a better specificity (86.4%, 95% CI: 75.7%, 93.6%). The positive likelihood ratio (LR+) for AS-OCT was 5.35 (95% CI: 2.87, 9.98).

Table 1: Distribution of Van Hericks grade in the study population

Van Hericks Grade	*n* (%)
Grade 1	13 (18.57)
Grade 2	36 (51.43)
Grade 3	13 (18.57)
Grade 4	8 (11.43)

Table 2: Assessment of anterior chamber angles by gonioscopy and anterior segment optical coherence tomography

Gonioscopy	AS-OCT closed (*n*)	AS-OCT open (*n*)
Nasal closed ($n=33$)	28	5
Nasal open ($n=37$)	9	28
Temporal closed ($n=33$)	29	4
Temporal open ($n=37$)	11	26

AS-OCT - Anterior segment optical coherence tomography

DISCUSSION

The results of our cross-sectional study show only moderate agreement and concordance between AS-OCT and gonioscopy for the assessment of ACA in this population. We found that 5 (15.15%) of nasal angles and 4 (12.12%) of temporal angles identified as closed by gonioscopy were called as open by AS-OCT. A LR+ >10 generally indicates that the test can be applied to a clinical population; however, we found a LR + of 5.35 for AS-OCT in this study although the upper limit of the 95% confidence interval was just below 10.

Previous studies have reported on the moderate agreement between AS-OCT and gonioscopy similar to our study results. Sakata *et al*. reported a kappa of 0.40 for agreement between AS-OCT and gonioscopy in a cross-sectional study from Singapore.[18] They suggested that variations in the iris profile and level of iridoangle contact also may explain some of the differences seen between gonioscopy and AS-OCT. Anatomic variations of the ACA have been previously described based on gonioscopic examinations and AS-OCT imaging and are well recognized.[2,10,11] A study from South Korea[19] reported a poor kappa between gonioscopy and AS-OCT although the discrimination capability of AS-OCT parameters between

Table 3: Agreement and concordance between gonioscopy and anterior segment optical coherence tomography in the study population

	Overall	Nasal	Temporal
Agreement (%)	79.29	80.00	78.57
κ	0.59	0.60	0.57
Pair wise correlation	0.60	0.60	0.59
Concordance correlation coefficient	0.59	0.60	0.58
Measure of precision	0.59	0.60	0.59
Measure of accuracy	0.99	0.99	0.98
Bland altman plot 95% limits of agreement	−0.80, 0.96	−0.82, 0.93	−0.79, 0.99
Correlation between difference and mean	0.004	0.00	0.01
Bradley blackwood *F*, *P*	2.12, 0.12	0.56, 0.57	1.67, 0.20

Table 4: Angle opening distance by Van Hericks grades in the nasal and temporal segments

Van Hericks grades	Mean angle opening distance (μm±SD), nasal	Mean angle opening distance (μm±SD), temporal
Grade 1	115.76±41.68	108.46±33.58
Grade 2	253.38±73.78	238.86±82.37
Grade 3	321.54±112.03	309.69±115.69
Grade 4	483.12±76.38	464.75±75.38

SD - Standard deviation

Table 5: Diagnostic effectiveness of anterior segment spectral domain-optical coherence tomography and gonioscopy for anterior chamber angle assessment

Parameter	Estimate (95% CI)
Sensitivity	73 (61.4-82.6)
Specificity	86.4 (75.7-93.6)
Positive predictive value	85.7 (74.6-93.3)
Negative predictive value	74 (62.8-83.4)
Positive likelihood ratio	5.35 (2.87-9.98)
Negative likelihood ratio	0.31 (0.21-0.46)
Area under ROC curve	0.80 (0.73-0.86)

CI - Confidence interval, ROC - Receiver operating characteristic

open and narrow angles determined by gonioscopy was excellent for all AS-OCT parameters (AUROC 0.99 for nasal and 0.96 for temporal). The results of our study suggest good discriminative ability with AUROC of 0.80 for nasal and 0.79 for temporal angles. A previous review[20] has also reported a good sensitivity and moderate agreement between gonioscopy and AS-OCT in the determination of closed ACA.

There are several ocular factors to consider for the possible differences between AS-OCT and gonioscopy besides factors such as the experience and skill of the assessors. Gonioscopy requires contact with the corneal surface, which can distort the cornea and affect ACA configuration and it is possible that gonioscopy technique can affect the determination of closed or open ACA. All measurements were done by a single investigator in this study and the possibility of a systematic bias in the assessment cannot be ruled out. A previous study has reported from angle visibility index analyses that it is more difficult to visualize and assess the configuration of the ACA in the temporal and nasal quadrants.[18,21] It is possible that small lighting condition changes affected pupil size, an important determinant of ACA configuration and AS-OCT measurements,[22] although examinations were done in a controlled setting with minimized lighting.

CONCLUSION

The results of our study suggest that direct visual assessments of the ACA may not accurately reflect its width and could be affected by other factors such as the configuration of the iris. These findings highlight some of the diagnostic challenges that clinicians face when attempting to visualize and interpret the nasal and temporal quadrants using gonioscopy. The results of our study show that AS-OCT can be considered as a clinical diagnostic test for the confirmation of the ACA but may have limited use as a screening test. The significant proportion of subjects that have a mismatch in the categorization of open and closed ACA and the moderate agreement highlights the need to have better diagnostic classification systems for closed ACA that can be objectively assessed.

Financial support and sponsorship

Nil.

Conflicts of interest

There are no conflicts of interest.

REFERENCES

1. Flaxman SR, Bourne RR, Resnikoff S, Ackland P, Braithwaite T, Cicinelli MV, *et al.* Vision loss expert group of the global burden of disease study. Global causes of blindness and distance vision impairment 1990-2020: A systematic review and meta-analysis. Lancet Glob Health 2017;5:e1221-34.
2. Nangia V, Jonas JB, George R, Lingam V, Ellwein L, Cicinelli MV, *et al.* Vision loss expert group of the global burden of disease study. Prevalence and causes of blindness and vision impairment: Magnitude, temporal trends and projections in South and Central Asia. Br J Ophthalmol 2019;103:871-7.
3. Jacob A, Thomas R, Koshi SP, Braganza A, Muliyil J. Prevalence of primary glaucoma in an urban south Indian population. Indian J Ophthalmol 1998;46:81-6.
4. Ramakrishnan R, Nirmalan PK, Krishnadas R, Thulasiraj RD, Tielsch JM, Katz J, *et al.* Glaucoma in a rural population of southern India: The Aravind comprehensive eye survey. Ophthalmology 2003;110:1484-90.
5. Vijaya L, George R, Arvind H, Baskaran M, Paul PG, Ramesh SV, *et al.* Prevalence of angle-closure disease in a rural southern Indian population. Arch Ophthalmol 2006;124:403-9.
6. Dandona L, Dandona R, Mandal P, Srinivas M, John RK, McCarty CA, *et al.* Angle-closure glaucoma in an urban population in southern India. The Andhra Pradesh eye disease study. Ophthalmology 2000;107:1710-6.
7. Vijaya L, George R, Baskaran M, Arvind H, Raju P, Ramesh SV, *et al.* Prevalence of primary open-angle glaucoma in an urban south Indian population and comparison with a rural population. The Chennai glaucoma study. Ophthalmology 2008;115:648-54.e1.
8. Dandona L, Dandona R, Srinivas M, Mandal P, John RK, McCarty CA, *et al.* Open-angle glaucoma in an urban population in southern India: The Andhra Pradesh eye disease study. Ophthalmology 2000;107:1702-9.
9. He M, Foster PJ, Ge J, Huang W, Wang D, Friedman DS, *et al.* Gonioscopy in adult Chinese: The liwan eye study. Invest Ophthalmol Vis Sci 2006;47:4772-9.
10. Tun TA, Baskaran M, Perera SA, Chan AS, Cheng CY, Htoon HM, *et al.* Sectoral variations of iridocorneal angle width and iris volume in Chinese Singaporeans: A swept-source optical coherence tomography study. Graefes Arch Clin Exp Ophthalmol 2014;252:1127-32.
11. Xu BY, Israelsen P, Pan BX, Wang D, Jiang X, Varma R. Benefit of measuring anterior segment structures using an increased number of optical coherence tomography images: The Chinese American eye study. Invest Ophthalmol Vis Sci 2016;57:6313-9.
12. Izatt JA, Hee MR, Swanson EA, Lin CP, Huang D, Schuman JS, *et al.* Micrometer-scale resolution imaging of the anterior eye *in vivo* with optical coherence tomography. Arch Ophthalmol 1994;112:1584-9.
13. Lin L. A note on the concordance correlation coefficient. Biometrics 2000;56:324-5.
14. Bland JM, Altman DG. Statistical methods for assessing agreement between two methods of clinical measurement. Lancet 1986;1:307-10.
15. Snedecor GW, Cochran WG. Statistical Methods. Ames, IA: Iowa State University Press; 1989.
16. Bradley EL, Blackwood LG. Comparing paired data: A simultaneous test for means and variances. Am Statist 1989;43:234-5.
17. Byrt T, Bishop J, Carlin JB. Bias, prevalence and kappa. J Clin Epidemiol 1993;46:423-9.

18. Sakata LM, Lavanya R, Friedman DS, Aung HT, Gao H, Kumar RS, *et al*. Comparison of gonioscopy and anterior segment ocular coherence tomography in detecting angle closure in different quadrants of the anterior chamber angle. Ophthalmology 2008;115:769-74.
19. Park SB, Sung KR, Kang SY, Jo JW, Lee KS, Kook MS. Assessment of narrow angles by gonioscopy, Van Herick method and anterior segment optical coherence tomography. Jpn J Ophthalmol 2011;55:343-50.
20. Porporato N, Baskaran M, Aung T. Role of anterior segment optical coherence tomography in angle-closure disease: A review. Clin Exp Ophthalmol 2018;46:147-57.
21. Xu BY, Pardeshi AA, Burkemper B, Richter GM, Lin SC, McKean-Cowdin R, *et al*. Differences in anterior chamber angle assessments between gonioscopy, EyeCam, and anterior segment OCT: The Chinese American eye study. Transl Vis Sci Technol 2019;8:5.
22. Leung CK, Cheung CY, Li H, Dorairaj S, Yiu CK, Wong AL, *et al*. Dynamic analysis of dark-light changes of the anterior chamber angle with anterior segment OCT. Invest Ophthalmol Vis Sci 2007;48:4116-22.

Original Article

Demographical and etiological diagnosis of infective corneal ulcer in a tertiary care center in West Bengal: A cross-sectional study

ABSTRACT

Purpose: The purpose was to study the demographical factors and microbial etiology associated with infective keratitis in a tertiary care center in West Bengal. **Materials and Methods:** In this cross-sectional study, 142 patients with suspected microbial keratitis were enrolled from June 2019 to May 2020. After taking the history and diagnosing the infective ulcer clinically, the corneal scrapings and cultures were evaluated. The smears were fixed with Gram stain and 10% potassium hydroxide wet preparation. The scrapped material was inoculated in blood agar and Sabouraud dextrose agar for culture. **Results:** Ocular trauma was the most common predisposing factor in 94 (70.6%) corneal ulcers ($P < 0.0001$). The most common etiologic agent causing corneal injury was wooden object (38.3%). Microbial etiology was established in 76 (53.52%) corneal scrapings. Out of the total culture-positive cases, 45 patients (31.7%) had pure fungal infections, 25 patients (17.6%) had pure bacterial infections, and 6 patients (4.2%) reported mixed infections. Among the fungal pathogens, *Aspergillus* species was the most common fungal isolate (29 cases, 56.8%), followed by *Fusarium* species (17 cases, 33.3%) and *Candida* species (5 cases, 9.8%). The most common bacterial isolate was *Staphylococcus aureus* (16 cases, 51.6%), followed by *Pneumococcus* species (7 cases, 22.5%). **Conclusion:** Trauma with wooden material was the most common predisposing factor for infective keratitis. Fungal ulcers predominated in the study findings. *Aspergillus* species and *S. aureus* were the most common fungal and bacterial isolates, respectively. Regional variations exist in the microbial etiology of infective keratitis.

Keywords: Infective keratitis, microbial etiology, ocular trauma

INTRODUCTION

Corneal ulceration is emerging as a silent epidemic, with India accounting for a large portion of the global burden of infectious keratitis. By definition, a corneal ulcer is a break in the epithelium with underlying stromal necrosis.

Corneal opacities, which are largely caused by infectious keratitis, are the fourth leading cause of blindness globally and responsible for 10% of the avoidable visual impairment in the world's least developed countries.[1,2] In India, it is estimated that approximately 6.8 million people have vision of <6/60 in at least one eye due to corneal diseases; of these, about a million have bilateral involvement.[3] Therefore, trends in infectious keratitis observed in India are important for global public health planning.[4]

Microbial keratitis, if not adequately treated, can have severe consequences. The clinical presentation of corneal ulceration is worsened due to the indiscriminate use of steroids by local doctors and quacks. With definitive identification and treatment, the significant morbidity associated with severe microbial keratitis may be avoided.

Garvita Joshi, Pinaki Sengupta[1], Anindya Gupta[1]

Department of Ophthalmology, Calcutta National Medical College, [1]Department of Ophthalmology, Regional Institute of Ophthalmology, Medical College Campus, Kolkata, West Bengal, India

Address for correspondence: Dr. Anindya Gupta, Regional Institute of Ophthalmology, Medical College Campus, 88 College Street, Kolkata - 700 073, West Bengal, India.
E-mail: agupta.dr@gmail.com

Submitted: 03-Jan-2021 **Revised:** 23-Jan-2021
Accepted: 24-Jan-2021 **Published:** 21-Apr-2022

Access this article online	
Website: www.kjophthal.com	Quick Response Code
DOI: 10.4103/kjo.kjo_1_21	

This is an open access journal, and articles are distributed under the terms of the Creative Commons Attribution-NonCommercial-ShareAlike 4.0 License, which allows others to remix, tweak, and build upon the work non-commercially, as long as appropriate credit is given and the new creations are licensed under the identical terms.

For reprints contact: WKHLRPMedknow_reprints@wolterskluwer.com

How to cite this article: Joshi G, Sengupta P, Gupta A. Demographical and etiological diagnosis of infective corneal ulcer in a tertiary care center in West Bengal: A cross-sectional study. Kerala J Ophthalmol 2022;34:32-6.

The prevalence of visual disability due to corneal opacity varies from one geographical location to another.[5] It is therefore important to recognize these patterns for early diagnosis, institution of therapy, optimal management, and also for the prevention of the disease.

There are several studies establishing the microbial etiology of infective keratitis from various parts of India. However, adequate data are lacking in the eastern part of the country in particular. This study is being done to find the microbial etiology of infective keratitis in a tertiary care center in West Bengal and also to identify the risk factors predisposing to corneal ulceration.

MATERIALS AND METHODS

This study was a teaching hospital-based cross-sectional type of observational study. We took history, performed ophthalmologic examination, and took samples in 142 patients, aged between 10 and 80 years, who presented with a corneal infiltrate that was compatible with the diagnosis of a bacterial or fungal corneal ulcer, at the outpatient clinic of the Department of Ophthalmology, Calcutta National Medical College and Hospital (CNMCH), from June 2019 to May 2020.

The Institutional Ethics Board of CNMCH and West Bengal University of Health Sciences Ethics Committee approved the clinical study. The patients themselves provided written informed consent after being given a detailed explanation of the study. We confirmed that the patients had seen the manuscript and patient data and agreed to its publication in a journal.

Exclusion criteria were as follows: (i) typical or suspected viral ulcers; (ii) Mooren's ulcer, marginal keratitis, interstitial keratitis, and atheromatous ulcers; (iii) any ulcer associated with systemic/autoimmune diseases; (iv) neurotrophic corneal ulcers; and (v) unwilling patients.

Ocular examination and specimen collection

The visual acuity was measured using a Snellen's chart. All the patients were examined under a slit-lamp biomicroscope by an ophthalmologist. The size of the ulcer, size of the stromal infiltrate, and depth were measured and recorded (in millimeters). The ulcer margin, floor, thinning, presence of vascularization, satellite lesions, pigmentation on the ulcer surface, surrounding corneal tissue, and any impacted foreign body were noted. The presence of hypopyon was noted and its height was recorded (in millimeters). The use of topical medications including topical corticosteroids and contact lens wear was noted. Associated ocular conditions such as dry eye, lagophthalmos, chronic dacryocystitis, and corneal anesthesia were noted.

Corneal scraping was performed under strict aseptic conditions by an ophthalmologist using a sterile Bard-Parker blade (No. 15). Fresh proparacaine (0.5%) eye drops were used for topical anesthesia, and the procedure was performed under the magnification of a slit lamp. The material obtained from the leading edge and the base of each ulcer was inoculated into the media and was smeared onto two slides – one for Gram stain and the other for 10% potassium hydroxide wet mount preparation for direct microscopic examination.

Laboratory procedures

All laboratory diagnosis was performed using standard protocols. For bacterial cultures, the material inoculated in blood agar, chocolate agar, and MacConkey agar was incubated at 37°C for 24 h. Examination was done at the end of 24 h and again after 48 h of incubation. If no growth was observed, the plates were discarded. The Sabouraud dextrose agar slope was incubated at room temperature for up to 2 weeks. The first examination was done after 48 h of inoculation, and then, it was reincubated. Further examination was done biweekly for up to 2 weeks to identify the growth of fungal colonies. At the end of the 2nd week, if there was no growth, the slope was discarded as negative.

Microbial cultures were considered to be significant if growth of the same organism could be demonstrated on two or more solid phase cultures. Similiarly, cultures were also significant if there was semiconfluent growth at the site of inoculation or growth on one solid medium consistent with microscopy; or semiconfluent growth at the site of inoculation on one solid medium; or growth of the same organism on repeated scraping. If, by microscopy, hyphae were observed in corneal tissue, but failed to grow in culture, the causative organism was reported as fungal.[6]

In the present study, a specimen was considered microbiologically positive only when the culture results were positive.

Statistical analysis

We made the following analysis and evaluation in patients who presented to us with a corneal infiltrate that was compatible with the diagnosis of a bacterial or fungal corneal ulcer: demographic characteristics, distribution of cases according to occupation, predisposing factors, various agents causing trauma, microbiological diagnosis, first presentation, and medication applied before inclusion in the study.

The categorical variables were expressed as the number of patients and percentage of patients and were compared

across the groups using Fisher's exact test. The statistical software SPSS version 20 has been used for the analysis. An alpha level of 5% has been taken, i.e., if any $P < 0.05$, it has been considered as significant.

RESULTS

Distribution of study population according to age

The age of the patients included in the study ranged from 12 years to 79 years. Majority of the patients (58) were in the age group of 41–60 years (40.8%), $P < 0.001$, with the mean age being 45 ± 16.09 years [Table 1].

Distribution of study population according to gender and residence

In the study participants, there was male predominance ($P < 0.05$) and majority of the patients resided in urban areas (64.08%) [Table 2].

Distribution of cases according to occupation

Majority of the patients in the study group were cultivators and gardeners (28.2%), followed by laborers and industrial workers (24.6%) and homemakers (19.0%) [Table 3].

Distribution of corneal ulcer cases according to predisposing factors

Out of the total 133 patients who had a history of predisposing factors, ocular trauma was the most common predisposing factor ($P < 0.001$) in 94 patients (70.6%). Preexisting ocular disease which included chronic dacryocystitis, dry eye, trichiasis, entropion, and lagophthalmos was seen in 10 patients (7.5%) [Table 4].

Distribution of cases according to various agents causing trauma

The most common agent causing trauma as identified in the study was wooden object (38.3%). This was followed by vegetative matter (22.3%) [Table 5].

Distribution of corneal ulcer cases according to microbiological diagnosis

Microbial etiology was found in 76 out of the 142 cases of corneal ulcers, with 45 cases (31.7%) positive for pure fungal pathogens and 25 cases (17.6%) positive for pure bacterial isolates. Mixed infections (both bacteria and fungi) were found in 4.2% of the cases [Table 6].

Distribution of fungal isolates from corneal ulcer cases

Filamentous fungi predominated in our study while few yeasts (*Candida* species) were also isolated. *Aspergillus* species was the predominant fungal pathogen (58.6%), followed by *Fusarium* species (33.3%) [Table 7].

Distribution of bacterial isolates from corneal ulcer cases

A majority of the bacterial isolates were positive for Gram-positive cocci while only one for Gram-negative

Table 1: Distribution of study population based on age groups (*n*=142)

Age	Frequency, *n* (%)
<20	9 (6.3)
21-40	48 (33.8)
41-60	58 (40.8)
61-80	27 (19)
Total	142 (100.0)

Table 2: Distribution of study population based on residence (*n*=142)

	Male	Female	Total, *n* (%)
Urban	54	37	91 (64.08)
Rural	29	22	51 (35.9)
Total	83	59	142 (100.0)

Table 3: Distribution of study population based on occupation (*n*=142)

Occupation	Frequency, *n* (%)
Cultivator/gardener	40 (28.2)
Laborer/industrial worker	35 (24.6)
Homemaker	27 (19.0)
Business man	13 (9.2)
Student	11 (7.7)
Service	5 (3.5)
Carpenter	2 (1.4)
Others	9 (6.3)
Total	142 (100.0)

Table 4: Distribution of corneal ulcer cases according to different predisposing factors (*n*=142)

Predisposing factors	Frequency, *n* (%)
Trauma	94 (66.2)
Corticosteroids	16 (11.3)
Diabetes mellitus	11 (7.7)
Preexisting ocular disease	10 (7.1)
Contact lens wear	2 (1.4)
None	9 (6.3)
Total	142 (100)

The predisposing were mutually exclusive

Table 5: Frequency distribution of agents causing trauma (*n*=94)

Agents causing trauma	Frequency, *n* (%)
Wooden object	36 (38.3)
Vegetative matter	21 (22.3)
Stone/dirt/mud	15 (16.0)
Metal	9 (9.6)
Sports injury (including blunt trauma)	5 (5.31)
Finger nail trauma	4 (4.3)
Animal matter	4 (4.2)
Total	94 (100.0)

bacilli (GBC). *Staphylococcus aureus* was the most common bacterial pathogen found in 16 cases (51.6%), followed by *Pneumococcus* species seen in 7 cases (22.5%) [Table 7].

DISCUSSION

The external location of the cornea predisposes it to a variety of sight-threatening insults. A wide spectrum of microbial organisms can produce corneal infection. The severity of corneal infection depends on the underlying condition of the cornea and pathogenicity of the infecting organism,[7] and consequently, therapeutic strategies may be variable.[8]

In the present study, corneal ulceration was seen in all the age groups with a preponderance among physically active adults [Table 1]. Male patients outnumbered females in the study (58.45%) ($P < 0.05$), and majority of the patients were from urban areas [Table 2]. This pattern was consistent with most of the earlier observations, such as that reported by Gopinathan *et al*.,[9] and could be attributed to an increased outdoor activity of men, especially in the working age group. In this study, we found that majority of the patients were cultivators and gardeners (28%), followed by laborers and industrial workers (24.6%) [Table 3]. This may be explained by the increased risk of injuries while working in the fields or at the construction site or at the factories. This pattern of occupational profile is consistent with that seen in a South Indian study by Bharathi *et al*.[10] However, this was in contrast to a study done in Ghana where only 16.1% of the patients were agricultural workers.[11] Trauma was the most common predisposing factor (70.6%) [Table 4] similar to the findings of a study in South India.[5] The most common etiologic agent causing corneal injury was wooden object (38.3%), followed by vegetative matter (22.3%) [Table 5]. These figures compare favorably with a study in Ahmedabad,[12] where it was reported that trauma due to wooden objects (34%) was the leading cause of corneal ulceration.

Table 6: Distribution of study cases based on type of infection (*n*=142)

Cases	Frequency, *n* (%)
Pure fungal	45 (31.7)
Pure bacterial	25 (17.6)
Mixed	6 (4.2)
Sterile	66 (46.5)
Total	142 (100.0)

Table 7: The bacterial isolates in patients with bacterial and missed infections (*n*=31)

Bacterial isolates	Pure bacterial	Mixed with fungus	Total, *n* (%)
Staphylococcus aureus	15	1	16 (51.6)
Pneumococcus species	5	2	7 (22.5)
Staphylococcus epidermidis	3	3	6 (19.3)
Enterococcus species	1	-	1 (3.2)
Pseudomonas species	1	-	1 (3.2)
Total	25	6	31 (100.0)

In our study, we observed that about 35 (24.6%) patients presented in their 1st week of illness. This is in contrast to the findings in the study of Srinivasan *et al*.,[5] where most of the patients, i.e., around 60%, were examined within 7 days after the onset of their illness. Medical help was sought by 65.49% of the patients before their initial examination at our outpatient department. It is of interest to note that 11 patients (7.74%) went to village healers. There is a risk of a possible bacterial or fungal contamination of traditional medicine which can lead to deterioration and further progression of corneal ulceration.

We observed that about 97 patients (68.3%) were applying some form of topical medication before their inclusion in the study. In the study, 58 out of 142 cases were applying topical antibiotic drops, 23 patients were on antifungals and antibiotics, and 16 cases were applying corticosteroids. The application of medication before inclusion in the study was statistically significant as a large proportion of ulcer scrapings were sterile (66 cases, 46.48%) ($P < 0.001$).

Microorganisms were isolated from 76 (53.52%) specimens sent for culture [Table 6]. This figure is consistent with the findings of a study in Ghana[11] where 57.3% of all the cultures were positive, but it does not approach the 80% culture positivity rate reported from Nepal by Upadhyay *et al*.[13] The lower rate of isolation can be attributed to the widespread availability of topical medications in West Bengal and their use in the majority of the patients (68.3%) before evaluation. More than half (59.21%) of all corneal ulcers with positive cultures were fungal in origin. If the six mixed infections (7.89%) are also considered to be primarily fungal for treatment purpose and are added to the pure fungal cases, 67.1% of all the culture-positive ulcers grew fungal pathogens. This figure approaches the fungal isolation rate in Ghana where Hagan *et al*.[11] cultured fungi from 56% culture-positive cases. *Aspergillus* species (56.8%) was the predominant fungal agent [Table 7] in line with studies from eastern[14] and western India[12] and in Nepal by Upadhyay *et al*.,[13] where *Aspergillus* species accounted for 47% of all the fungal pathogens. This was followed by *Fusarium* species (33.8%) and *Candida* species (9.8%). Studies from South India[5,10] and South Florida[15] show *Fusarium* species as the predominantly isolated pathogen among fungal positive corneal ulcer cases. This pattern of distribution could possibly be explained by differences in the climate and the natural environment.

Mixed infections both by bacteria and fungi comprised 4.2% of the total cases, which was less as compared to that reported by Srinivasan *et al*.[5] (5.1%) and more than that reported by Bharathi *et al*.[10] (2.4%).

We observed that 31 (21.8%) culture-positive cases demonstrated bacterial etiology, of which *S. aureus* was the most frequently isolated organism (51.6%), followed by *Streptococcus pneumoniae* (22.5%) and *Staphylococcus epidermidis* (19.3%). This was consistent with a similar study in Bengal.[14] However, studies in Nepal[13] and Ghana[11] found *S. pneumoniae* as the most frequently isolated bacterial pathogen. A history of contact lens wear was present in two patients in the study, out of which *Pseudomonas* species and *S. aureus* were isolated in one case each.

CONCLUSION

The results of our present study showed trauma due to wooden objects as the most common predisposing factor in causing infective keratitis.

Fungi predominated the culture-positive cases, with *Aspergillus* species being the predominant fungal agent, while *S. aureus* was the predominant bacterial pathogen. This study was carried out primarily to identify the specific pathogens responsible for corneal ulceration in eastern India and determine the demographical characteristics of the population at risk for corneal ulceration and also the different factors which can predispose to the development of an ulcer. This knowledge can be useful for defining the magnitude of problem in this part of the country and providing a base for further research work.

Financial support and sponsorship
Nil.

Conflicts of interest
There are no conflicts of interest.

REFERENCES

1. Pascolini D, Mariotti SP. Global estimates of visual impairment: 2010. Br J Ophthalmol 2012;96:614-8.
2. Austin A, Lietman T, Rose-Nussbaumer J. Update on the management of infectious keratitis. Ophthalmology 2017;124:1678-89.
3. Dandona R, Dandona L. Corneal blindness in a southern Indian population: Need for health promotion strategies. Br J Ophthalmol 2003;87:133-41.
4. Prajna VN, Prajna L, Muthiah S. Fungal keratitis: The Aravind experience. Indian J Ophthalmol 2017;65:912-9.
5. Srinivasan M, Gonzales CA, George C, Cevallos V, Mascarenhas JM, Asokan B, *et al*. Epidemiology and aetiological diagnosis of corneal ulceration in Madurai, south India. Br J Ophthalmol 1997;81:965-71.
6. Leck AK, Thomas PA, Hagan M, Kaliamurthy J, Ackuaku E, John M, *et al*. Aetiology of suppurative corneal ulcers in Ghana and South India, and epidemiology of fungal keratitis. Br J Ophthalmol 2002;86:1211-5.
7. Bourcier T, Thomas F, Borderie V, Chaumeil C, Laroche L. Bacterial keratitis: Predisposing factors, clinical and microbiological review of 300 cases. Br J Ophthalmol 2003;87:834-8.
8. Agrawal V, Biswas J, Madhavan HN, Mangat G, Reddy MK, Saini JS, *et al*. Current perspectives in infectious keratitis. Indian J Ophthalmol 1994;42:171-92.
9. Gopinathan U, Sharma S, Garg P, Rao GN. Review of epidemiological features, microbiological diagnosis and treatment outcome of microbial keratitis: experience of over a decade. Indian J Ophthalmol 2009;57:273-9.
10. Bharathi MJ, Ramakrishnan R, Vasu S, Meenakshi R, Palaniappan R. Epidemiological characteristics and laboratory diagnosis of fungal keratitis. A three-year study. Indian J Ophthalmol 2003;51:315-21.
11. Hagan M, Wright E, Newman M, Dolin P, Johnson G. Causes of suppurative keratitis in Ghana. Br J Ophthalmol 1995;79:1024-8.
12. Tewari A, Sood N, Vegad MM, Mehta DC. Epidemiological and microbiological profile of infective keratitis in Ahmedabad. Indian J Ophthalmol 2012;60:267-72.
13. Upadhyay MP, Karmacharya PC, Koirala S, Tuladhar NR, Bryan LE, Smolin G, *et al*. Epidemiologic characteristics, predisposing factors, and etiologic diagnosis of corneal ulceration in Nepal. Am J Ophthalmol 1991;111:92-9.
14. Basak SK, Basak S, Mohanta A, Bhowmick A. Epidemiological and microbiological diagnosis of suppurative keratitis in Gangetic West Bengal, Eastern India. Indian J Ophthalmol 2005;53:17-22.
15. Liesegang TJ, Forster RK. Spectrum of microbial keratitis in South Florida. Am J Ophthalmol 1980;90:38-47.

Original Article

Factors associated with poor prognosis in corneal ulcer: A clinical and epidemiological study

ABSTRACT

Aim: To explore the factors associated with culture positivity and worsening of corneal ulcers in patients presenting to a tertiary care teaching hospital in south Kerala. **Methods:** We did a retrospective review of hospital-based case records from June 2018 to May 2019 and included all cases of infective corneal ulcer admitted during the period of study with corneal stromal infiltrate on slit-lamp examination. Results of gram stain, potassium hydroxide stain, and culture result were noted. The treatment history (moxifloxacin (0. 3%) or fortified cephalosporin and gentamicin or natamycin) was recorded. The data were exported to the statistical software SPSS V27.0 for further analysis. **Results:** The data of 125 culture-positive and 250 culture-negative ulcers were studied. Most patients were aged >55 years (n = 201, 53.6%) and 35–55 years (n = 120, 32.0%). The association of culture negativity with nontraumatic risk factors was significant (P = 0.01) but not with the size of the ulcer, progress score, or worsening clinical status of the ulcer. More persons with pretreatment (15.2%) showed worsening of the clinical status compared to those who did not (6.3%) (P = 0.005). 63% of the culture-positive cases had not taken any pretreatment. Compared to noncentral ulcers there was a marked deterioration of central ulcers (16.7%) (P = 0.005). **Conclusion:** Pretreatment and centrally located ulcers were significantly associated with a worsening clinical condition in this study. Culture-positive corneal ulcers showed a tendency toward improvement, but we could not find an association between the detection of the organism and its favorable response to treatment.

Keywords: Corneal ulcer, culture, prognosis

INTRODUCTION

The incidence of microbial keratitis in South India is estimated at approximately 113/100,000 population.[1] The incidence of microbial keratitis in India is more than ten times the incidence in the US with an estimated 800,000 persons developing microbial keratitis in India each year.[2] An estimated 1.5–2 million people each year worldwide develop uniocular blindness that is attributable to microbial keratitis.[2] Increased severity of infection in microbial keratitis is associated with delays in presentation, inappropriate use of medications and the difficulty to obtain diagnostic cultures, especially in rural populations can lead to an increased magnitude of uniocular blindness and vision impairment and healthcare costs, especially in vulnerable populations.[3] In the US, microbial keratitis results in an estimated 175 million dollars in direct health expenditure while a study from south India reported that the total overall cost for accessing and receiving care was 85.8 ± 4.6 USD and the mean total cost to diagnose and appropriately treat 1 case of keratitis such that the patient had vision better than 6/18 at final follow-up was 56.2 ± 3.6 USD.[4,5]

The severity of microbial keratitis is influenced by an intermix of environmental factors like geographical location, climate, and virulence of causative organisms and patient factors like population demographic, occupation, contact lens use, and associated ocular and systemic morbidity. The Asia Cornea

Submitted: 24-Apr-2021 **Revised:** 20-Jun-2021
Accepted: 21-Jun-2021 **Published:** 21-Apr-2022

Access this article online

Website: www.kjophthal.com

DOI: 10.4103/kjo.kjo_97_21

Quick Response Code

Mini Mathew, A. R. Arya, Ajith Cherian[1]
Department of Ophthalmology, Regional Institute of Ophthalmology, [1]Department of Neurology, Sree Chitra Tirunal Institute for Medical Sciences and Technology, Thiruvananthapuram, Kerala, India

Address for correspondence: Dr. Mini Mathew, Department of Ophthalmology, Regional Institute of Ophthalmology, Thiruvananthapuram, Kerala, India.
E-mail: miniacherian@gmail.com

This is an open access journal, and articles are distributed under the terms of the Creative Commons Attribution-NonCommercial-ShareAlike 4.0 License, which allows others to remix, tweak, and build upon the work non-commercially, as long as appropriate credit is given and the new creations are licensed under the identical terms.

For reprints contact: WKHLRPMedknow_reprints@wolterskluwer.com

How to cite this article: Mathew M, Arya AR, Cherian A. Factors associated with poor prognosis in corneal ulcer: A clinical and epidemiological study. Kerala J Ophthalmol 2022;34:37-41.

Society Infectious Keratitis Study on etiological patterns of infectious keratitis, including viral disease, from 13 tertiary care hospitals throughout Asia reported a fungal predominance in India[6] compared to a predominant bacterial etiology in the more developed economies. Kerala is a south Indian state with a hot, humid climate interspersed with a good monsoon. The climatic conditions of Kerala and its agrarian nature can lead to an increased risk for microbial keratitis. We designed a retrospective case record-based study to explore the factors associated with culture positivity and worsening of corneal ulcers in patients presenting to a tertiary care teaching hospital in south Kerala.

METHODS

The study protocol that used a case-control design and a retrospective review of hospital-based case records was approved by the institutional ethics committee. The records of patients admitted to the study institute from June 2018 to May 2019 were retrieved and analyzed. The study included all cases of infective corneal ulcer that required admission during the period of study with the presence of corneal stromal infiltrate upon slit-lamp examination, and which required microbiological evaluation of corneal scrapings for suspected microbial keratitis. The study excluded viral ulcers, Mooren's ulcers, marginal ulcers, interstitial keratitis, sterile neurotrophic ulcers, ulcers associated with autoimmune conditions, and cases of noninfective corneal ulcer. The cases were defined as patients with culture positivity and controls were defined as patients with culture-negative results. The outcome variables of interest included the size and depth of infiltrate, presence of hypopyon, and visual acuity. The exposure variables studied included age, pretreatment, time lag, size, depth of ulcer, and culture positivity. A sample size of 350 was estimated using the Open Epi software, 80% power, least anticipated odds ratio, and a 1: 2 allocation for cases and controls.

The size and depth of the infiltrate, duration of treatment/ other features like hypopyon, satellite lesions, collagenolysis, etc., are not mentioned.

The data was entered into an anonymized study form that included sociodemographic details, duration of symptoms, previous treatment, predisposing ocular conditions, and associated risk and clinical features. The size of the epithelial defect and infiltrate measured with the variable slit on the biomicroscope, and the size and depth of the stromal infiltrate were recorded in millimeters. A sketch of each ulcer was drawn on the form and the presence or absence of a hypopyon, hyphate margins, presence of immune ring, satellite lesions was recorded. Associated ocular conditions such as blepharitis, dacryocystitis, dry eyes, corneal anesthesia, or ocular leprosy were noted. The results of corneal scraping including Gram stain, potassium hydroxide stain and culture result were noted. The treatment history (moxifloxacin (0. 3%) or standard therapy of fortified cephalosporin and gentamicin drops or natamycin) was recorded. Ulcers were classified according to severity and changes in the initial size, position of ulcer, and the course of the ulcer was recorded on days 3, 6, and 14 days or till discharge.

The data were entered into a spreadsheet and exported to the statistical software IBM Statistics for Windows, version 27.0, (Armonk, NY) for further analysis. Continuous variables were expressed as mean and were compared using a *t*-test. Categorical variables were expressed as proportions and were compared using a Fisher's test. A logistic regression model was used to explore associations of prognosis. Each patient was given a combined score called progress score based on the vision, size, and depth of involvement at presentation, 1 day, 6 days, 2 weeks, or at discharge. The progression pattern was assessed and the improvement of the progress score was analyzed as–1 (deterioration), 0 (stabilization), and 1, to 5 for various levels of improvement. The effect of initial size, the position of ulcer, and pretreatment on the course of the ulcer was analyzed using the Chi-square test, bivariate logistic regression test, and Fischer's test. Binary logistic regression analysis was used to predict risk factors of deterioration. Age, culture result, size of ulcer, foreign body, trauma, other risk factor, site of ulcer, and pretreatment were the variables considered in the logistic regression model.

RESULTS

The data of 125 culture-positive and 250 culture-negative ulcers were retrieved from the case records of patients admitted with corneal ulcer during the study period. Most of the subjects were aged >55 years (n = 201, 53.6%) and 35–55 years (n = 120, 32.0%). Culture negative results were significantly more common than culture-positive results in all age groups except the 35-to-55-year age group [see Table 1]. Culture negativity was significantly associated with nontraumatic risk factors (P = 0.01) but was not associated with the size of the ulcer, progress score, or worsening clinical status of the ulcer [see Table 2]. Twelve of the 15 culture-positive ulcers that showed deterioration were fungal ulcers. The common fungi involved with corneal ulcers in this population were Fusarium and aspergillus. More patients who took pretreatment (15.2%) showed worsening of the clinical status compared to those who

Table 1: Association of culture positivity with age in the study population

Age (years)	Culture negative (n=250), n (%)	Culture positive (n=125), n (%)	P
<15 (n=24)	20 (83.33)	4 (16.67)	0.001
15-34 (n=30)	22 (73.33)	8 (26.67)	0.0003
35-55 (n=120)	58 (48.33)	62 (51.67)	0.61
>55 (201)	150 (74.63)	51 (25.37)	0.001

Table 2: Associations of culture positivity in the study population

Factors	Culture negative, n (%)	Culture positive, n (%)	P
Non traumatic risk factor	50 (20)	12 (9.6)	0.01
Size of ulcer (2-6 mm)	112 (45)	62 (50)	0.05
Progress score-improvement	177 (71)	87 (70)	0.06
Stabilization	52 (21)	24 (19)	0.05
Deterioration	20 (8)	14 (11)	0.05

did not take pretreatment (6.3%) (P = 0.005). 63% of the culture-positive cases had not taken any pretreatment. There was a marked deterioration of central ulcers (16.7%) compared to ulcers (4.7%) at other locations (P = 0.005). Only 61.7% of the centrally located corneal ulcers showed improvement compared to ulcers in other locations (75.7%). A bivariate regression model was used to explore associations of age, culture positivity, size of ulcer, foreign body, trauma, other risk factors, site of ulcer, and pretreatment with deterioration of the ulcer. Pretreatment (odds ratio 2.35, 95% confidence interval [CI]: 1.11, 4.92, P = 0.02) was significantly associated with a worsening clinical condition while a noncentrally located ulcer was protective from clinical deterioration (odds ratio 0.26, 95% CI: 0.12, 0.55, P < 0.001).

DISCUSSION

The pretreatment (whether steroids are used which has a major bearing in the outcome of a corneal ulcer) details are not written.

Most subjects with corneal ulcers were aged >35 years in the study population and possibly reflect the risk factors associated with corneal ulcers like outdoor occupation and agrarian work. Nontraumatic risk factors were significantly associated with corneal ulcer in persons aged >55 years while ocular trauma was a significant risk factor in the younger ages. The association with trauma reflects in the culture positivity rates with a higher frequency of culture positivity in the younger age groups. We found that pretreatment with ophthalmic medications and centrally located ulcers were significantly associated with a worsening clinical condition in this study population. Our patients were found to have pretreament with broad-spectrum antibiotic with or without natamycin. None of our patients were recorded to have pretreatment with steroid eye drops. Culture-positive corneal ulcers showed a tendency toward improvement, but we could not find an association between the detection of the organism and its favorable response to treatment.

We found similar results in our study with more culture-positive ulcers showing a greater deterioration'.--THE CAUSE OF THIS ??

Still, it is not clear why were the fungal ulcers having a poor prognosis. Is it related to the etiological agent or is it patient related (like poor compliance/cocktail treatment/late intervention/super-added systemic illness like diabetes, etc.,)

Previous studies[7,8] have reported positive culture and ulcer size larger than 5 mm^2 as a significant predictor of slow healing in ulcer. We found similar results in our study with more culture-positive ulcers showing a greater deterioration. Twelve of the 15 culture-positive ulcers that showed deterioration were fungal ulcers. Of the 45.5%of culture positivity, 15% showed fusarium growth 9% showed aspergillus and 12% constituted other fungi namely *Penicillium*, scopularis, aerobasidium, epicorum, and rhodoturulla. Sixty-three percent of culture-positive were seen not to have taken pretreatment.

Eighty percent of culture positive had a size >2 mm. The poor prognosis of the culture-positive fungal ulcers could be related to the etiological agent and the late presentation as most of our culture-positive ulcers were large in size. Ten percent of culture positive were associated with a nontraumatic risk factor like diabetes mellitus (DM), exposure, aphakia/pseudophakia, contact lens. In this DM was seen in 9% of culture-positive cases. As our study is retrospective in nature compliance to the drugs cannot be commented on.

Stains and culture remain a gold standard to determine the course of management for corneal ulcers. Cultures are used to supplement clinical assessments but do not identify causative organisms in most cases of microbial keratitis.[9] The median culture positivity rate from clinically diagnosed cases of MK is 50.3% and stains achieve diagnosis in only 27.3%–61.6% of cases.[10-12] The relative insensitivity of these methods is attributable to prior antibiotic use, technical difficulties in

growing organisms from small samples, and difficulties in immediate incubation of culture plates to optimize diagnostic yield.[13] The relatively small quantity of infected material that can be sourced from the cornea add to the difficulty. *In vivo* confocal microscopy is a useful clinical adjunct but has several limitations including insufficient resolution for definitive diagnostic results in all cases especially cysts, hyphae and smaller bacteria (0–5 μm), dependency on the skill of the operator, and affordability, accessibility and availability.[14-16] These difficulties affect clinical management decisions as clinicians are often forced to depend on broad-spectrum, fortified antibiotics, or a late-generation fluoroquinolone in the presence of culture negative results. In addtion, the time to get a result, as well as the availability of lab services, are factors that must be considered. Polymicrobial keratitis is increasingly recognized and adds to the challenges as it can be difficult to differentiate from microbial keratitis.

The utility of scraping and culturing every corneal ulcer has been questioned earlier.[17] This is a pertinent and relevant question when we consider the fact that there is a lack of microbiology facilities at all eye hospitals or primary and secondary care centers. All the 375 patients in our study had specimens cultured but culture positivity was not a predictor of a good response to treatment and did not ensure an improvement in the ulcer. Pretreatment with over-the-counter drugs and from local clinics was a significant predictor of poor response to treatment in this study. Pretreatment often led to a culture-negative report and we recommend considering pretreatment as an important indicator for the immediate culture of the ulcer. There are several other important reasons to consider an immediate culture in eyes with pretreatment. These include the predilection to use broad-spectrum and latest antibiotics as over-the-counter medications, the use of steroids as a first-line treatment, the increasing use of contact lenses for refractive and therapeutic purposes, and the possibility of infectivity with newly recognized strains of organisms. Central ulcers who show a primary nonresponse to treatment with a history of pretreatment should be sent for early microbiological evaluation.

CONCLUSION

Time to heal may equate to the possibility of vision loss in corneal ulcers. Early identification and appropriate management are therefore essential. Corneal ulcers also have socioeconomic consequences in addition to vision loss. Time taken to heal and the visits to the hospital translate to a loss of working days and a loss in productivity for most patients with corneal ulcers, especially in the younger ages. Most patients with corneal ulcers are engaged in work in the informal sectors where a loss of a day at work will results in reduced work opportunities in the future as well. Failure in early resolution of the corneal ulcer, especially centrally located ones, can result in corneal scarring and uniocular blindness that may need keratoplasty or even evisceration and prosthetic implants. This will lead to an increase in the economic burden to the patient, a poor quality of life, and increase in the magnitude of uniocular blindness.

The retrospective nature of our study and the limited period of follow-up are limitations of our study. The case-control design does not allow us to comment on the culture positivity rates. The documentation and detailed clinical examination are strengths of the study, but the single center nature of the study does not allow us to generalize results to a larger population.

The discussion around microbial keratitis in India has predominantly limited itself to the identification of causative organisms and clinical course. Although these considerations are useful, the focus only on clinical aspects has possibly led to an underestimation of its public health impact including the contribution to uniocular blindness and vision impairment and the impact on the person and society. Most patients with corneal ulcers are in the productive age groups and a loss or reduced productivity has implications on the long-term health of the community as well. The possibility of a loss of productivity must be factored in the decisions taken by the patient to self-medicate or pretreat with over-the-counter medications. The rampant use of over-the-counter medications has a role to play in the increasing prevalence of antimicrobial resistance. The steroid in corneal ulcer trial[18] reported a 3.48-fold higher minimum inhibitory concentration for bacteria isolated from patients who had been pretreated with topical fluoroquinolones, compared to treatment-naive patients. The mycotic ulcer treatment trial I, reported a 2.14-times increase in mean minimum inhibitory concentration per year after adjusting for causative organism.[19] Low susceptibility to moxifloxacin for coagulase-negative *Staphylococcus* species (61.2%) and methicillin-sensitive *Staphylococcus* (53.1%) has been reported from India.[20]

Further studies to develop better clinical algorithms for the identification and management of corneal ulcers at different healthcare levels are essential. Antibiotic resistance, infectivity with newer organisms, and a possible increase in magnitude with increased use of contact lenses for refractive and therapeutic purposes must be studied. These studies must be complemented with studies on the impact of corneal ulcers on the quality of life and economic impact as well to improve benefits to patients.

Financial support and sponsorship

Nil.

Conflicts of interest

There are no conflicts of interest.

REFERENCES

1. Gonzales CA, Srinivasan M, Whitcher JP, Smolin G. Incidence of corneal ulceration in Madurai district, South India. Ophthalmic Epidemiol 1996;3:159-66.
2. Whitcher JP, Srinivasan M, Upadhyay MP. Corneal blindness: A global perspective. Bull World Health Organ 2001;79:214-21.
3. Burton MJ, Pithuwa J, Okello E, Afwamba I, Onyango JJ, Oates F, *et al*. Microbial keratitis in East Africa: Why are the outcomes so poor? Ophthalmic Epidemiol 2011;18:158-63.
4. Ung L, Bispo PJ, Shanbhag SS, Gilmore MS, Chodosh J. The persistent dilemma of microbial keratitis: Global burden, diagnosis, and antimicrobial resistance. Surv Ophthalmol 2019;64:255-71.
5. Prajna VN, Nirmalan PK, Saravanan S, Srinivasan M. Economic analysis of corneal ulcers in South India. Cornea 2007;26:119-22.
6. Khor WB, Prajna VN, Garg P, Mehta JS, Xie L, Liu Z, *et al.* The Asia cornea society infectious keratitis study: A prospective multicenter study of infectious keratitis in Asia. Am J Ophthalmol 2018;195:161-70.
7. Wilhelmus KR, Schlech BA. Clinical and epidemiological advantages of culturing bacterial keratitis. Cornea 2004;23:38-42.
8. Morlet N, Minassian D, Butcher J. Risk factors for treatment outcome of suspected microbial keratitis. Ofloxacin Study Group. Br J Ophthalmol 1999;83:1027-31.
9. Dahlgren MA, Lingappan A, Wilhelmus KR. The clinical diagnosis of microbial keratitis. Am J Ophthalmol 2007;143:940-4.
10. Cariello AJ, Passos RM, Yu MC, Hofling-Lima AL. Microbial keratitis at a referral center in Brazil. Int Ophthalmol 2011;31:197-204.
11. Khanal B, Deb M, Panda A, Sethi HS. Laboratory diagnosis in ulcerative keratitis. Ophthalmic Res 2005;37:123-7.
12. Leck AK, Thomas PA, Hagan M, Kaliamurthy J, Ackuaku E, John M, *et al*. Aetiology of suppurative corneal ulcers in Ghana and south India, and epidemiology of fungal keratitis. Br J Ophthalmol 2002;86:1211-5.
13. Kaye SB, Rao PG, Smith G, Scott JA, Hoyles S, Morton CE, *et al.* Simplifying collection of corneal specimens in cases of suspected bacterial keratitis. J Clin Microbiol 2003;41:3192-7.
14. Alzubaidi R, Sharif MS, Qahwaji R, Ipson S, Brahma A. *In vivo* confocal microscopic corneal images in health and disease with an emphasis on extracting features and visual signatures for corneal diseases: A review study. Br J Ophthalmol 2016;100:41-55.
15. Hau SC, Dart JK, Vesaluoma M, Parmar DN, Claerhout I, Bibi K, *et al.* Diagnostic accuracy of microbial keratitis with *in vivo* scanning laser confocal microscopy. Br J Ophthalmol 2010;94:982-7.
16. Kheirkhah A, Syed ZA, Satitpitakul V, Goyal S, Müller R, Tu EY, *et al.* Sensitivity and specificity of laser-scanning *in vivo* confocal microscopy for filamentous fungal keratitis: Role of observer experience. Am J Ophthalmol 2017;179:81-9.
17. McDonnell PJ. Empirical or culture-guided therapy for microbial keratitis? A plea for data. Arch Ophthalmol 1996;114:84-7.
18. Ray KJ, Prajna L, Srinivasan M, Geetha M, Karpagam R, Glidden D, *et al.* Fluoroquinolone treatment and susceptibility of isolates from bacterial keratitis. JAMA Ophthalmol 2013;131:310-3.
19. Prajna NV, Lalitha P, Rajaraman R, Krishnan T, Raghavan A, Srinivasan M, *et al*. Mycotic ulcer treatment trial group. Changing azole resistance: A secondary analysis of the MUTT I randomized clinical trial. JAMA Ophthalmol 2016;134:693-6.
20. Lalitha P, Manoharan G, Karpagam R, Prajna NV, Srinivasan M, Mascarenhas J, *et al.* Trends in antibiotic resistance in bacterial keratitis isolates from South India. Br J Ophthalmol 2017;101:108-13.

Original Article

A study on ocular symptomatology and clinical profile of coronavirus disease-19 positive patients admitted at a tertiary care institute in South India

ABSTRACT

Purpose: To study the ocular symptomatology and clinical profile of coronavirus disease-19 (COVID-19) positive patients admitted at a tertiary care institute. **Methods:** This cross-sectional, observational, and descriptive study was conducted on 200 reverse transcriptase-polymerase chain reaction positive confirmed COVID-19 patients in a tertiary care institute from September 2020 to October 2020. Ocular and systemic history was collected from the patients, clinical findings and investigation values were noted and analyzed. **Results:** Out of 200 COVID-19 positive patients in our study, 54% of the patients were graded as mild COVID-19 cases, 34% of the patients were graded as moderate, and 12% of the patients were graded as severe COVID-19 cases. The prevalence of ocular symptoms was 10.5%. Burning sensation of the eyes was the most common ocular symptom. A higher occurrence of ocular symptoms was observed in febrile patients and it was found to be statistically significant. The ocular symptoms worsened with a rise in temperature. **Conclusion:** Our study reveals that in COVID-19 positive patients, the most common systemic symptom was fever and the most common ocular symptom was burning sensation. In most of the cases, ocular symptoms appeared before or with the appearance of systemic symptoms. Most ocular symptoms were either mild or moderate grade. Ocular symptoms were higher in febrile patients with the severity increasing during febrile period in most patients. With this, we need to consider all patients coming to the outpatient department with complaints of burning sensation of eyes, eye pain and red eye as possible COVID-19 cases, and do due diligent workup.

Keywords: Burning sensation, coronavirus disease 19, eye pain, fever, ocular symptoms, redness in the eye

INTRODUCTION

The outbreak of the novel coronavirus disease (COVID-19) had been declared by the WHO as a global public health emergency.[1] COVID-19 was first reported in Wuhan, China in December 2019, followed by an outbreak across other parts of China, and all over the world.[2,3]

COVID-19 has a variable spectrum of symptoms.[4] As per some studies, more than 80% of COVID-19 illnesses are asymptomatic or can be symptomatic with mild symptoms, the most common and frequently reported symptoms of COVID-19 being fever, cough, and dyspnea whereas less common symptoms are myalgia, malaise, arthralgia, chest pain, nasal congestion, runny nose, headache, sore throat, and diarrhea.[4-6] COVID-19 has been described to potentially have ocular involvement.[7] However, scant information is available regarding Severe Acute Respiratory Syndrome-Coronavirus-2 (SARS-CoV-2) and ocular structures tropism.[8-10]

Patients infected with SARS-CoV-2 can present with a multitude of ocular manifestations such as conjunctivitis, red eye,

Shruthi Bidari, Roshni Robert, B. Abhilash, Mahesh Babu, M. S. Mashitha

Department of Ophthalmology, KVG Medical College and Hospital, Sullia, Karnataka, India

Address for correspondence: Dr. Mahesh Babu, Quarter No B-26, KVG Doctors' Apartment, Kurunjibhag, Sullia - 574 327, Karnataka, India.
E-mail: maheshbabu.oph@gmail.com

Submitted: 20-Apr-2021 **Revised:** 02-Jun-2021
Accepted: 07-Jul-2021 **Published:** 21-Apr-2022

Access this article online	
Website: www.kjophthal.com	Quick Response Code
DOI: 10.4103/kjo.kjo_93_21	

This is an open access journal, and articles are distributed under the terms of the Creative Commons Attribution-NonCommercial-ShareAlike 4.0 License, which allows others to remix, tweak, and build upon the work non-commercially, as long as appropriate credit is given and the new creations are licensed under the identical terms.

For reprints contact: WKHLRPMedknow_reprints@wolterskluwer.com

How to cite this article: Bidari S, Robert R, Abhilash B, Babu M, Mashitha MS. A study on ocular symptomatology and clinical profile of coronavirus disease-19 positive patients admitted at a tertiary care institute in South India. Kerala J Ophthalmol 2022;34:42-6.

ocular irritation, foreign body sensation, tearing, chemosis, blurring of vision, and posterior pole changes.[11] Ocular symptoms can also rarely present as an initial manifestation of the COVID-19, although they can present along with other systemic symptoms of COVID-19.[12-15] Following the outbreak, various studies have been conducted in India where the general clinical profiles of SARS-CoV-2 affected patients have been assessed. However, owing to the lack of sufficient data and observations in India with respect to ocular symptomatology, and its relationship with systemic symptoms, clinical findings, and investigation values, our study aims to fulfill these lacunae of previous studies.[16]

METHODS

The current study was a cross-sectional, observational, and descriptive study conducted on 200 reverse transcriptase-polymerase chain reaction (RT-PCR) positive confirmed COVID-19 patients in a teaching hospital in Dakshina Kannada, South India. The period of study was between September 2020 and October 2020. All patients were in a normal psychological and physical state and reported systemic symptoms and ocular symptoms accurately. Inclusion criteria include RT-PCR confirmed COVID-19 positive stable patients, with no history of chronic ocular diseases, admitted to our institute between the duration of September 2020 to October 2020. Patients with a history of ocular diseases or any chronic use of ocular medications in the past 1 year were excluded from this study. Patients with a history of previous ocular surgery (except cataract surgery) or ocular trauma were also excluded from this study. A semi-structured questionnaire was formulated, and pilot tested before obtaining information from the patients. There were a total of 10 questions comprising both closed-ended and semi-open questions, which were used to collect information on systemic and ocular symptoms. Sample size was calculated using the formula, $4pq/L^2$, with $p = 27.7712$, $q = 72.3$, and allowable error $d = 6.4$. The minimum sample size was calculated to be 196 which was approximated to 200.[14] Informed consent was obtained from all participants recruited into the study. The study was approved by the Institutional Ethics Committee and performed in accordance with the tenets of the declaration of Helsinki.

Patients admitted in the COVID ward were communicated by us with the assistance of two-way audiovisual devices (camera, mic, and display screen) set up at COVID ward in our institute. Demographic data of the patients were noted from the patient case sheet. Ocular and systemic history was taken from the patients as per the questionnaire in local language by using audio-visual communications devices. The clinical findings (pulse rate, respiratory rate, temperature, and oxygen saturation) and the investigation values (Laboratory parameters such as Hemoglobin, total count, differential count, erythrocyte sedimentation rate, D-dimer, serum ferritin, and C-reactive protein (CRP) levels) were noted from the patient's case sheet which were recorded by treating physician after examining the patients following COVID appropriate behavior and wearing personal protection equipment. The general clinical profile of all patients was tabulated and graded as mild, moderate, and severe COVID-19 cases as per the guidelines from the directorate general of health services, ministry of health and family welfare, Government of India[17] [Table 1]. Patients grouped under the "severe" category with acute respiratory distress syndrome, sepsis and septic shock were excluded from our study. All ocular symptoms were subjectively graded as mild, moderate, and severe on the scale of 1–10 based on the patient's response as 0-absent, 1–3-mild, 4–6-moderate, and ≥ -severe based on the visual analog scale. The data were entered in Microsoft Office Excel 2007 and the same was analyzed using the SPSS version 21 (SPSS (version 21.0, IBM Corp., Armonk, NY, USA)). The data were expressed in frequencies and percentages. Appropriate parametric (*t*-test) and nonparametric tests (Chi-square test) were employed for analysis and $P < 0.05$ was taken as the level of statistical significance in our current study.

RESULTS

In the current study, a total of 200 COVID-19 positive patients, 132 (66%) were male, and 68 (34%) were female. The age of the participating patients ranged from as young as 8 years to 77 years. Mean age of the population under study was 43.28 ± 14.28. The age distribution of COVID-19 patients in our study is depicted in Figure 1.

Among the RTPCR confirmed cases of COVID-19, 54% of the patients were graded as mild cases, 34% of the patients were graded as moderate cases, and 12% of the patients were graded as severe cases. The systemic symptoms reported

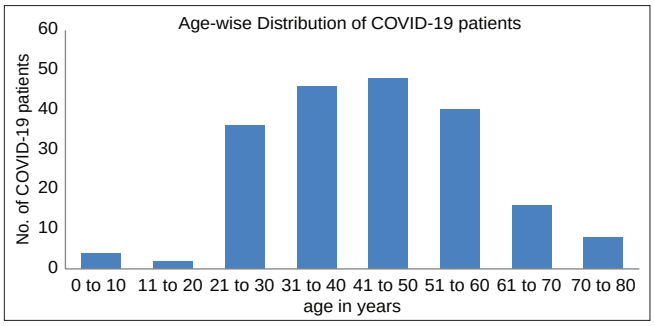

Figure 1: Demographic characteristics of the population under study

Table 1: Grading Of COVID-19 severity as per directorate general of health services, ministry of health and family welfare, Government of India

	Asymptomatic	Mild case	Moderate case	Severe case
Symptoms	No symptoms, no hypoxemia or breathlessness	Uncomplicated upper respiratory tract infection, no hypoxemia orbreathlessness	Pneumonia with no signs of severe disease	Severe pneumonia, ARDS, sepsis, septic shock
Clinical signs				
Spo_2 (percentage in room air)	≥ 94	≥94	>90-94	<90
RR (/min)	≤24	≤24	24-30	>30

ARDS – Acute respiratory distress syndrome

across mild, moderate, and severe grades were varied. Table 2 shows the frequency and severity of systemic symptoms in COVID-19 positive patients in this study.

On analysis of the study population, the prevalence of ocular symptoms was observed to be 10.5%. The distribution of ocular symptoms varied among the different age groups [Figure 2] with 28.5% of COVID-19 patients having ocular symptoms falling in the age group of 51–60 years, and no ocular symptoms having been observed in patients aging zero to 10 years.

Table 3 shows grading of individual ocular symptoms into mild, moderate, and severe, as analyzed by the visual analog scale and the frequency of occurrence of ocular symptoms. On further analysis, in 40% of the patients, the ocular symptoms appeared before the onset of systemic symptoms, while 20% of the patients developed ocular symptoms after the onset of systemic symptoms. Eighteen out of 21 patients that reported ocular symptoms were febrile. Ocular symptoms reported were higher among patients with fever compared to the afebrile patients and it was found to be statistically significant ($P = 0.0050$). A trend toward increase in the severity of ocular symptoms was noticed with 70% of the patients having reported an increase in the severity of ocular symptoms during the febrile period whereas in 30% of them, the severity remained unchanged. In mild COVID-19 patients, 14.81% had ocular symptoms, in moderate COVID-19 patients 3.1% had ocular symptoms, and in severe COVID-19 patients 8.4% had ocular symptoms.

Among the COVID-19 patients with ocular symptoms, burning sensation appeared first in most patients followed by eye pain Figure 3. There was no statistical significance in the D-Dimer values CR*P* values in relation to ocular symptoms among COVID-19 patients.

Table 2: Frequency of systemic symptoms in categories of coronavirus disease-2019 positive patients

Parameter	COVID			Total
	Mild (%)	Moderate (%)	Severe (%)	
Fever	62 (57.41)	32 (29.09)	16 (66.66)	110 (55)
Cough	26 (24.07)	16 (47.05)	16 (66.66)	74 (37)
Myalgia	30 (27.77)	22 (36.67)	6 (25)	58 (29)
Headache	34 (31.48)	20 (29.41)	0	54 (27)
Sore throat	28 (25.92)	12 (17.64)	0	40 (20)
Cold/running nose	20 (18.51)	6 (8.82)	4 (16.66)	30 (15)
Loose stools	0	16 (23.53)	4 (16.66)	20 (10)
Breathlessness	0	2 (2.94)	14 (58.33)	16 (8)
Body ache	4 (3.73)	6 (8.82)	4 (16.66)	14 (7)
Loss of taste	4 (3.73)	8 (11.76)	0	12 (6)
Anosmia	8 (7.40)	4 (5.88)	0	12 (6)
Vomiting	0	8 (11.76)	2 (8.33)	10 (5)
Nausea	4 (3.73)	4 (5.88)	0	8 (4)
Generalized weakness	4 (3.73)	4 (5.88)	0	8 (4)
Abdominal pain	0	6 (8.82)	0	6 (3)
Giddiness	2 (1.85)	4 (5.88)	0	6 (3)
Throat pain	2 (1.85)	4 (5.88)	0	6 (3)
Chest pain	0	2 (2.94)	2 (8.33)	4 (2)
Loss of appetite	0	2 (2.94)	0	2 (1)

COVID – Coronavirus disease

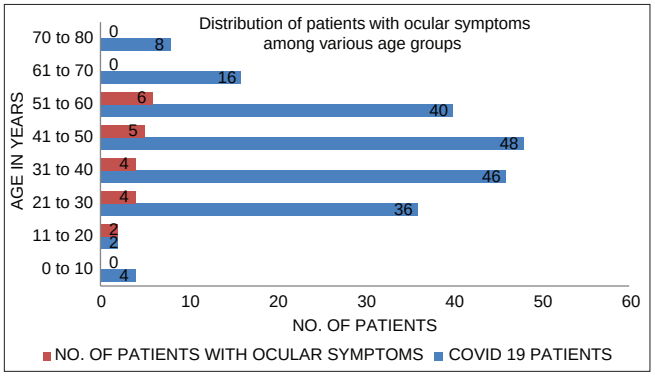

Figure 2: Distribution of patients with ocular symptoms among various age groups

DISCUSSION

Of the 200 patients in our study, 21 of them reported ocular symptoms. In a study by Wu *et al*., conducted among COVID-19 patients in China, out of a total of 38 patients, 12 had ocular manifestations consistent with symptoms

Table 3: Severity and frequency of ocular symptoms based on visual analog scale in coronavirus disease-2019 patients

	Severity of ocular symptoms based on VAS			
Variables	**Mild (%)**	**Moderate (%)**	**Severe (%)**	**Total**
Burning sensation	8 (66.67)	4 (33.33)	0	12
Redness	4 (40)	6 (60)	0	10
Eye pain	4 (50)	4 (50)	0	8
Watering eye	6 (100)	0	0	6
Foreign body sensation	4 (66.67)	2 (33.33)	0	6
Increased sensitivity to light	4 (66.67)	2 (33.33)	0	6
Swelling of eyelid	0	6 (100)	0	6
Itching sensation	0	6 (100)	0	6
Blurred vision	0	2 (100)	0	2
Secretion/ discharge	0	0	0	0

VAS – Visual analog scale

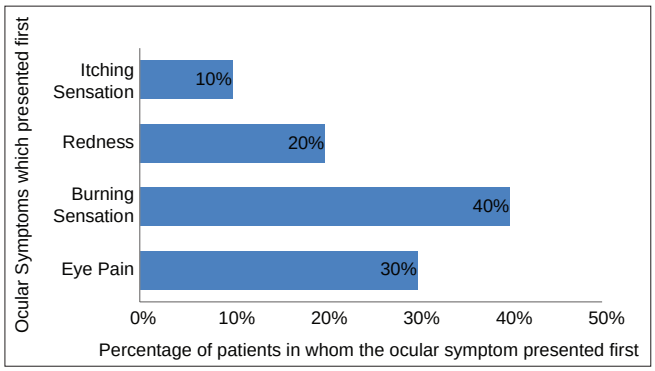

Figure 3: First ocular symptoms in COVID-19 patients

suggestive of conjunctivitis i.e., a prevalence of 31.6%.[11] A study by Sindhuja *et al*. in a hospital in North India, found 8.66% prevalence of ocular symptoms.[16] However, in our study, we observed a 10.5% prevalence of ocular symptoms among COVID-19 patients. The variable results could be due to the small sample size in the study by Wu *et al*.

In our study, the most common systemic symptom was fever (55%), followed by cough (37%), myalgia (29%), headache (27%), sore throat (19%), and cold/running nose (15%). Fever was the most common systemic symptom in the mild, moderate, and severe groups of COVID-19 patients. The observations of our study were similar to findings seen in Liwen Chen *et al*. study in which the most common clinical symptoms reported were fever, cough, and fatigue.[18] In a similar study by Wang *et al*., on 138 hospitalized patients, the most common symptoms were found to be fever, fatigue, and dry cough.[4]

In our study, we observed that the distribution of ocular symptoms varied with age, with 28.57% of COVID-19 patients with ocular symptoms falling in the age group of 51–60 years. There were no ocular symptoms reported in patients aging zero to 10 years. However, since the sample size in this age group was inadequate, comprising only four patients, further studies with a higher sample size must be conducted in age-matched study population, to arrive at a general consensus.

Patients with ocular symptoms reported mild or moderate grade symptoms and none of the patients presented with severe ocular symptoms. In our study, the most common ocular symptom reported was burning sensation of the eyes (6%) followed by redness (5%), eye pain (4%), watering (3%), foreign-body sensation (3%), increased sensitivity to light (3%), lid swelling (3%), and itching sensation (3%). No patients presented with ocular discharge. In a study by Akçay *et al*., a similar trend was observed, with burning sensation being the most commonly reported ocular symptom among COVID-19 patients.[19] The time scale of the appearance of ocular symptoms varied in relation to the systemic symptoms in different patients. In our study, we observed that, in most cases, ocular symptoms appeared before or with the appearance of systemic symptoms. Initially, burning sensation was the earliest noticed ocular symptom among most patients in our study.

The prevalence of ocular symptoms was higher in patients with fever compared to the afebrile patients and it was found to be statistically significant. Another notable observation was that among the febrile patients, the severity of ocular symptoms worsened during their febrile periods compared to the afebrile periods. However, further studies are needed to arrive at a consensus.

Strengths of the study

Our study explores the idea of the spectrum of COVID-19 symptomatology and could further aid in the case identification of unsuspected cases of SARS-CoV-2 presenting with ocular symptoms only. It also explores the relationship between ocular symptoms and systemic symptoms, and the time scale of their appearance.

Limitations of the study

Sample size is comparatively small, and it is a single-center study.

CONCLUSION

Our study reveals that in COVID-19 positive patients, the most common systemic symptom was fever and the most common ocular symptom was burning sensation. In most of the cases, ocular symptoms appeared before or with the appearance of systemic symptoms. Most ocular symptoms were either mild or moderate grade. There was a statistically significant

positive relationship between fever and the presence of ocular symptoms. Ocular symptoms were higher in febrile patients with the severity increasing during febrile period in most patients. A higher incidence of ocular symptoms in febrile patients goes to show that it may have a direct correlation with the inflammatory process at work in COVID patients, although further studies about targeted ocular microbiology and ocular inflammation in infectious diseases may yield more accurate results. We did not find any statistical significance in the D-dimer values and CR*P* values in relation to ocular symptoms among COVID-19 patients. With this, we need to consider all patients coming to the outpatient department (OPD) with complaints of burning sensation of eyes, eye pain and red eye in the current climate as possible COVID-19 cases, and do due diligent workup such as RT-PCR for confirming or refuting the diagnosis. This would be useful in the early detection of COVID-19 cases while they present to the Ophthalmology OPD with the above-mentioned ocular symptoms.

Acknowledgment

We would like to thank Dr. Dinesh Peraje Vasu for the ideas and support during the entire work.

Financial support and sponsorship

Nil.

Conflicts of interest

There are no conflicts of interest.

REFERENCES

1. World Health Organization. WHO Director-General's Opening Remarks at the Media Briefing on COVID-19; 11 March 2020. https://www.who.int/dg/speeches/detail/who-director-general-s-opening-remarks-at-the-media-briefing-on-covid-11-march-2020 [Last accessed on 2020 Sep 18].
2. Hui DS, I Azhar E, Madani TA, Ntoumi F, Kock R, Dar O, *et al*. The continuing 2019-nCoV epidemic threat of novel coronaviruses to global health – The latest 2019 novel coronavirus outbreak in Wuhan, China. Int J Infect Dis 2020;91:264-6.
3. World Health Organization. COVID-19 weekly operational update on COVID-19, 29 March 2021. https://www.who.int/publications/m/item/weekly-operational-update-on-covid-19---29-march-2021. [Last accessed on 2020 Sep 21].
4. Wang D, Hu B, Hu C, Zhu F, Liu X, Zhang J, *et al*. Clinical characteristics of 138 hospitalized patients with 2019 novel coronavirus-infected pneumonia in Wuhan, China. JAMA 2020;323:1061-9.
5. Chen N, Zhou M, Dong X, Qu J, Gong F, Han Y, *et al*. Epidemiological and clinical characteristics of 99 cases of 2019 novel coronavirus pneumonia in Wuhan, China: A descriptive study. Lancet 2020;395:507-13.
6. Huang PC, Wang Y, Li PX, Ren PL, Zhao PJ, Hu Y, *et al*. Clinical features of patients infected with 2019 novel coronavirus in Wuhan, China. Lancet 2020;395:497-506.
7. Hu K, Patel J, Swiston C, Patel BC. Ophthalmic manifestations of coronavirus (COVID-19). StatPearls [Internet]. 2021 Feb 26.
8. Lu C, Liu X, Jia Z. 2019-nCoV transmission through the ocular surface must not be ignored. Lancet 2020;395:e39.
9. Hong N, Yu W, Xia J, Shen Y, Yap M, Han W. Evaluation of ocular symptoms and tropism of SARS-CoV-2 in patients confirmed with COVID-19. Acta ophthalmologica. 2020;98:e649-55.
10. Hassani RT, Sandali O. Le nouveau Coronavirus COVID-19: Quells risques ophtalmiques? J Fr Ophtalmol 2020;43:291-3.
11. Wu P, Duan F, Luo C, Liu Q, Qu X, Liang L, *et al*. Characteristics of ocular findings of patients with coronavirus disease 2019 (COVID-19) in Hubei Province, China. JAMA Ophthalmol 2020;138:575-8.
12. Güemes-Villahoz N, Burgos-Blasco B, García-Feijoó J, Sáenz-Francés F, Arriola-Villalobos P, Martinez-de-la-Casa JM, *et al*. Conjunctivitis in COVID-19 patients: Frequency and clinical presentation. Graefes Arch Clin Exp Ophthalmol 2020;258:2501-7.
13. Xia J, Tong J, Liu M, Shen Y, Guo D. Evaluation of coronavirus in tears and conjunctival secretions of patients with SARS-CoV-2 infection. J Med Virol 2020;92:589-94.
14. Ceran BB, Ozates S. Ocular manifestations of coronavirus disease 2019. Graefes Arch Clin Exp Ophthalmol 2020;258:1959-63.
15. Invernizzi A, Pellegrini M, Messenio D, Cereda M, Olivieri P, Brambilla AM, *et al*. Impending central retinal vein occlusion in a patient with coronavirus disease 2019 (COVID-19). Ocul Immunol Inflamm 2020;28:1290-2.
16. Sindhuja K, Lomi N, Asif MI, Tandon R. Clinical profile and prevalence of conjunctivitis in mild COVID-19 patients in a tertiary care COVID-19 hospital: A retrospective cross-sectional study. Indian J Ophthalmol 2020;68:1546-50.
17. Clinical Management Protocol: COVID-19 Government of India Ministry of Health and Family Welfare Directorate General of Health Services (EMR Division) Version 4 27.06.20. https://www.mohfw.gov.in/pdf/ClinicalManagement ProtocolforCOVID19 dated27062020.pdf. [Last accessed on 2020 Sep 18].
18. Chen L, Deng C, Chen X, Zhang X, Chen B, Yu H, *et al*. Ocular manifestations and clinical characteristics of 535 cases of COVID-19 in Wuhan, China: A cross-sectional study. Acta Ophthalmol 2020;98:e951-9.
19. Akçay Bİ, Kardeş E, Kıray G, Ayaz B, Karakuş Hacıoğlu G, *et al*. Evaluation of ocular symptoms in COVID-19 subjects in inpatient and outpatient settings. Int Ophthalmol 2021;41:1541-8.

Original Article

Spectrum of herpetic eye disease during COVID-19 pandemic

ABSTRACT

Purpose: To analyze clinical presentation, outcome and upsurge in the acute presentation of Herpetic eye disease (Herpes simplex keratits and Herpes Zoster Ophthalmicus) cases during coronavirus disease 2019(COVID-19) pandemic. **Materials and Methods:** Retrospective analysis of case records of patients diagnosed with either acute HSV or HZO from April 2020 to March 2021 for demography, ocular manifestations, and management and clinical outcome was done. **Results:** We had 71 patients presenting to our hospital with herpetic eye disease with 50.70% being HZO. The majority (64.78%) of the patients were <50 years of age. The mean time to presentation from the onset of symptoms was earlier in HZO compared to HSV. Three patients were post-COVID-19 infection while six patients were post-COVID-19 vaccination. Stromal keratitis (48.5%) was the most common presentation in patients with HSV while keratitis and uveitis (31.57% each) were the most common presentation in HZO. 83.08% resolved without any visual sequelae. We also observed atypical presentation in the form of multidermatomal involvement and recurrence of keratitis in HZO patients. We observed an alarming two-fold increase in the number of cases that presented this year (2020–21) as compared to the same time (n = 33) in the past year (2019–20). **Conclusion:** This study highlights an increase in viral eye disease presenting atypically and higher incidence in young individuals during the COVID pandemic. Viral disease of the eye during the pandemic may be related to the altered immunity in coexisting asymptomatic COVID-19-infected patients and similar in postvaccinated individuals or the stress-induced immune alteration by the pandemic itself in healthy individuals. However, though this study suggests direct causal relation of either of the above as possibility and needs to be kept in mind in clinical practice, for definite association, we need further exploration and more data.

Keywords: COVID-19 pandemic, HSV, herpes zoster ophthalmicus, post-COVID vaccination

INTRODUCTION

Herpes simplex virus (HSV) and herpes zoster virus are DNA viruses belonging to the Herpes virus family. The virus remains dormant in the nervous tissue following primary infection. Failure of the immune system to contain the virus causes reactivation which is known to be triggered by immunosuppression, trauma, stress, radiation, certain mediation, and viral infections.[1,2] Both these viruses are known to result in potential chronic ocular morbidity with substantial visual loss.

Herein, this study was aimed to analyze cases of new-onset Herpes simplex keratitis and Herpes zoster ophthalmicus (HZO) occurring in patients during the COVID-19 pandemic (April 2020–March 2021).

MATERIALS AND METHODS

Retrospective data of patients presenting to us in the outpatient department with acute HSV and HZO during the

Shruti Bhat, Pallavi Joshi[1], Anand Balasubramaniam, Yash Gala

Department of Cornea and Refractive Services, Sankara Eye Hospital, [1]Department of Cornea, Ocular Surface and Refractive Services, Sankara Eye Hospital, Bengaluru, Karnataka, India

Address for correspondence: Dr. Pallavi Joshi, Department of Cornea, Ocular Surface and Refractive Services, Sankara Eye Hospital, Bengaluru, Karnataka, India.
E-mail: drpallavijoshi@gmail.com

Submitted: 22-Oct-2021
Accepted: 01-Dec-2021 **Published:** 21-Apr-2022

Access this article online	
Website: www.kjophthal.com	Quick Response Code
DOI: 10.4103/kjo.kjo_204_21	

This is an open access journal, and articles are distributed under the terms of the Creative Commons Attribution-NonCommercial-ShareAlike 4.0 License, which allows others to remix, tweak, and build upon the work non-commercially, as long as appropriate credit is given and the new creations are licensed under the identical terms.

For reprints contact: WKHLRPMedknow_reprints@wolterskluwer.com

How to cite this article: Bhat S, Joshi P, Balasubramaniam A, Gala Y. Spectrum of herpetic eye disease during COVID-19 pandemic. Kerala J Ophthalmol 2022;34:47-50.

COVID-19 pandemic (April 2020–March 2021) was reviewed and analyzed.

To have a comparative data to assess the role of the COVID pandemic for the upsurge, the present results were compared to that of the previous year during the same period (2019–2020).

RESULTS

The study included a total of 71 patients with herpetic eye disease, of which 36 patients had HZO.

The demographic details are shown in Table 1. Of 71 patients, 45 were male and 26 were female. The age of the patients ranged from 12– 96 years with the majority (64.78%) being < 50 years of age. Five (7%) were pediatric cases. One patient was immune compromised. Only eight patients had comorbidities in the form of diabetes and hypertension. The presentation time to hospital from onset of symptoms ranged from 2–90 days with a more acute presentation of patients with HZO (mean time-5.07 days) compared to those with HSV (mean time-25.65 days).

The ocular involvement is as shown in Table 2. Stromal keratitis (48.5%) followed by epithelial disease (31.4%) were the most common presentation in patients with HSV [Figure 1]. Two patients had viral keratitis in the grafted eye (post-COVID vaccination). While, in patients with HZO, 52.8% had ocular involvement in whom keratitis and uveitis (6 patients each) were the most common presentation [Figure 2a]. In addition, atypical features in the presentation of HZO such as multidermatomal involvement [Figure 2b], recurrence of keratitis (n = 1), and also patients who had corneal involvement (n = 10), 70% did not have tip of the nose involved, thus deviating from the Hutchinson sign were also observed.

There was marginally higher percentage of patients with involvement of the left eye (55.22%) compared to the right eye. Twelve patients developed significant visual morbidity due to extensive corneal scarring. However, the majority of the patients (83.08%) resolved without any visual sequelae.

The data analyzed showed that every patient was asked history for recent exposure, contact, or symptoms suggestive of COVID, but laboratory investigations for COVID-19 were not advised in these patients.

However, three patients were diagnosed with COVID-19 and presented to us postrecovery while three patients had been exposed to COVID-affected relatives in the previous 2 weeks before presentation. In addition to the above, we also had six patients developing herpetic eye disease within 2 weeks of COVID vaccination.

Surgical intervention was required in four cases of HSV presenting with perforation. Three patients underwent glue with bandage contact lens (BCL) while one patient underwent corneal patch graft. One patient managed with glue and BCL ultimately underwent keratoplasty after adequate control of the disease. One HZO case with neurotrophic ulcer underwent amniotic membrane transplantation with tarsorrhaphy.

Table 1: Demographic details of the patients

Parameters	Number
Distribution of viral keratitis	
Herpes simplex	35
Herpes zoster	36
Male	45
Female	26
Age (years)	
Range	
<30	16
30-50	30
50-70	19
>70	6
Mean age (years)	44.65
Comorbidities	
DM	5
HTN	3
HIV	1
History of COVID-19	3
Primary contacts of COVID-19 patients	3
History of COVID-19 vaccination	6

DM - Diabetes mellitus, HTN - Hypertension

Table 2: Distribution of ocular involvement

Ocular manifestation	Number
Herpes zoster	
Keratitis	6
Neurotrophic ulcer	4
Dendritic ulcer	2
Uveitis	6
Mixed (>1 structure involved)	7
Keratouveitis	4
Uveitis with episcleritis	2
Cranial nerve palsy with uveitis	1
No anterior or posterior segment involvement	17
Herpes simplex	
Keratitis	31
Epithelial	11
Stromal	17
Endotheliitis	3
Keratouveitis	4

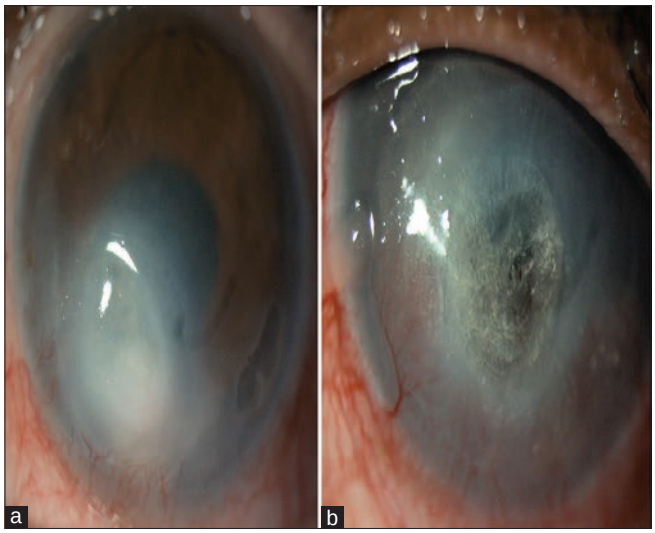

Figure 1: Slit-lamp examination in a patient with necrotizing HSV stromal keratitis (a) and slit-lamp examination in a patient with corneal perforation secondary to Herpes Simplex Virus keratitis post-COVID-19 infection (b)

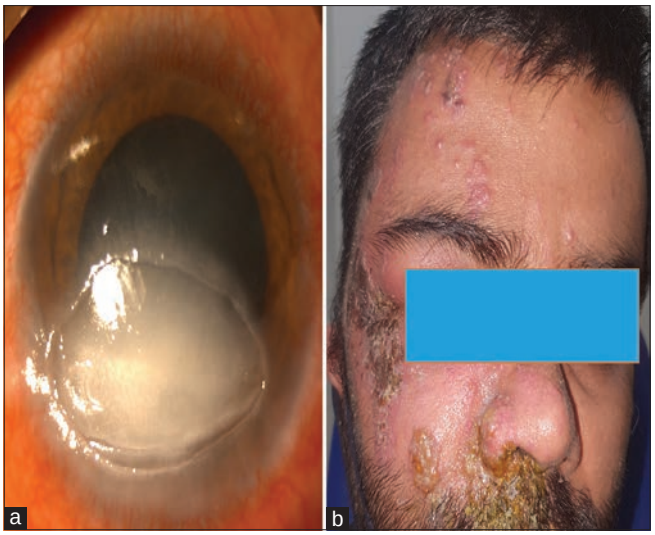

Figure 2: Slit-lamp examination in a patient with neurotrophic ulcer secondary to Herpes zoster ophthalmicus (a) and patient with acute vesicular eruption and mutidermatomal involvement in Herpes zoster ophthalmicus (b)

Our study showed nearly two-fold increase in the number of cases that presented in (2020–21) as compared to the same time ($n = 33$) in the past year (2019–20).

DISCUSSION

COVID caused by severe acute respiratory syndrome coronavirus 2 has led to a global epidemic. The rapid progression of the COVID-19 pandemic has created tremendous challenges for health-care professionals worldwide.

COVID-19 is known to present with varied manifestations, and the eye is not an exception. COVID-19 as well as its therapy has been reported to have both direct and indirect effects on the eye.[3]

Knowledge about this disease is still evolving. Several studies reported that COVID-19 infection is associated mostly with reduction in the population of lymphocytes, monocytes, and eosinophils,[4-7] especially with drastically low levels of CD4 + T cells, CD8 + T cells, B cells, and natural killer cells.[8] These cells are essential for an effective antiviral response. The immune system in COVID-19 patients demonstrates immunosuppression which is more severe in critically ill patients.[9] Our study showed two such patients who suffered from severe COVID-19 infection and developed HSV infection during the same period which reflects the same.

Studies have also reported lower percentages of T-cell functional markers in COVID-19 patients with decreased percentages of CD107a, interferon gamma (IFN-γ) +, interleukin-2, granzyme B +, and IFN-alpha when compared to normal controls correlating with functional exhaustion of cytotoxic lymphocytes.[10] The combination of these mechanisms leads to an impaired antiviral response in the host.[11] This could result in failure to maintain the latency of the virus and reactivation of the disease.

In addition to the above, many psychological problems such as stress, anxiety, depression, frustration, and uncertainty during COVID-19 outbreak have emerged progressively.[12] The physical and emotional stress during the pandemic could also be a possible triggering factor for reactivation of the virus.

Furthermore, with the recent introduction of vaccination, this study highlights a few cases of postvaccination viral keratitis. Chau *et al*. have observed the immunogenicity of COVID-19 vaccines could potentially induce or trigger autoimmune diseases.[13] There could be probable alteration of immune response in post-COVID vaccinated individuals which could potentiate reactivation of disease. However, it might be too early to comment a causal relation or to draw a conclusion as the data are limited.

Majtanova *et al*. have described five cases of Herpes simplex keratitis in COVID-19 patients.[14] Elsaie *et al*. highlighted that dermatological herpes zoster infection may be an alarming sign of a subclinical COVID-19, even in patients with mild or no respiratory symptoms during the pandemic.[15] There have very few isolated case reports on COVID-19 and HZO.

The limitations of this study are its retrospective nature and limited sample size. Furthermore, the availability of fewer centers during lockdown is a factor which cannot be

overlooked. However, our study observed apart from the increased number of cases during the COVID-19 pandemic, the presentation can be atypical and unusual which needs to be borne in mind. In addition, this study showed quite a higher percentage of young individuals presenting with the disease. Our observation would recommend further studies before drawing any definitive association.

CONCLUSION

Herpetic eye disease though not an uncommon condition encountered in clinical practice, the upsurge of viral keratitis in the current pandemic probably requires exclusion of concomitant or recent subclinical COVID-19 even in mild/asymptomatic cases. Furthermore, corneal transplant patients must be educated and made aware of the risk of viral infections in the grafted eye. With the arrival of subsequent waves and with the vaccination drive on, we may expect a greater number of cases of HSV and HZO in the coming time even in young and immunocompetent individuals. However, definitive association cannot be confirmed.

Financial support and sponsorship
Nil.

Conflicts of interest
There are no conflicts of interest.

REFERENCES

1. Rolinski J, Hus I. Immunological aspects of acute and recurrent herpes simplex keratitis. J Immunol Res 2014;2014:513560.
2. Wung PK, Holbrook JT, Hoffman GS, Tibbs AK, Specks U, Min YI, *et al*. Herpes zoster in immunocompromised patients: Incidence, timing, and risk factors. Am J Med 2005;118:1416.
3. Bertoli F, Veritti D, Danese C, Samassa F, Sarao V, Rassu N, *et al*. Ocular findings in COVID-19 patients: A review of direct manifestations and indirect effects on the eye. J Ophthalmol 2020;2020:4827304.
4. Henry BM, de Oliveira MH, Benoit S, Plebani M, Lippi G. Hematologic, biochemical and immune biomarker abnormalities associated with severe illness and mortality in coronavirus disease 2019 (COVID-19): A meta-analysis. Clin Chem Lab Med 2020;58:1021-8.
5. Ruan Q, Yang K, Wang W, Jiang L, Song J. Clinical predictors of mortality due to COVID-19 based on an analysis of data of 150 patients from Wuhan, China. Intensive Care Med 2020;46:846-8.
6. Kumar A, Arora A, Sharma P, Anikhindi SA, Bansal N, Singla V, *et al*. Clinical features of COVID-19 and factors associated with severe clinical course: A systematic review and meta-analysis. SSRN 2020:3566166.
7. Cai Q, Huang D, Ou P, Yu H, Zhu Z, Xia Z, *et al*. COVID-19 in a designated infectious diseases hospital outside Hubei Province, China. Allergy 2020;75:1742-52.
8. Cao X. COVID-19: Immunopathology and its implications for therapy. Nat Rev Immunol 2020;20:269-70.
9. Chowdhury MA, Hossain N, Kashem MA, Shahid MA, Alam A. Immune response in COVID-19: A review. J Infect Public Health 2020;13:1619-29.
10. Zheng M, Gao Y, Wang G, Song G, Liu S, Sun D, *et al*. Functional exhaustion of antiviral lymphocytes in COVID-19 patients. Cell Mol Immunol 2020;17:533-5.
11. Zheng HY, Zhang M, Yang CX, Zhang N, Wang XC, Yang XP, *et al*. Elevated exhaustion levels and reduced functional diversity of T cells in peripheral blood may predict severe progression in COVID-19 patients. Cell Mol Immunol 2020;17:541-3.
12. Duan L, Zhu G. Psychological interventions for people affected by the COVID-19 epidemic. Lancet Psychiatry 2020;7:300-2.
13. Chau CY, Chow LL, Sridhar S, Shih KC. Ophthalmological considerations for COVID-19 vaccination in patients with inflammatory eye diseases and autoimmune disorders. Ophthalmol Ther 2021;10:201-9.
14. Majtanova N, Kriskova P, Keri P, Fellner Z, Majtan J, Kolar P. Herpes simplex keratitis in patients with SARS-CoV-2 infection: A series of five cases. Medicina (Kaunas) 2021;57:412.
15. Elsaie ML, Youssef EA, Nada HA. Herpes zoster might be an indicator for latent COVID 19 infection. Dermatol Ther 2020;33:e13666.

Case Series

Neuro-ophthalmic manifestations of central nervous system tuberculosis: Compilation of three diverse unique presentations

ABSTRACT

Tubercular meningitis is the most devastating form of tuberculosis. Neuro-ophthalmic involvement can manifest as cranial nerve palsies, pupil abnormalities, disc changes, like papillitis, papilloedema, or optic atrophy and choroidal tubercles. The rate and extent of recovery are strongly. Related to early diagnosis and treatment. Herein, we describe a constellation of three cases of central nervous system tuberculosis with aberrant regeneration of oculomotor nerve, optochiasmatic arachnoiditis presenting as bilateral primary optic atrophy and the last case of parietal lobe tuberculoma presenting as homonymous hemianopia, each one with its own characteristic ocular findings.

Keywords: Central nervous system tuberculosis, neuro-ophthalmic manifestations, rare

INTRODUCTION

Tuberculosis is one of the commonest ailments in India and the neuro ophthalmic manifestations are quite devastating leading to permanent loss of vision in young adults. The various presentations are nerve palsies, optic atrophy, papillitis etc.

CASE REPORTS

The first case is of a 15 years old female fever, headache, vomiting, tinnitus, seizures for the past 3 months with history of gradual painless decrease in vision with sudden onset binocular horizontal diplopia. The best corrected visuals acuity was counting fingers at 1 m in right eye and counting finger at one and half meter in the left eye. Pupillary evaluation showed sluggishly reacting pupils in both eyes with relative afferent pupillary defect (RAPD) in the right eye. There was −1 limitation of abduction in both eyes. On alternate cover test there was alternating esotropia which measured 30 prism diopters for distance and 16 prism diopters for near. Dilated fundus examination showed temporal pallor in both eyes [Figure 1]. Cerebrospinal fluid examination showed lymphocytosis with elevated proteins. Magnetic resonance imaging (MRI) revealed shaggy meningeal enhancement in right frontotemporal region, right perisylvian cistern, and right half of surpasellar cistern [Figure 2] suggestive of optochiasmatic arachnoiditis accounting for asymmetric decreased vision and RAPD in the right eye. The patient was started on anti-tubercular therapy and steroids. At 2 months' follow-up, the visual acuity remained same but with resolution of diplopia. Optochiasmatic arachnoiditis remains one of the potential causes of primary optic atrophy with permanent loss of vision in tubercular meningitis (TBM).

The second case is of a 15-year-old girl presented to ophthalmology outpatient department with a history of

Harsha Sammer Pagad, Rishwa Hariyani[1], Akash Jain[1], Nita Shanbhag[2]

Assistant Professor, Department of Ophthalmology, Dr. D. Y. Patil Medical College, Nerul, [1]Resident Ophthalmology, [2]Department of Ophthalmology, Dr. D Y Patil Medical College, Navi Mumbai, Maharashtra, India

Address for correspondence: Dr. Harsha Sammer Pagad, Dr. D. Y. Patil Medical College and Hospital and Research Centre, Sector 5, Nerul, Navi Mumbai - 400 706, Maharashtra, India.
E-mail: harushsam@yahoo.co.in

Submitted: 18-Dec-2020 **Accepted:** 04-Jan-2021 **Published:** 21-Apr-2022

Access this article online	
Website: www.kjophthal.com	Quick Response Code
DOI: 10.4103/kjo.kjo_205_20	

This is an open access journal, and articles are distributed under the terms of the Creative Commons Attribution-NonCommercial-ShareAlike 4.0 License, which allows others to remix, tweak, and build upon the work non-commercially, as long as appropriate credit is given and the new creations are licensed under the identical terms.

For reprints contact: WKHLRPMedknow_reprints@wolterskluwer.com

How to cite this article: Pagad HS, Hariyani R, Jain A, Shanbhag N. Neuro-ophthalmic manifestations of central nervous system tuberculosis: Compilation of three diverse unique presentations. Kerala J Ophthalmol 2022;34:51-4.

the left eye remaining open when looking down since the past 8 months. She also complained of binocular horizontal diplopia in up and down gaze. She was diagnosed with TBM (for her symptoms of fever, headache, vomiting, backache, lower limb paresthesia with a history of inability to walk, seizures) with cerebellar involvement with left eye pupil involving complete third nerve palsy 8 months ago. She was receiving anti-tubercular therapy (Category 2) for a year. Contrast enhanced computed tomography scan at that time showed Few disc and ring T2 hypo-intense enhancing lesions with surrounding vasculogenic edema in the right parietal post central cortex, bilateral cerebellar hemisphere, and inferior vermis with subtle blooming on Gradient echo sequences (GRE) seen in inferior vermis lesion possibly calcification suggestive of infective etiology and an acute nonhemorrhagic infarct most likely vasculitis in pontine region [Figure 3].

On examination, her unaided visual acuity recorded 20/20, N6 in both eyes. Ocular motility examination was normal in right eye. Color vision testing with Ishihara chart was normal in both eyes. Extraocular motility evaluation revealed −3 limitation of elevation and −2 limitation of depression in left eye. Signs of aberrant regeneration such as Pseudo von Graefe's Signs, Pseudo Duane's Sign were present. Pupil in the left eye was mid-dilated sluggish reaction to light. Pupillary constriction was noted and measured with a pupil scale when eye adducted and converged, i.e., pseudo Argyll Robertson sign present[Figure 4]. Fundus examination was unremarkable in both eyes.

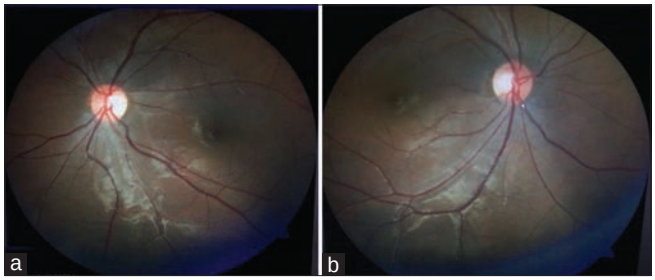

Figure 1: Colour Fundus photograph showing bilateral primary optic atrophy (a) left eye (b) right eye

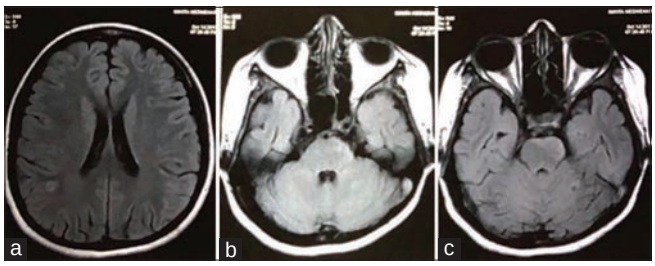

Figure 3: (a,b) CECT scan showing few disc and ring T2 hypo intense lesions in right parietal cortex and calcification in bilateral cerebellar hemisphere, (c) Acute non haemorrhagic infarct in pons

We report third case of homonymous hemianopia due to presumptive cerebral tubercular granulomas in a young adult as one of the neuro-ophthalmic presentation of central nervous system (CNS) tuberculosis.

A 19-year-old female presented with acute onset headache, binocular diplopia, blurry vision. Her best-corrected visual acuity was 6/12 p in both eyes with sluggishly reacting pupils in both eyes. Color vision recorded with Ishihara's pseudoisochromatic chart was 11/16 in right eye and 7/16 in left eye. There was-1/2 limitation of abduction in both eyes. She had alternating esotropia on alternate cover test which measured 25 prism diopter for distance and near 14 prism diopter suggestive of bilateral sixth nerve paresis. Automated perimetry detected incongruous left homonymous hemianopia [Figure 5]. On dilated fundus examination, the patient had grade 2 papilledema [Figure 6].

A MRI study was ordered in view of above findings. MRI of brain/orbit showed The presence of right parieto-occipital tuberculomas [Figure 7]. She was mantoux positive the patient was started on AKT along with steroids and mannitol at 2 months' follow, the patient had resolution of papilledema and sixth nerve paresis with recovery of vision.

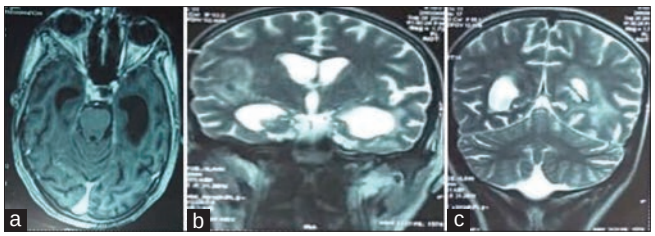

Figure 2: Magnetic resonance imaging: (a) Enhancement in right frontotemporal region, (b) right perisylvian cistern, and (c) right half of suprasellar cistern



Figure 4: Signs of aberrant regeneration

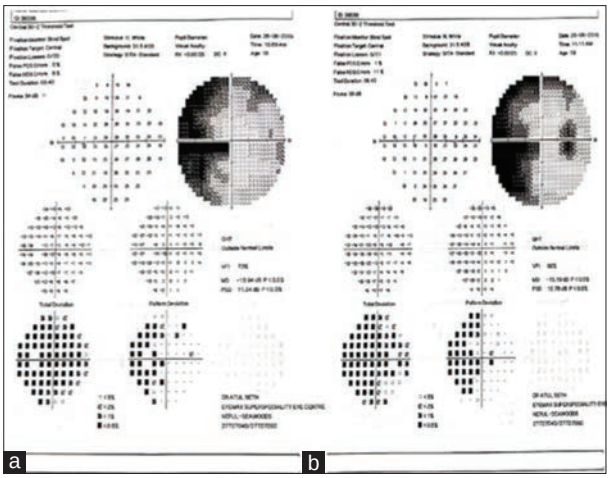

Figure 5: Left-sided homonymous hemianopia, 30-2 field of (a) left eye (b) right eye

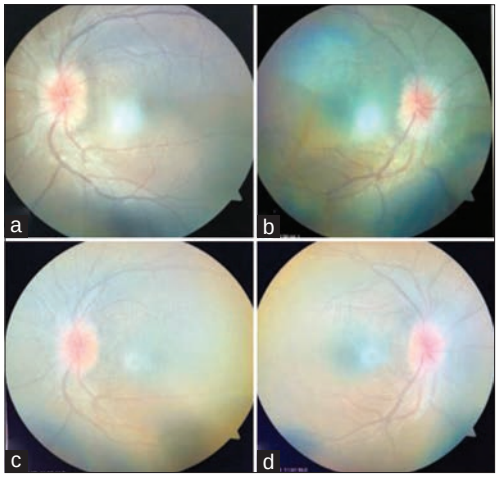

Figure 6: Papilledema at presentation (a) left eye, (b) right eye and resolution at 2 months follow-up, (c) left eye, (d) right eye

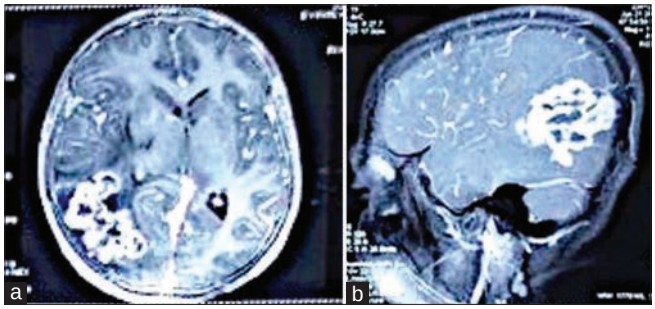

Figure 7: MRI Brain: Right parieto-occipital granulomas, (a) coronal, (b) transverse

DISCUSSION

TB is still a very common ailment in India. The most serious form of tuberculosis is TBM.[1] Tuberculomas account for 5%–30% of intracranial space occupying lesions often affecting children and young adults and TBM can have different ocular involvement in the form of choroidal tubercles, papillitis, optic atrophy, and nerve palsies.[2] There have been multiple publications quoting the incident of various ocular complications in TBM. Verma *et al*.[3] observed that 76% of children with TBM had ocular findings with third and sixth cranial nerves being frequently involved. In another study by Lamba *et al*.[4] of 48 children with TBM, optic disc changes (papillitis) constituted 62%, pupillary involvement was in 48% of patients and cranial nerves (3rd) involvement was found in 28% of patients. Anupriya *et al*.[5] observed that optochiasmatic arachnoiditis can occur as a complication of TBM.

Vision impairment is one of the most devastating sequelae associated with CNS TB causing significant morbidity. Vision impairment may result from optochiasmati arachnoiditis, compression of optic nerve by tuberculoma, optic nerve granuloma, optic neuritis associated with anti-tubercular therapy, vasculitic infarcts, or occlusion of arteries supplying the optic nerve by basal exudates.

TBM affects mainly the basal parts of the brain. Exudates present in the interpeduncular, suprasellar and Sylvian cisterns, result in optochiasmatic arachnoiditis and tuberculoma. Optochiasmatic arachnoiditis and tuberculoma are associated with profound vision loss.[6] They are the devastating forms of TBM affecting young adults. There can be enhancing lesions on MRI in the interpeduncular fossa, pontine cistern, and the perimesencephalic and suprasellar cisterns. The management of tuberculous optochiasmatic arachnoiditis and optochiasmatic arachnoiditis tuberculoma has been challenge with usually unsatisfactory outcomes. Corticosteroids such as dexamethasone, methyl prednisolone, thalidomide, and hyaluronidase have been used with variable success. Neurosurgery may be needed in unresponsive cases.[7] Our patient also did not have any improvement in vision despite appropriate treatment.

The second case is of aberrant regeneration of third nerve noted in a case of tubercular meningits with vasculitic infarct in pons. Aberrant regeneration is a very common phenomenon observed with diseases of the third nerve. According to Seddon's classification,[6] aberrancy does not occur in first- and second-degree nerve injuries. It is more common in third degree or neurotmesis where the endoneurium is disrupted. Microvascular ischemic damage to the oculomotor nerve due to small vessel disease as in diabetes rarely is responsible for synkinesis, but there are few case reports following the same.[8] Walsh has reported cases of aberrant regeneration following ischemic insult.[8]

Atypical ophthalmic manifestations may be the initial presenting feature in patients with CNS tuberculosis. This case highlights the need for increased index of suspicion for intracranial tuberculosis in young patients with atypical ophthalmic manifestations in a country like India with wide prevalence of tuberculosis. The perimetry findings correlated with the location of granulomas affection the right optic radiation whereas in cases of papilledema, we expect an enlarged blind spot.

A similar case of homonymous hemianopia as an isolated presentation of tubercular abscess has been reported by Gharai *et al.*,[9] in a patient with HIV infection.

This case emphasizes the importance of neuroimaging in cases of unusual visual field defects like hemianopia in patients with papilledema to reach an etiological diagnosis like CNS tuberculosis which can be potentially blinding and lethal if left untreated.

CONCLUSION

TBM can cause irreversible loss of vision and cause a panorama of ocular motor abnormalities. Early timely intervention by a multidisciplinary team of neurologist, ophthalmologist can save eye/vision and life.

Declaration of patient consent

The authors certify that they have obtained all appropriate patient consent forms. In the form the patient (s) has/have given his/her/their consent for his/her/their images and other clinical information to be reported in the journal. The patients understand that their names and initial s will not be published and due efforts will be made to conceal their identity, but anonymity cannot be guaranteed.

Financial support and sponsorship

Nil.

Conflicts of interest

There are no conflicts of interest.

REFERENCES

1. Das U, Gupta VK, Yadav P, Mediratta V, Rewash BB. Tuberculous meningitits with blindness. JAIME 2010;11:61-2.
2. Desai HG, Anklesaria ED. Ophthalmological aspects of tuberculous meningitis. J Indian Med Assoc 1967;49:429-32.
3. Verma BM, Srivastav SK, Srivastav JR. Ocular manifestation of tubercular meningitis and their prognostic value in children verma BMD. IJO 1981;29:301-2.
4. Lamba PA, Bhalla JS, Mullick DN. Ocular manifestations of tubercular meningitis – A clinico-biochemical study. J Pediatr Ophthalmol Strabismus 1986;23:123-5.
5. Anupriya A, Sunidhi M, Maya T, Goel M, Alexander M. Tuberculous optochiasmatic arachnoiditis. Neurol India 2010; 58:732-5.
6. Seddon HJ. A classification of nerve injuries. Br Med J 1942:237-9.
7. Garg RK, Paliwal V, Malhotra HS. Tuberculous optochiasmatic arachnoiditis: A devastating form of tuberculousmeningitis. Expert Rev Anti Infect Ther 2011;9:719-29.
8. Weber E, Newman A. Aberrant regeneration of the oculomotor nerve: Implications for neurosurgeons. Neurosurg Focus 2007;23:E14.
9. Gharai S, Venkatesh P, Sinha A, Garg S. Isolated homonymous hemianopsia due to presumptive cerebral tubercular abscess as initial manifestation of human immunodeficiency virus. Indian J Ophthalmol 2012;60:321-4.

Case Series

Ethambutol-induced optic neuropathy: A case series

ABSTRACT

In this observational case series, we describe the clinical features and investigations of three patients with ethambutol-induced optic neuropathy (EION). All three patients had a significant visual loss within 3 months to 1 year of starting antitubercular treatment. Visual field examination revealed bitemporal hemianopia in one patient and central scotomas in another. Optical coherence tomography showed significant global thinning of the ganglion cell layer and thinning of the temporal quadrants of the retinal nerve fiber layer. Visual evoked potential revealed prolonged P1 or P2 latency and reduced amplitude in all three patients. Ethambutol was stopped in all three patients. The visual acuity continued to deteriorate even after stopping the drug but showed gradual improvement over a period of one and a half years. However, the visual recovery was not full in all three patients. Considering the severity and partially irreversible nature of the loss of vision caused by EION, it is imperative to detect it at an early and subclinical stage.

Keywords: Antitubercular treatment, bitemporal hemianopia, ethambutol induced optic neuropathy, ganglion cell layer, humphrey field analyzer, optical coherence tomography, retinal nerve fiber layer, visual evoked potential

INTRODUCTION

Tuberculosis caused by Mycobacterium Tuberculosis is one of the major systemic infections in the world.[1] In India, diagnosis and treatment of tuberculosis is based on Revised National Tuberculosis Control Programme (RNTCP) guidelines.[2] According to the updated RNTCP guidelines, all new cases of tuberculosis are treated with an intensive phase, consisting of 2 months of Rifampicin, Isoniazid, Ethambutol and Pyrazinamide on daily dosages as per four weight band categories, followed by a continuation phase in which Pyrazinamide is stopped and Rifampicin, Isoniazid and Ethambutol are continued for 4 months.[3,4]

Ethambutol was introduced in 1961 as a bacteriostatic agent for Mycobacterium Tuberculosis. In 1962, Carr and Henkind first reported Ethambutol-induced optic neuropathy (EION). The exact mechanism of ocular toxicity remains to be established. It might result from decreased levels of copper in the mitochondria or from the accumulation of zinc in the lysosomes of the retinal ganglion cells.[5] EION is related to dose and duration. The standard daily dose of Ethambutol is 15 mg/kg of body weight given as a single dose. Higher dose, prolonged duration, diabetes mellitus, hypertension, older age, tobacco smoking, alcohol consumption, and poor renal function are risk factors for EION.[6] Toxic optic neuritis may be of early or late-onset, reversible or irreversible and axial or periaxial. Ethambutol can cause visual impairment as a result of retrobulbar neuritis which is related to the dose and duration of treatment.

In this case series, we discuss three patients who presented with EION with a similar spectrum of clinical features.

Anna Elias, R. Neena, A. Giridhar

Department of Ophthalmology, Giridhar Eye Institute, Kochi, Kerala, India

Address for correspondence: Dr. Anna Elias, Department of Ophthalmology, Giridhar Eye Institute, Kadavanthra, Kochi, Kerala, India.
E-mail: annatelias@gmail.com

Submitted: 16-May-2021 **Accepted:** 09-Jun-2021 **Published:** 21-Apr-2022

Access this article online	
Website: www.kjophthal.com	Quick Response Code
DOI: 10.4103/kjo.kjo_114_21	

This is an open access journal, and articles are distributed under the terms of the Creative Commons Attribution-NonCommercial-ShareAlike 4.0 License, which allows others to remix, tweak, and build upon the work non-commercially, as long as appropriate credit is given and the new creations are licensed under the identical terms.

For reprints contact: WKHLRPMedknow_reprints@wolterskluwer.com

How to cite this article: Elias A, Neena R, Giridhar A. Ethambutol-induced optic neuropathy: A case series. Kerala J Ophthalmol 2022;34:55-61.

CASE REPORTS

Case 1

A 45-year-old female patient presented with defective vision in both eyes for the past 2 weeks. She had been started on antitubercular medication 5 months earlier for tuberculous lymphadenitis. She was on Rifampicin, Isoniazid, Ethambutol, and Pyrazinamide. Her best-corrected visual acuity (BCVA) at presentation was 6/9, N6 (RE) and 6/18, N18 (LE). Within 2 days, her visual acuity dropped to 6/18, N8 (RE) and counting finger 2 m, N36 (LE). She was a known diabetic for the past 15 years and a hypertensive for 3 years, on treatment. Anterior segment examination was normal. Pupils were reacting normally to light. Fundus examination was normal in both eyes.

She underwent visual field examination (Central 30–2 threshold test, SITA standard) which revealed bitemporal hemianopia [Figure 1a-d]. Color vision was defective in both eyes. Ishihara color plates were used to test color vision. She could identify 9/21 (RE) and 5/21 (LE) plates. Full-field flash Visual evoked potential (VEP) revealed delayed P2 latency and reduced amplitude in both eyes. A magnetic resonance imaging (MRI) of the brain and orbit was normal. Optical coherence tomography (OCT) done revealed thinning of the ganglion cell layer (GCL) in both eyes and normal thickness of the retinal nerve fiber layer (RNFL) in the right eye and thinning of the temporal quadrant of the RNFL in the left eye [Figure 1e-g]. A diagnosis of ethambutol induced optic neuropathy (EION) was made. Ethambutol and Isoniazid were stopped initially. A month later, the patient stopped all antitubercular medication. She was started on multivitamin and mineral supplements. Her vision continued to deteriorate. Six weeks later her visual acuity had plummeted to counting finger 2 m, <N36 (RE) and counting finger 1 m, <N36 (LE).

She was lost to follow-up for a year. When she returned, her visual acuity had improved to 6/60, N36 (RE) and 6/60, N18 (LE). She was continued on multivitamin and mineral supplements. In her last follow up at 20 months after stopping Ethambutol and Isoniazid, her BCVA was 6/24, N8 (RE) and 6/18, N6 (LE). Humphrey field analyzer (HFA) 30–2 using size V stimulus showed normal visual fields [Figure 1h and i]. Full-field Flash VEP showed normal P2 latency and normal amplitude. Fundus examination did not show disc pallor [Figure 1j]. OCT done showed extensive thinning of the GCL in all quadrants and thinning of the RNFL in the superior, inferior and temporal quadrants in both eyes [Figure 1k-m].

To summarize, a 45-year-old female patient was diagnosed to have EION after 5 months of antitubercular medication. Ethambutol and Isoniazid were stopped. She was put on multivitamin and mineral supplements. Her visual acuity continued to drop despite stopping all antitubercular treatment (ATT), but she had partial recovery of vision after one and a half years.

Case 2

A 69-year-old female was referred to our hospital with a history of defective vision in both eyes for the past 3 months. She was diagnosed to have pulmonary tuberculosis and was started on ATT 3 months earlier. She was also a known case of rheumatoid arthritis on tab Hydroxychloroquine (HCQ). Her initial BCVA was 6/6, N6 (RE) and 6/12, N6 (LE). Anterior segment examination showed posterior synechiae in the right eye and pseudophakia. She had an immature senile cataract in the left eye. Intraocular pressure measured by Goldmann Applanation Tonometer was 14 mmHg in the right eye and 13 mmHg in the left eye. Pupillary reaction was slightly sluggish in the right eye and normal in the left eye. Fundus examination revealed small discs with slightly blurred margins and a dull foveal reflex in both eyes [Figure 2a]. Visual field examination (HFA 30–2) revealed central scotomas in both eyes and peripheral constriction in the left eye [Figure 2b and c]. OCT showed normal GCL and RNFL values [Figure 2d and e]. Color vision was defective in the left eye (11/21) and almost normal in the right eye (20/21). Multifocal ERG revealed grossly reduced foveal, parafoveal, and perifoveal ring responses in the right eye and a reduced foveal peak in the left eye [Figure 2f and g]. However, the ellipsoid zone was intact in both eyes signifying that there was no significant retinal toxicity due to HCQ.

Pattern VEP showed borderline P1 latency for both checker sizes and reduced amplitude for 1° and 15 min checker size for both eyes, the left eye being more affected. MRI of the brain was normal. She was diagnosed to have EION. Ethambutol and Isoniazid were stopped. She was supplemented with multivitamins. Her rheumatologist stopped HCQ also.

She reported a month later with a significant drop in vision in both eyes CF3 m, N36 (RE) and CF2 m, N36 (LE)]. A repeat HFA 30–2 using size V stimulus showed a central scotoma in both eyes. OCT showed normal GCL and RNFL values.

Six months later, her vision showed significant improvement in the right eye. BCVA was 6/9, N6 (RE) and 6/60, N18 (LE). Color vision also improved to 21/21 (RE) and 14/21 (LE). Fundus examination was unremarkable. OCT showed generalized thinning of the GCL in both eyes. RNFL values were normal in both eyes.

At the 10th month visit, her BCVA was 6/9, N6 (RE) and 6/60, N18 (LE). HFA 30–2 showed improvement in both

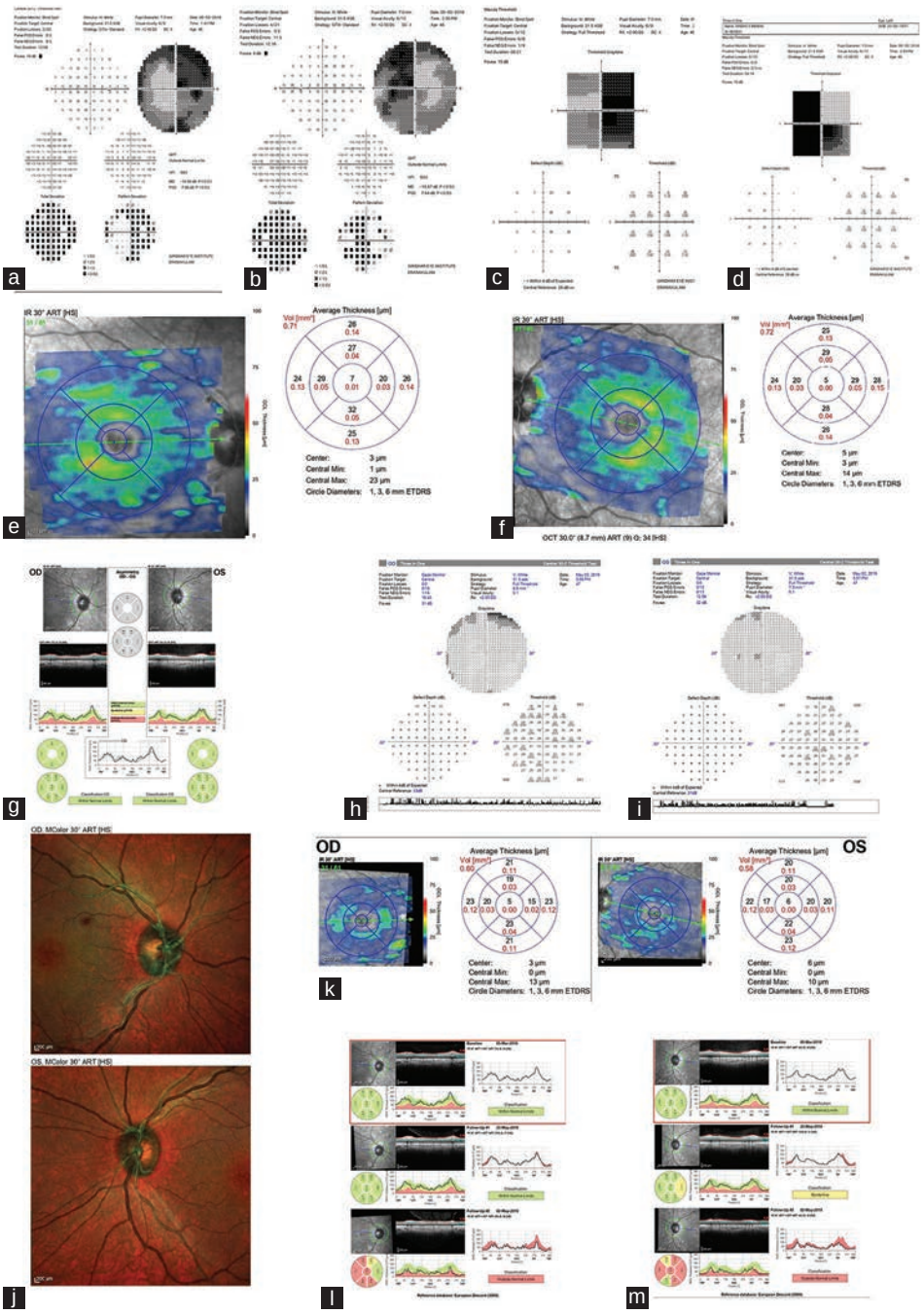

Figure 1: (a) OD humphrey field analyser 30–2.5.13.18, (b) OS humphrey field analyser 30-2.5.3.18, (c) OD Macula 5.3.18, (d) OS Macula 5.3.18, (e) OD ganglion cell layer 23.5.18, (f) OS ganglion cell layer 23.5.18, (g) OU RNFL 5.3.18, (h) OD humphrey field analyser 30-2 2.5.19, Size 5 stimulus, (i) OS humphrey field analyser 30-2 2.5.19, size 5 stimulus, (j) OU MC 2.5.19, (k) OU ganglion cell layer 2.5.19, (l) OD RNFL FU 2.5.19, (m) OS RNFL FU 2.5.19. (MC – Muliticolour photo, FU – Follow up)

eyes [Figure 2h and i]. OCT revealed further deterioration of GCL and temporal thinning of RNFL in both eyes.

She was reviewed 1 year after stopping Ethambutol and Isoniazid. Her BCVA had improved significantly in the left eye also 6/6, N6 (RE), 6/12, N6 (LE)]. GCL and RNFL showed thinning in both eyes. The right eye showed thinning of RNFL in the inferotemporal quadrant and the left eye showed thinning of the temporal and inferotemporal quadrants, corresponding to worse visual acuity in the left eye [Figure 2j and k]. HFA 30–2 showed significant improvement in the visual fields in both eyes [Figure 2l and m].

To summarize, a 69-year-old female was diagnosed to have EION 3 months after starting ATT. Ethambutol and Isoniazid were stopped. She was put on multivitamin and mineral

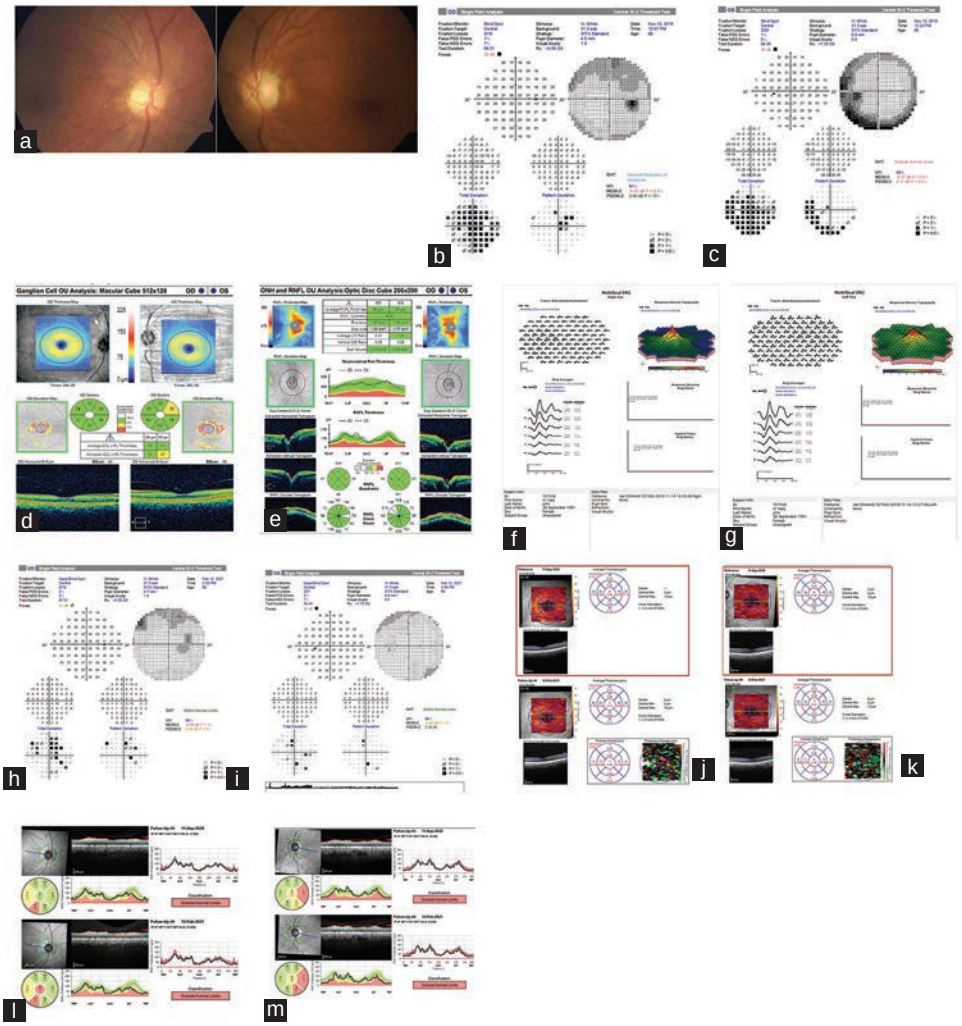

Figure 2: (a) CP 2.12.21, (b) OD humphrey field analyser 30-2 12.11.19, (c) OS humphrey field analyser 30-2 12.1119, (d) OU ganglion cell layer 13.12.19, (e) OU Cirrus OCT ONH and RNFL, (f) OD MFERG 14.11.21, (g) OS MFERG 14.11.21, (h) OD humphrey field analyser 30-2 12.2.21, (j) OD ganglion cell layer FU 12.2.21, (k) OS ganglion cell layer FU 12.2.21, (l) OD RNFL FU 12.2.21, (m) OS RNFL FU 12.2.21. (CP – Colour photo, MFERG – Multifocal ERG)

supplements. Visual acuity continued to drop despite stopping Ethambutol and Isoniazid, but she had a significant and slow recovery of vision a year after stopping Ethambutol.

Case 3

A 24-year old, malnourished young female presented with defective vision in both eyes for the past 2 weeks. She had been diagnosed to have tuberculosis of the ankle bones and was started on ATT 5 months earlier. She was on Rifampicin, Isoniazid, Pyrazinamide and Ethambutol. She had no systemic illness. She had ulcers on both feet. Her initial visual acuity was CF2 m in the right eye and CF1 m in the left eye. She was illiterate, hence near vision, recorded as reduced Snellen, was 6/24 in the right eye and 6/45 in the left eye. Ethambutol had been stopped 2 weeks earlier. Pupils were reacting normally to light. Fundus examination showed a normal disc and macula in both eyes [Figure 3a]. Visual fields and color vision could not be assessed due to her poor visual acuity. Standard deviation (SD)-OCT revealed normal thickness of RNFL and marginal thinning of GCL in both eyes [Figure 3b-d].

She was started on multivitamin supplements. Full-field flash VEP revealed delayed P2 latency in both eyes and reduced amplitude in the left eye [Figure 3f]. Six weeks later, her visual acuity was CF1 m in both eyes. Fundus examination showed mild temporal pallor in both eyes. A repeat SD-OCT showed progressive thinning of both GCL and RNFL in both eyes [Figure 3b-e]. RNFL thinning was visible in the inferotemporal quadrants in both eyes and in temporal quadrants also in the left eye. As her vision was worsening, Isoniazid was also discontinued. The patient stopped ATT on her own a month later. She was reviewed 6 weeks later. Her visual acuity had improved to 6/18, N18 in the right eye. However, the vision in the left eye remained the same at CF1 m, <N36. She was on levofloxacin for her leg ulcers.

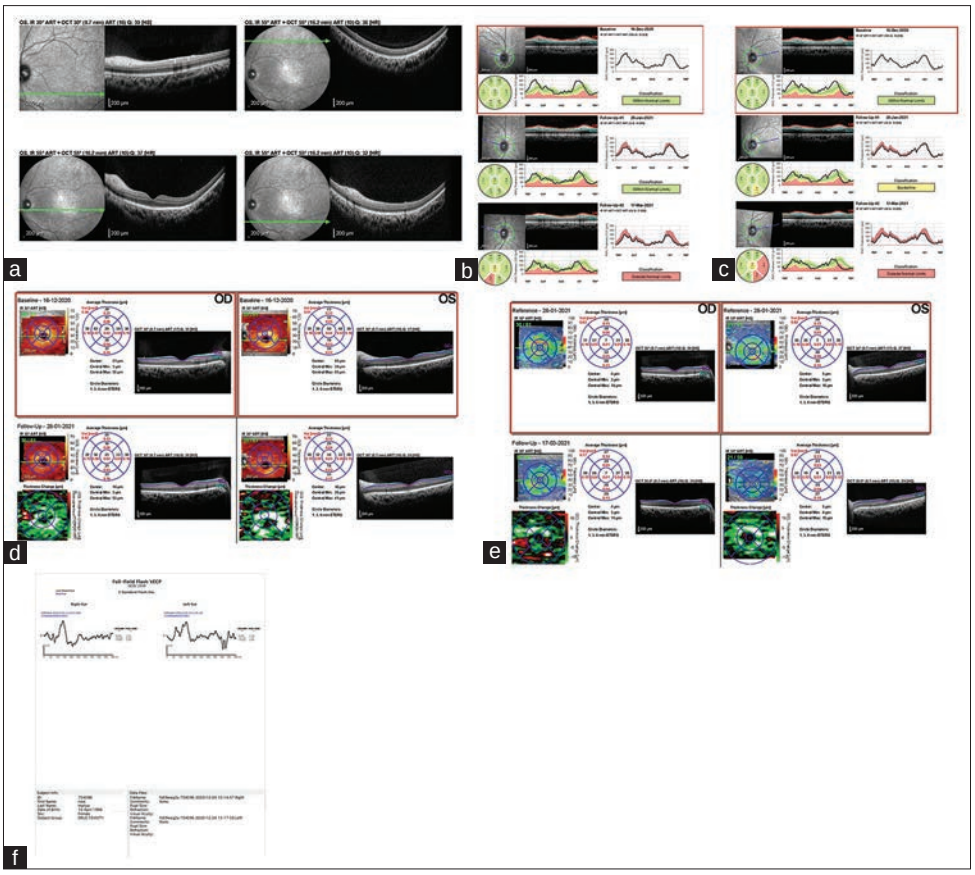

Figure 3: (a) Disc macula wide field image OU 16.12.20, (b) RNFL OD FU 16.12.20 to 17.3 21, (c) OS RNFL FU 16.12.20 to 17.3.21, (d) OU ganglion cell layer FU 16.12.20, 28.1.21, (e) OU ganglion cell layer FU 17.3.21, (f) OU F VEP 24.12.20. (FU – follow up, F VEP – Flash visual evoked potential)

To summarize, a young female patient was diagnosed to have EION after 5 months of ATT. Ethambutol and Isoniazid were stopped and she was put on multivitamin supplements. RNFL and GCL showed progressive thinning, the left eye being more involved. Her visual acuity in the right eye showed significant improvement. However, the vision in the left eye remained the same.

DISCUSSION

In this observational case series, we describe the clinical features and investigations of three patients with EION. All three patients were women with ages ranging from 24 to 69 years. All three presented with defective vision, 3 months to 1 year after starting ATT. The deterioration of vision was rapid and significant, reaching levels such as counting finger 1 m, <N36, and continued to progress despite cessation of ATT. Visual field examination showed bitemporal hemianopia in one patient and central scotomas in another. VEP in all three patients revealed prolonged P1 or P2 latency and reduced amplitude. All three patients showed significant thinning of the GCL in all quadrants and thinning of the RNFL mainly in the inferotemporal and temporal quadrants.

Ethambutol and Isoniazid were stopped. Initially, the vision continued to deteriorate even after stopping the drugs. There was a gradual recovery of visual acuity within a time period of one and a half years. The 24–year-old patient showed a faster recovery of visual acuity compared to the two older patients. The patients were started on multivitamins. There was a significant improvement in the visual fields one to one and a half years after stopping Ethambutol. However, the visual recovery was not complete in all three patients. The improvement in vision was not parallel in both eyes.

EION is one of the most common drug-induced optic neuropathies. It is one of the most important first-line drugs used in the treatment of tuberculosis. The incidence of optic neuropathy is dose-dependent. The incidence is reported to be 5% for patients on 25 mg/kg/day and <1% in patients treated with 15 mg/kg/day.[7]

EION usually presents between 3 and 5 months of starting ATT, though toxicity as early as one and a half months and as late as 12 months of starting therapy have been reported.[8] Our three patients presented between 3 and 5 months of starting ATT.

Considering the severity of the visual loss caused by EION, it is imperative to detect it at an early and subclinical stage to prevent permanent visual loss. The screening modalities used are visual field examination, OCT, and VEP.

Fundus examination in the initial stages is normal, but in the later stages as optic atrophy progresses, disc pallor is noted more specifically temporal pallor.

Visual field examination reveals central, centrocecal scotoma or bitemporal hemianopia. In a case series of six patients reported by Mendel *et al*., four patients presented with bitemporal hemianopia.[9] The temporal field was most commonly affected and the superotemporal quadrant was involved in all their patients. It appears that the retinal ganglion cells and their axons located in an inferior and nasal distribution are more susceptible to EION, causing superotemporal field defects.

OCT provides an objective and quantitative measures of retinal damage. Studies have shown gradual thinning of the RNFL, more significantly in the temporal quadrant of the peripapillary RNFL.[10] Lee *et al*. have shown that loss of ganglion cell inner plexiform layer (GCIPL) thickness indicated early neuronal loss (earlier than RNFL).[11] An important finding in their study was that the amount of reduction in temporal GCIPL thickness negatively correlated with the degree of vision recovery. In their results as the thickness of the remaining GCIPL increased and damage to the GCIPL decreased during follow-up, the possibility of visual recovery before permanent retinal ganglion cell death increased. Therefore, the measurement of GCIPL thickness could predict visual recovery after stopping Ethambutol.

Lee *et al*. noted that temporal GCIPL thinning could be related to poorer visual acuity and become a reflection of the severity of EION. Early GCIPL thinning that is present at the onset of symptoms precedes cpRNFL changes that increase at symptom onset and later normalize at 6 months. They recommend using temporal GCIPL over cpRNFL or macular RNFL as an anatomic marker to predict visual acuity improvement in early phase EION. Although color vision, visual fields, and pattern VEP are sensitive diagnostic tools for EION, they can be performed only in patients with reasonably good vision. OCT is the only diagnostic tool that can be performed, irrespective of the quality of vision.

Pattern VEP is a sensitive and early indicator of Ethambutol toxicity.[12,13] Subclinical toxicity in the form of increased latency of P100 wave of pattern VEP was associated with consumption of a higher daily dose of Ethambutol (18 mg/kg/day).[14]

In our case series, multiple investigations were performed including color photo, visual fields, SD-OCT, VEP, and ERG. Two of the patients showed defective color vision at the initial visit. One of them showed normal GCL and RNFL values on OCT. Though we have presented a small number of patients in our case series, we could infer, which investigations could indicate EION in the subclinical stage. When a suspected case of EION is referred by a physician to the general ophthalmologist, it would be prudent to check color vision as most ophthalmologists would have Ishihara's Charts. Characteristic visual field defects could also point to EION. Our series also showed GCL thinning in the early stages and RNFL thinning, mainly in the inferotemporal and temporal quadrants in the later stage.

VEP proved to be a sensitive indicator of EION. All three patients showed delayed P2 or P1 latency and reduced amplitude in the early stages of EION. Referring a patient for VEP could be worthwhile if one does not have the machine.

Our case series underscores the need to perform a regular ophthalmic evaluation in patients started on Ethambutol. All patients who are newly diagnosed to have tuberculosis should have a baseline ophthalmic examination before commencing treatment with ethambutol. Patients started on ATT should be educated on the potential side effects of the drug. They should be advised to consult an ophthalmologist if they experience any visual symptoms. If the dose taken is more than 15 mg/kg/day, monthly evaluation is warranted.

Once EION is recognized, Ethambutol should be stopped immediately to prevent further visual deterioration. The toxicity is considered reversible on discontinuation of Ethambutol. However, permanent visual impairment has been reported within a follow-up period ranging from 6 months to 3 years, in spite of prompt discontinuation of the drug.[12]

When ocular toxicity is severe, both Ethambutol and Isoniazid should be stopped immediately. About 30% to 50% of patients show recovery to a variable extent after 6–9 months of stopping Ethambutol.[15] In all our three patients, visual acuity continued to deteriorate, despite stopping Ethambutol. This could be due to the cumulative toxicity of Ethambutol and the time taken for the elimination of the drug. However, there was a gradual recovery of vision over a period of three to 14 months. It is important to inform the patient that the improvement of vision, on stopping Ethambutol is not dramatic, but gradual. This information will be a source of encouragement to the patient and may deter the patient from turning to dubious alternative therapies.

CONCLUSION

EION can result in significant loss of vision. If diagnosed early and the drug stopped, reversal of the toxic effects is possible. The treating doctor, the ophthalmologist and the patient should work closely to prevent irreversible visual loss. Early diagnosis using a sensitive indicator is mandatory to prevent irreversible loss of vision. It is important to formulate guidelines for mandatory ophthalmic evaluation in patients on treatment with Ethambutol.

Declaration of patient consent

The authors certify that they have obtained all appropriate patient consent forms. In the form the patient (s) has/have given his/her/their consent for his/her/their images and other clinical information to be reported in the journal. The patients understand that their names and initial s will not be published and due efforts will be made to conceal their identity, but anonymity cannot be guaranteed.

Financial support and sponsorship

Nil.

Conflicts of interest

There are no conflicts of interest.

REFERENCES

1. Varma D, Anand S, Reddy AR, Das A, Watson JP, Currie DC, *et al.* Tuberculosis: An under-diagnosed aetiological agent in uveitis with an effective treatment. Eye (Lond) 2006;20:1068-73.
2. Chaudhari A. Recent changes in technical and operational guidelines for tuberculosis control programme in India-2016. A paradigm shift in tuberculosis control. J Assoc Chest Phys 2017;5:1.
3. Central TB Division. RNTCP Updated TB Guidelines 2019. New Delhi: Ministry of Health and Family Welfare; 2019.
4. Carr RE, Henkind P. Ocular manifestations of ethambutol, Toxic amblyopia after administration of an experimental antituberculous drug. Arch Ophthalmol 1962;67:566-71.
5. Chung H, Yoon YH, Hwang JJ, Cho KS, Koh JY, Kim JG. Ethambutol-induced toxicity is mediated by zinc and lysosomal membrane permeabilization in cultured retinal cells. Toxicol Appl Pharmacol 2009;235:163-70.
6. Talbert Estlin KA, Sadun AA. Risk factors for ethambutol optic toxicity. Int Ophthalmol 2010;30:63-72.
7. Goodman BL, Knollmann BC. Goodman and Gilman's the Pharmacological Basis of Therapeutics. 13th ed. New York: McGraw-Hill Medical; 2018. p. 1074.
8. Sivakumaran P, Harrison AC, Marschner J, Martin P. Ocular toxicity from ethambutol, a review of 4 cases and recommended precautions. NZ Med J 1998;111:428-30.
9. Mendel T, Fleischman D, Allingham RR, Tseng H, Chesnutt DA. Spectrum and clinical course of visual field abnormalities in ethambutol toxicity. Neuroophthalmology 2016;40:139-45.
10. Zoumalan CI, Agarwal M, Sadun AA. Optical coherence tomography can measure axonal loss in patients with ethambutol-induced optic neuropathy. Graefes Arch Clin Exp Ophthalmol 2005;243:410-6.
11. Lee JY, Choi JH, Park KA, Oh SY. Ganglion cell layer and inner plexiform layer as predictors of vision recovery in ethambutol-induced optic neuropathy: A longitudinal OCT analysis. Invest Ophthalmol Vis Sci 2018;59:2104-9.
12. Kim KL, Park SP. Visual function test for early detection of ethambutol induced ocular toxicity at the subclinical level. Cutan Ocul Toxicol 2016;35:228-32.
13. Kumar A, Dada T. Visual evoked response (VER) in ocular ethambutol toxicity. Natl Med J India 1999;12:193-4.
14. Mandal S, Saxena R, Dhiman R, Mohan A, Padhy SK, Phuljhele S, *et al.* Prospective study to evaluate incidence and indicators for early detection of ethambutol toxicity. Br J Ophthalmol. 2021;105:1024-8. [doi: 10.1136/bjophthalmol-2020-316897]. Epub 2020 Jul 26. PMID: 32713840.
15. Kumar A, Sandramouli S, Verma L, Tewari HK, Khosla PK. Ocular ethambutol toxicity: Is it reversible? J Clin Neurophthalmol 1993;13:15-7.

Case Report

Custard apple-induced toxic keratopathy

ABSTRACT

Custard apple seeds are a natural remedy for head lice. We report a case series of three patients with ocular exposure to custard apple seeds. All three developed toxic keratopathy which was treated with topical antibiotics and soft steroids and they responded well to the treatment. This report is intended to increase the awareness in this regard.

Keywords: *Annona squamosa*, custard apple, toxic keratopathy

INTRODUCTION

Custard apple (*Annona squamosa*) commonly known as "sitaphal" belongs to the family Annonaceae which is a large family comprising about 135 genera and more than 2500 species distributed mainly in tropical and subtropical regions.[1] In folklore medicine, various parts of *A. squamosa* are used for the treatment of many diseases. The extract from the leaves is used as antidiabetic, anti-ulcer, antidepressant, anti-inflammatory, and antimicrobial. The seed powder is used to kill head lice and fleas as well as for skin exfoliation. *A. squamosa* plant extract contains steroids, terpenoids, glycoside, alkaloid, flavonoid saponin, phenolic compounds, and acetogenins.[2] Hence, when this comes in contact with the eyes, it causes severe inflammation and toxic keratopathy.

Even though some cases have been reported before, general public and even doctors are not well aware of the hazardous effects of this natural remedy. We report three cases with toxic keratopathy due to accidental eye contact with custard apple seed powder applied over the scalp to increase the awareness about the toxic effects of this plant.

CASE REOPRT

Three patients from the same family (mother and two daughters) presented to us with a history of applying custard apple seed powder over the scalp as a treatment for head lice. On the next day, patients started experiencing symptoms and they presented to us on the 3rd day.

Case 1

A 35-year-old female patient presented with photophobia, difficulty in opening the eye, and pain in the left eye. On examination, she had unaided visual acuity of 6/9 in the right eye improving to 6/6 with pin hole and 6/18 p in the left eye not improving with pinhole. After applying topical proparacaine drops, the patient opened her eyes. There was mild upper and lower lidedema, severe conjunctival congestion, and central epithelial defect measuring 4 mm × 4 mm, and her anterior chamber was quiet. She was treated with topical moxifloxacin 0.5% eye drops 4 times/day, hydroxyl propyl methyl cellulose drops and gel 2%, and loteprednol 0.5% eye drops 4 times/day. On the next day, she complained of pain in the left eye and there was an epithelial defect of 7 mm × 6 mm size with loose epithelium above that, central Descemet membrane folds [Figure 1a and b], and + 0.5 cells in the anterior chamber. The loose epithelium was debrided and she was advised to continue the same medications. The size of the epithelial defect decreased by the 3rd day and the

R. Sruthi, G. S. Kalaimathi, Vinay S. Pillai

Department of Ophthalmology, Giridhar Eye Institute, Kochi, Kerala, India

Address for correspondence: Dr. R. Sruthi,
Giridhar Eye Institute, Kochi - 682 020, Kerala, India.
E-mail: drsruthigokul@gmail.com

Submitted: 10-Jan-2021 **Revised:** 12-Jan-2021
Accepted: 02-Feb-2021 **Published:** 21-Apr-2022

Access this article online	
Website: www.kjophthal.com	Quick Response Code
DOI: 10.4103/kjo.kjo_5_21	

This is an open access journal, and articles are distributed under the terms of the Creative Commons Attribution-NonCommercial-ShareAlike 4.0 License, which allows others to remix, tweak, and build upon the work non-commercially, as long as appropriate credit is given and the new creations are licensed under the identical terms.

For reprints contact: WKHLRPMedknow_reprints@wolterskluwer.com

How to cite this article: Sruthi R, Kalaimathi GS, Pillai VS. Custard apple-induced toxic keratopathy. Kerala J Ophthalmol 2022;34:62-4.

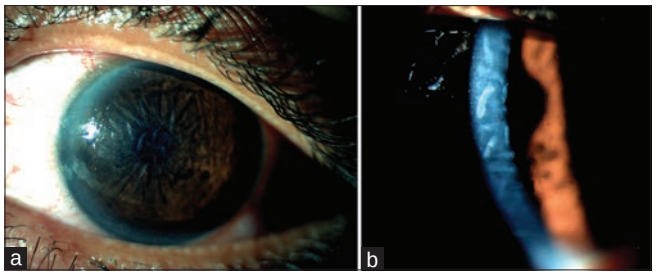

Figure 1: (a) Anterior segment photo of Case 1 on day 2: Large epithelial defect with Descemet membrane folds (after scraping the loose epithelium). (b) Anterior segment photo (with slit) of the case 1 on day 2: Epithelial defect with Descemet membrane folds

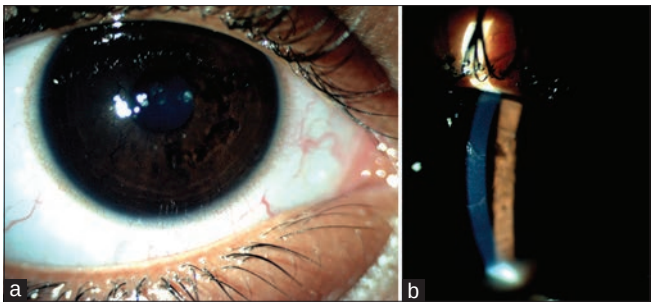

Figure 2: (a) Anterior segment image of case 2 on day 2: Central epithelial defect. (b) Anterior segment image (with slit) of case 2 on day 2: Central epithelial defect

defect completely healed by day 5. The anterior chamber became quiet by then.

Case 2

A 7-year-old female child presented with photophobia, difficulty in opening the eyes, and pain in both eyes. On examination, after applying topical proparacaine eye drops, vision with glasses in both eyes was 6/18. There was upper and lower lid edema, severe conjunctival congestion, and central epithelial defect measuring 5 mm × 4 mm in both eyes and the anterior chambers were quiet. She was given topical fluorometholone and tobramycin combination eye drops 4 times/day, carboxymethyl cellulose sodium eye drops 2 hourly, and hydroxyl propyl methyl cellulose eye ointment. On the next day, she improved symptomatically and the epithelial defect in the right eye decreased in size [Figure 2a and b] and the defect in the left eye resolved completely. The epithelium in the right eye was completely regenerated by day 3.

Case 3

A 4-year-old female child presented with the same symptoms as mentioned above. On examination, she had upper and lower lidedema in both eyes, conjunctival congestion in both eyes, and small central epithelial defect of size 2 mm × 2 mm and punctate epithelial erosions in both eyes. She was also given topical fluorometholone and tobramycin combination eye drops 4 times/day and carboxy methyl cellulose eye drops 2 hourly. On the next day, her epithelial defect healed completely and only punctuate epithelial erosions were remaining. Cornea became clear by day 3 in both eyes.

DISCUSSION

There have been only a few reports of toxic keratopathy induced by custard apple seeds to our knowledge. In 2016, Nagaraja *et al*.[3] reported a case series of six patients with custard apple-induced keratopathy. They suggested avoidance of topical steroids as there was an increased chance of infective keratitis. Pratheeba Devi *et al*.[4] in 2017 published two cases of custard apple-induced keratopathy which were treated with epithelial debridement, topical antibiotics, and patching. The largest published series is by Gandhi *et al*.[5] in which they reported nineteen similar cases.

In an experiment published by Sookvanichsilp N *et al*.,[6] the extracts of active compounds of leaves and seeds from *A. squamosa* in four organic solvents, i.e., petroleum ether, ether, chloroform, and ethanol, were tested for toxicity to the eyes, ear, and skin of rabbits. The results revealed that some extracts caused conjunctival redness, chemosis, rugged cornea, skin erythema, and edema.

Similarly, in human eyes, the toxin mainly affects the cornea and the conjunctiva and causes conjunctival congestion, epithelial erosions, and loose epithelium which leads to an epithelial defect. We used soft steroids along with topical antibiotics in all three cases and the epithelium completely healed by day 5. Soft steroids reduced the inflammation due to toxicity, lubricants helped in healing, and comfort and the antibiotics prevented infection. We removed the loose epithelium in one patient. There was no evidence of infective keratitis in any of the cases. The aggressive treatment and frequent follow-ups are the key factors in regaining the integrity of the ocular surface.

CONCLUSION

The ocular exposure of custard apple seeds is highly toxic to the ocular surface. Careful management and follow-ups will prevent infective keratitis as well as help in regeneration of the epithelium and reduction of the inflammation. Patients need to be educated about the ill effects of this traditional remedy.

Declaration of patient consent

The authors certify that they have obtained all appropriate patient consent forms. In the form the patient (s) has/have given his/her/their consent for his/her/their images and other clinical information to be reported in the journal. The patients

understand that their names and initials will not be published and due efforts will be made to conceal their identity, but anonymity cannot be guaranteed.

Financial support and sponsorship

Nil.

Conflicts of interest

There are no conflicts of interest.

REFERENCES

1. Al-Ghazzawi AM. Anti-cancer activity of new benzyl isoquinoline alkaloid from Saudi plant *Annona squamosal*. BMC Chem 2019;13:13.
2. Saha R. Pharmacognosy and pharmacology of *Annona squamosa*: A review. Int J Pharm Life Sci 2011;2:1183-9.
3. Nagaraja H, Kugar T, Shivanna Y, Agrawal A, Shetty R. Ocular toxicity by seeds of *Annona squamosa* (custard apple). Indian J Ophthalmol 2016;64:611-3.
4. Nivean PD, Malarkodi S, Nishanth M, Nivean M. Custard apple seed induced keratitis: A harmful traditional practice in South India. GMS ophthalmology cases. 2017;7:Doc 23.
5. Gandhi P, Radhakrishnan N, Khaitan I, Srinivasan M, Prajna VN. Toxic keratitis after application of custard apple seed for head lice infestation. Cornea 2019;38:948-50.
6. Sookvanichsilp N, Gritsanapan W, Somanabandhu AO, Lekcharoen K, Tiankrop P. Toxicity testing of organic solvent extracts from *Annona squamosa*: Effects on rabbit eyes and ear skin. Phytother Res 1994;8:365-8.

Case Report

A rare case of Vogt–Koyanagi–Harada disease presenting simultaneously with pituitary macroadenoma

ABSTRACT

A 45-year-old female presented with sudden painful loss of vision in both eyes of 1-week duration. Clinical findings and imaging studies suggested Vogt–Koyanagi–Harada (VKH) disease. She was started on systemic steroids. Nonresolution of periocular pain and presence of color vision defects prompted us to do neuroimaging study which detected a pituitary macroadenoma. The patient underwent surgical removal of the mass lesion. There was a complete resolution of VKH features with systemic steroids.

Keywords: Macroadenoma, pituitary, steroids, Vogt–Koyanagi–Harada disease

INTRODUCTION

Vogt–Koyanagi–Harada (VKH) disease is an idiopathic inflammatory disease characterized by bilateral granulomatous panuveitis.[1] Ocular findings in the acute stage of the disease include multifocal neurosensory detachment, choroidal detachment, and optic disc hyperemia or swelling.[2] Prolonged immunosuppression forms the cornerstone of therapy. I report a rare case of VKH disease presenting with pituitary macroadenoma simultaneously.

CASE REPORT

A 45-year-old female presented with sudden onset painful loss of vision in both eyes (BE) of 1-week duration. The patient gave a history of having headache and eye ache for the last 2 months. There was a history of fever, flu-like symptoms, and increasing intensity of periorbital pain 1 week prior to vision loss. She had been diagnosed elsewhere as a case of posterior uveitis in BE and had been advised systemic steroids. Best-corrected visual acuity (BCVA) in BE was 20/200, N36. Anterior segment was within normal limits in BE. Pupils were reacting sluggishly to light bilaterally. Intraocular pressure was 16 and 18 mmHg in the right eye (RE) and left eye, respectively. Fundus examination revealed 1 + cells in vitreous, significant disc edema, and exudative macular detachment bilaterally [Figure 1]. A pocket of subretinal fluid was noted superior to the optic disc in RE also. The patient had undergone optical coherence tomography (OCT) elsewhere which showed pockets of neurosensory detachment with intervening septae in BE. The fluid within the pockets appeared hyperreflective which was suggestive of high fibrin content. Fundus fluorescein angiography showed early pinpoint hyperfluorescence in the macular area in BE with increasing leakage from these points as the angiography proceeded. Bilateral disc leakage was noted [Figure 2]. Ultrasound examination showed lens echo, few low reflective dot echoes, increased choroidal thickness, and absent T-sign in BE.

We diagnosed it as a case of VKH disease in BE. Routine blood investigations, blood sugar, and baseline investigations

Pradeep Kumar Panigrahi

Department of Ophthalmology, Institute of Medical Sciences and SUM Hospital, SOA (Deemed to be) University, Bhubaneswar, Odisha, India

Address for correspondence: Dr. Pradeep Kumar Panigrahi, Department of Ophthalmology, Institute of Medical Sciences and SUM Hospital, SOA (Deemed to be) University, 8-Kalinga Nagar, Bhubaneswar - 751 003, Odisha, India.
E-mail: doc.pkp25@gmail.com

Submitted: 17-Jun-2021 **Revised:** 24-Jun-2021
Accepted: 28-Jun-2021 **Published:** 21-Apr-2022

Access this article online	
Website: www.kjophthal.com	Quick Response Code
DOI: 10.4103/kjo.kjo_144_21	

This is an open access journal, and articles are distributed under the terms of the Creative Commons Attribution-NonCommercial-ShareAlike 4.0 License, which allows others to remix, tweak, and build upon the work non-commercially, as long as appropriate credit is given and the new creations are licensed under the identical terms.

For reprints contact: WKHLRPMedknow_reprints@wolterskluwer.com

How to cite this article: Panigrahi PK. A rare case of Vogt–Koyanagi–Harada disease presenting simultaneously with pituitary macroadenoma. Kerala J Ophthalmol 2022;34:65-7.

for sarcoidosis, tuberculosis, and syphilis were normal. The patient was started on intravenous methylprednisolone (1 g mixed in 300 ml normal saline) for 3 days. After completion of pulse steroid therapy, the patient was started on oral steroids (Tablet Omnacortil 1 mg/kg after heavy breakfast), proton-pump inhibitors, and calcium supplements. The patient came for review 2 weeks later. She reported mild improvement in vision, but there was no relief from the periocular pain. BCVA in BE was 20/120, N24. Pupils were sluggishly reacting to light in BE. Color vision done using Ishihara's chart was defective in BE. Fundus examination showed decreasing subretinal fluid in the macular area but a minimal reduction in disc edema. At this point of time, we advised magnetic resonance imaging (MRI) of the brain to rule out any other possible etiology responsible for disc edema. MRI scans revealed a well-defined lobulated heterogeneously enhancing hyperintense lesion (12 mm × 13 mm) in the sellar and suprasellar region with chiasmal compression suggestive of pituitary macroadenoma [Figure 3]. The patient was immediately referred to the neurosurgery department where she was advised surgical removal of the adenoma. The patient underwent successful removal of the tumor through the transsphenoidal approach 3 weeks following initial presentation.

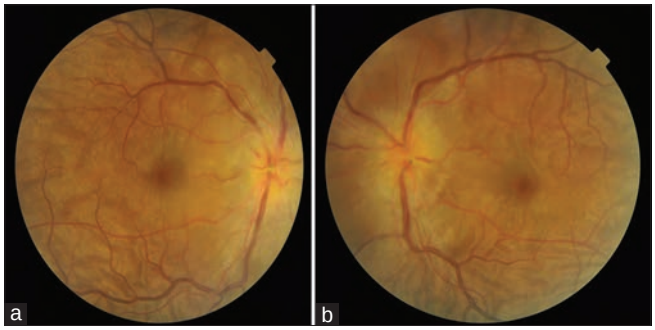

Figure 1: (a and b) Color fundus photograph of the right and left eye showing disc edema and macular neurosensory detachment

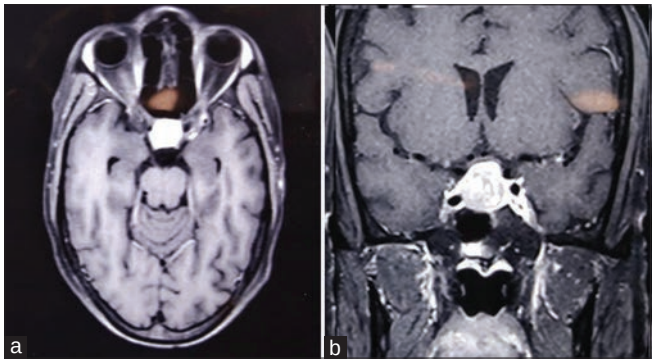

Figure 3: Axial (a) and coronal (b) magnetic resonance imaging scans of the brain showing a well-defined hyperintense lobulated lesion in the sellar and suprasellar region suggestive of pituitary macroadenoma

Six weeks following the presentation, BCVA in BE was 20/80, N12. Disc edema and exudative macular detachment had resolved. Few hard exudates were noted in the macular area bilaterally [Figure 4a and b]. OCT showed complete resolution of neurosensory detachment [Figure 4c and d]. Oral steroids were slowly tapered over a period of 6 months. At final follow-up, 6 months after presentation BCVA remained stable at 20/60, N12 in BE. Bilateral disc

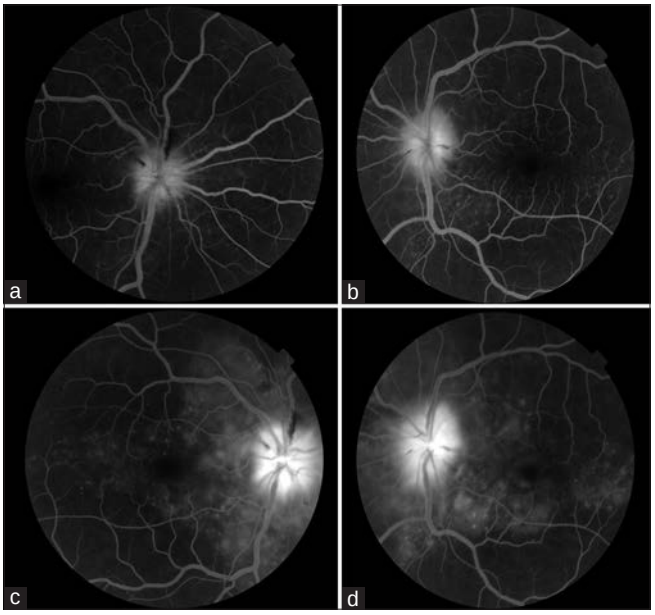

Figure 2: (a and b) Fundus fluorescein angiography showing disc edema and early pinpoint hyperfluorescent lesions in the macular area bilaterally. (c and d) Fundus fluorescein angiography images showing a progressive increase in disc and macular leakage bilaterally in the late phases of angiography

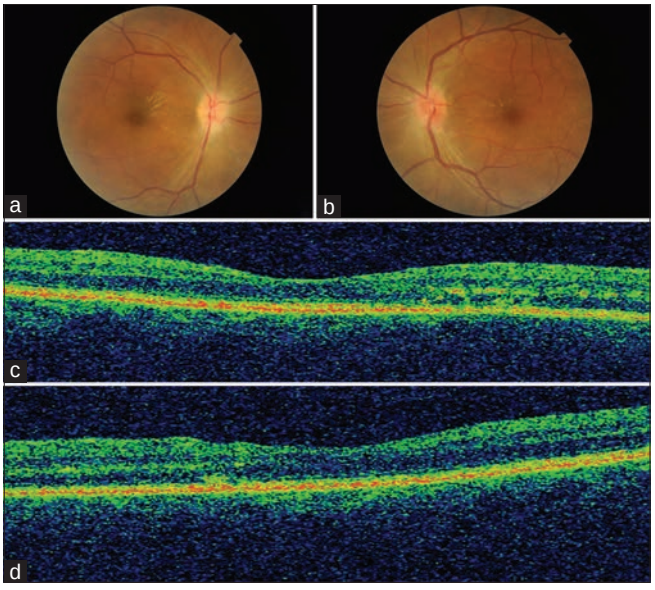

Figure 4: (a and b) Color fundus photograph of the right and left eye showing resolved disc and macular edema with few hard exudates in the macular area bilaterally. (c and d) Optical coherence tomography images of the right and left eye showing resolved neurosensory detachment bilaterally

pallor suggestive of optic atrophy was noted in BE. Macula was dry bilaterally.

DISCUSSION

Pituitary adenomas are usually benign tumors. Clinically nonfunctioning pituitary adenomas are the most common subtype which are characterized by the absence of clinical evidence of hormonal secretion.[3] There were no clinical signs of hormonal secretion in the present case. Visual symptoms produced depend on the size of the lesion. Pituitary macroadenomas (>1 cm) can lead to ocular symptoms such as field defects, eye pain, headache, blurring of vision, and double vision.[4] Compression of optic nerves, if not relieved early, can lead to optic atrophy and permanent vision loss.[5]

The present case presented with clinical and angiographic features of VKH disease. Patients with VKH disease also present with headache and periocular pain which usually get resolved soon with the initiation of systemic steroid therapy. Nonresolution of periocular pain 2 weeks after steroid therapy and the presence of color vision defects prompted us to go for neuroimaging study. Although there was resolution of disc edema and neurosensory detachment, the final visual acuity was poor. This could be due to optic atrophy induced by tumor compression. Simultaneous presentation of VKH disease and pituitary adenoma has not been reported earlier. However, the association seems more coincidental rather than causal in this case.

CONCLUSION

The present case highlights the importance of performing additional investigation in all cases where the response to treatment is suboptimal. Early diagnosis and treatment of newly detected diseases can help salvage vision in such cases.

Declaration of patient consent

The authors certify that they have obtained all appropriate patient consent forms. In the form the patient(s) has/have given his/her/their consent for his/her/their images and other clinical information to be reported in the journal. The patients understand that their names and initials will not be published and due efforts will be made to conceal their identity, but anonymity cannot be guaranteed.

Financial support and sponsorship

Nil.

Conflicts of interest

There are no conflicts of interest.

REFERENCES

1. Fang W, Yang P. Vogt-koyanagi-harada syndrome. Curr Eye Res 2008;33:517-23.
2. Katsuyama A, Kusuhara S, Awano H, Nagase H, Matsumiya W, Nakamura M. A case of probable Vogt-Koyanagi-Harada disease in a 3-year-old girl. BMC Ophthalmol 2019;19:179.
3. Ntali G, Wass JA. Epidemiology, clinical presentation and diagnosis of non-functioning pituitary adenomas. Pituitary 2018;21:111-8.
4. Kitthaweesin K, Ployprasith C. Ocular manifestations of suprasellar tumors. J Med Assoc Thai 2008;91:711-5.
5. Abouaf L, Vighetto A, Lebas M. Neuro-ophthalmologic exploration in non-functioning pituitary adenoma. Ann Endocrinol (Paris) 2015;76:210-9.

Case Report

Case of multiple sclerosis presenting as unilateral internuclear ophthalmoplegia

ABSTRACT

A 30-year-old female presented with complaints of decreased vision and diplopia since 1 week along with headache and gait disturbances. Examination revealed medial restriction of ocular movements in the right with left abducting nystagmus suggestive of right-sided internuclear ophthalmoplegia and right-sided facial palsy. The patient was admitted under neurology as a suspected case of demyelinating disorder. Magnetic resonance imaging with gadolinium contrast revealed features suggestive of probably multiple sclerosis (MS). The patient was given 5 days of high-dose intravenous steroids following which the patient showed improvement and was discharged on multivitamins. Subsequent follow-up showed significant improvement in symptoms, visual acuity, and ocular movements. Hereby presenting a rare case of MS presenting as unilateral internuclear ophthalmoplegia.

Keywords: Internuclear ophthalmoplegia, magnetic resonance imaging, multiple sclerosis, neuro-ophthalmology

INTRODUCTION

Multiple sclerosis (MS) is an immune-mediated inflammatory disease that attacks and destroys the myelinated axons in the central nervous system.[1,2] MS is more common in females than males between the age of 20 and 40 years.[3] The cause of MS is unknown. MS results in various ophthalmic findings of which, commonly presenting symptoms include optic neuritis (seen in 20% cases as primary presentation), internuclear ophthalmoplegia (bilateral > unilateral), and nystagmus. Unusual presentations include visual field loss, gaze palsies, and isolated ocular motor palsies.[4] Internuclear ophthalmoplegia is characterized by a deficit in ipsilateral adduction with contralateral abducting nystagmus which mainly occurs due to lesion in the medial longitudinal fasciculus.[5,6] Causes of internuclear ophthalmoplegia are MS, brain infarction, head trauma, infection, hydrocephalus, brainstem tumors, and lupus erythematosus.[7] There can be varied presentations in MS as it can affect any white matter tract of the central nervous system and also no single test can diagnose MS, hence diagnosis is based on both clinical examination and laboratory evaluation. We hereby report a case of MS presenting as unilateral internuclear ophthalmoplegia.

CASE REPORT

A healthy 30-year-old female presented to our outpatient department with a history of blurring of vision and diplopia of 1 week duration, which aggravated on left-sided gaze. She had a headache which was generalized throbbing type along with gait disturbances and also on and off tingling and numbness of the upper and lower extremities. The patient was not a known case of any systemic illness. There was no history of ocular trauma, head injury, or chronic drug intake

Aishwarya M. Angadi

Department of Ophthalmology, Goa Medical College, Bambolim, Goa, India

Address for correspondence: Dr. Aishwarya M. Angadi, 2-10-786/16 "Aishwarya Nilaya" Bejai Nodu Lane, Mangalore - 575 004, Karnataka, India.
E-mail: aishwaryamalli@gmail.com

Submitted: 21-Jun-2021 **Accepted:** 07-Jul-2021 **Published:** 21-Apr-2022

Access this article online	
Website: www.kjophthal.com	Quick Response Code
DOI: 10.4103/kjo.kjo_148_21	

This is an open access journal, and articles are distributed under the terms of the Creative Commons Attribution-NonCommercial-ShareAlike 4.0 License, which allows others to remix, tweak, and build upon the work non-commercially, as long as appropriate credit is given and the new creations are licensed under the identical terms.

For reprints contact: WKHLRPMedknow_reprints@wolterskluwer.com

How to cite this article: Angadi AM. Case of multiple sclerosis presenting as unilateral internuclear ophthalmoplegia. Kerala J Ophthalmol 2022;34:68-70.

prior to the episode. There was no significant past history or family history. On examination, visual acuity was 20/50 OU which did not improve with pinhole. Pupils were 3 mm reacting to both direct and consensual light reflex. Ocular movements were restricted medially in the right eye with horizontal nystagmus on abduction of the left eye suggestive of right internuclear ophthalmoplegia [Figure 1]. Rest of the anterior segment of both eyes by slit-lamp examination, including intraocular pressure was within normal limits. Color vision, dilated fundoscopy, and visual field testing by Humphreys field analyzer were within normal limits in both eyes. Neurological examination revealed right facial weakness, gait ataxia with brisk deep tendon reflexes. As a demyelinating disease was suspected, magnetic resonance imaging (MRI) was done and showed multiple lesions along with the subcortical and periventricular white matter in bilateral fronto-temporo-parieto-occipital region, bilateral centrum semiovale, perpendicular to callososeptal interface, the brainstem and cerebellum showing varying degrees and patterns of enhancement all these features suggestive of demyelinating disorder, likely MS [Figure 2]. The patient's Vitamin D level was below normal. Lumbar puncture was done and oligoclonal bands and raised chloride level was detected in cerebrospinal fluid. The patient was also positive for antineutrophil cytoplasmic antibody in the serum. Rest of the routine blood investigations were within normal limits. The patient received 5 days of high-dose injectable steroids, after clearance from physician, and showed symptomatic improvement within a week. Following which she was shifted to oral steroids according to body weight and was discharged on multivitamin and calcium supplements. Follow-up examination of the patient after 6 weeks showed improvement in terms of vision and ocular movements and did not have symptoms of diplopia.

DISCUSSION

The most common presentation of MS is optic neuritis, internuclear ophthalmoplegia. Unilateral internuclear ophthalmoplegia is much less common presenting feature when compared to bilateral in a case of MS. The primary symptom of internuclear ophthalmoplegia is diplopia on lateral gaze because of paresis of the adducting eye and is a strong evidence of MS; however systemic lupus erythematosus and small basilar artery strokes may also cause it. The cause of internuclear ophthalmoplegia is commonly MS in young adults especially when the syndrome is bilateral. But ours is a rare case of MS presenting as unilateral internuclear ophthalmoplegia. The patient on investigating had the presence of oligoclonal band in the cerebrospinal fluid analysis had low levels of vitamin D and also MRI lesions suggestive of MS. Combining both examination and investigations she was diagnosed as a case of MS.

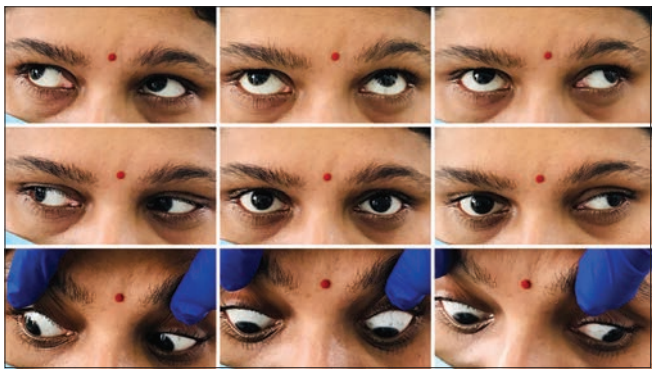

Figure 1: Picture showing ocular movements in all 9 gazes, suggestive of right-sided internuclear ophthalmoplegia

CONCLUSION

MS should be a differential diagnosis in young patients presenting with visual loss, ocular movement disorders, gaze palsies (unilateral/bilateral). It is difficult to come to a diagnosis of MS as there is no single diagnostic test but it is a combination of clinical and laboratory evaluation.

Acknowledgment

We would like to express our sincere gratitude to Dr. Aparna G. Naik (Lecturer, Department of Ophthalmology, Goa Medical College) for her invaluable guidance and encouragement in the successful completion of this case report.

Declaration of patient consent

The authors certify that they have obtained all appropriate patient consent forms. In the form the patient (s) has/have given his/her/their consent for his/her/their images and other clinical information to be reported in the journal. The patients

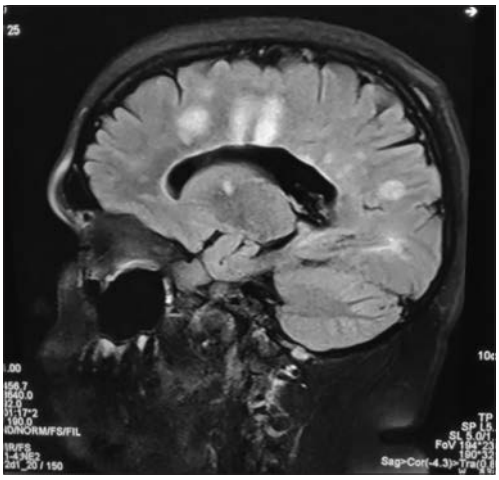

Figure 2: T2-weighted magnetic resonance imaging showing white matter hyperintensity and also hyperintensity in the pericallosal region suggestive of Dawson finger

understand that their names and initial s will not be published and due efforts will be made to conceal their identity, but anonymity cannot be guaranteed.

Financial support and sponsorship

Nil.

Conflicts of interest

There are no conflicts of interest.

REFERENCES

1. Multiple Sclerosis: Practice Essentials, Background, Pathophysiology. Available from: https://emedicine.medscape.com/article/1146199-overview. [Last accessed on 2021 Jun 18].
2. Diagnosis and Treatment of Multiple Sclerosis | The BMJ. Available from: https://www.bmj.com/content/332/7540/525.short. [Last accessed on 2021 Jun 18].
3. Harbo HF, Gold R, Tintoré M. Sex and gender issues in multiple sclerosis. Ther Adv Neurol Disord 2013;6:237-48.
4. Chen L, Gordon LK. Ocular manifestations of multiple sclerosis. Curr Opin Ophthalmol 2005;16:315-20.
5. Internuclear Ophthalmoplegia-EyeWiki. Available from: https://eyewiki.aao.org/Internuclear_Ophthalmoplegia. [Last accessed on 2021 Jun 18].
6. Sharma R, Saxena R, Bhatia R, Menon V. Multiple Sclerosis – An Ophthalmologist's perspective.DJO 2013;23:251-256. Available from: https://www.djo.org.in/articles/23/4/multiple-sclerosis-an-ophthalmologists-perspective.html. [Last accessed on 2021 Dec 15].
7. Obuchowska I, Mariak Z. Internuclear ophthalmoplegia – Causes, symptoms and management. Klin Oczna 2009;111:165-7.

Photo Essay

Pachychoroid disease mimicking pattern dystrophy

ABSTRACT

We report a case of pachychoroid disease with bilateral vitelliform lesions simulating pattern dystrophy. One eye showed spontaneous resolution of the deposits, while the other eye demonstrated recurrent deposition with onset of choroidal neovascular membrane over a 3-year follow-up. The purpose of this manuscript is to highlight the importance of multimodal imaging which would help us to differentiate mimics of pattern dystrophy.

Keywords: Pachychoroid disease, pattern dystrophy, vitelliform lesions

INTRODUCTION

Acquired vitelliform lesions (AVL) are subretinal autofluoresecent depositions reported in various dystrophic, degenerative, toxic, paraneoplastic, and vitreoretinal interface disorders involving the macula. The natural course of these lesions is often characterized by a gradual break down and slow resorption, resulting in photoreceptor disruption and eventual atrophy. Here, we are reporting multimodal imaging of a case of bilateral AVL with pachychoroid. This case also demonstrates the observation that these acquired vitelliform deposits herald the transformation of an nonexudative choroidal neovascular membrane (CNVM) to an exudative one.

CASE REPORT

A 67-year-old female reported in 2017 with gradual diminution of vision in RE over the past 1 year. Her BCVA was 6/9 in the right eye and 6/6 in the left eye. Fundus evaluation revealed RPE alterations with vitelliform-like lesions simulating pattern dystrophy in both eyes. The vitelliform deposits were seen on OCT which also revealed pachychoroid features with a shallow pigment epithelial detachment (PED) with subretinal clear spaces in the right eye and a focal extrafoveal double layer sign (DLS) in the left eye [Figure 1]. The typical increased autofluorescence was evident from vitelliform lesion on Blue peak AF [Figure 2]. These deposits also showed increased reflectance on IR imaging [Figure 2]. Even though FFA/ICG angiography did not reveal any neovascular membrane in either eye [Figure 3a-h], OCTA showed a nonexudative CNVM in the left eye corresponding to focal DLS [Figure 3i]. There was no positive family history, and EOG was normal. On follow-up over the next 3 years, the right eye showed spontaneous resolution of the vitelliform deposits [Figures 4 and 5], whereas the left eye demonstrated multiple recurrence of deposition at different locations with progression of nonexudative CNVM to exudative CNVM [Figures 4 and 5]. As the patient was symptomatic with decrease in BCVA with the occurrence of exudative CNVM in the left eye, she was treated with two doses of intravitreal Ranibizumab which resulted in resolution of fluid and improvement in vision [Figure 6]. She continues to be on follow-up since then.

Soman Manoj, Sameer Iqbal[1], Padmanaban Meleth[1], Unnikrishnan Nair R[1]

Departments of Vitreo-Retinal Service and [1]Department of Vitreo Retinal Services, Chaithanya Eye Hospital and Research Institute, Thiruvananthapuram, Kerala, India

Address for correspondence: Dr. Soman Manoj, Department of Vitreo-Retinal Service, Chaithanya Eye Hospital and Research Institute, Thiruvananthapuram, Kerala, India.
E-mail: soman.manoj@gmail.com

Submitted: 14-Jun-2021 **Accepted:** 15-Jun-2021 **Published:** 21-Apr-2022

Access this article online	
Website: www.kjophthal.com	Quick Response Code
DOI: 10.4103/kjo.kjo_140_21	

This is an open access journal, and articles are distributed under the terms of the Creative Commons Attribution-NonCommercial-ShareAlike 4.0 License, which allows others to remix, tweak, and build upon the work non-commercially, as long as appropriate credit is given and the new creations are licensed under the identical terms.

For reprints contact: WKHLRPMedknow_reprints@wolterskluwer.com

How to cite this article: Manoj S, Iqbal S, Meleth P, Nair RU. Pachychoroid disease mimicking pattern dystrophy. Kerala J Ophthalmol 2022;34:71-3.

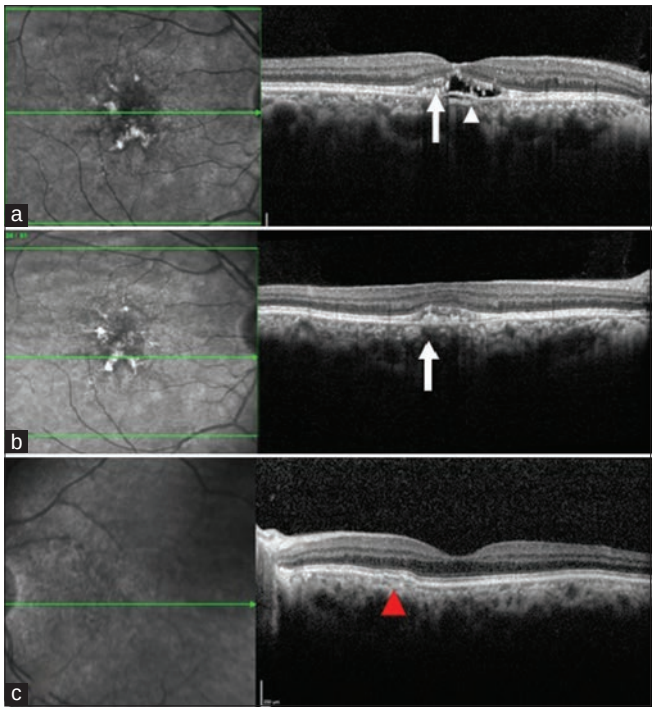

Figure 1: Spectral domain optical coherence tomography showing pachychoroid features in both eyes with hyperreflective lesions in subretinal space (a and b: Arrows) with a shallow pigment epithelial detachment in subfoveal region of the right eye (a: Arrow head) and similar deposition in the left eye (c) and focal extrafoveal double layer sign (c: Red arrow head)

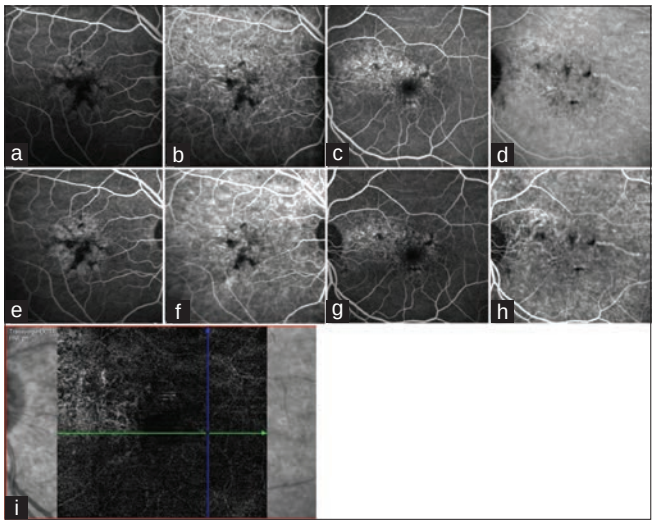

Figure 3: (a-h) Early and late phase combined FFA/ICGA showing window defects and blocked fluorescence corresponding to vitelliform deposits with no evidence of neovascularization network. Note the abnormal network evident on OCTA (i) in the left eye suggestive of nonexudative choroidal neovascular membrane

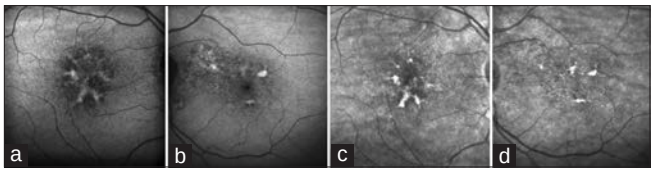

Figure 2: BAF revealed increased autofluorescence from vitelliform deposits in both eyes (a and b), while IR images showed corresponding increased reflectance (c and d)

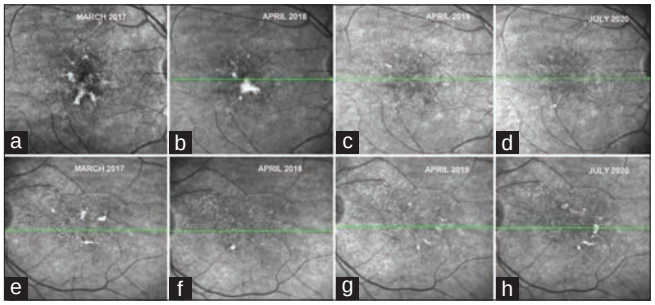

Figure 4: Serial IR images demonstrating in the right eye (a-d) central migration and gradual disappearance of vitelliform lesions and in the left eye (e-h) even though te lesions disappeared initially, it reappeared at different locations in macula

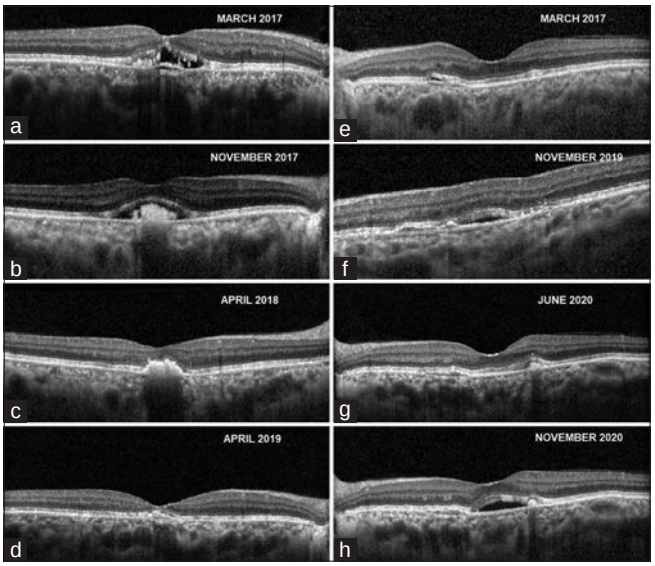

Figure 5: Serial spectral domain-optical coherence tomography images of the right eye revealing flattening of pigment epithelial detachment (a) and central clumping of vitelliform deposits (b) and later resorption (c and d) while the left eye revealed focal double layer sign (e) and development of extrafoveal fluid (f) managed conservatively and later new vitelliform deposition (g) followed by sub macular fluid (h) necessitating treatment. Note that these new hyper reflective lesions appear before the onset of exudation (g)

DISCUSSION

Pattern dystrophies are described as a dominantly inherited conditions characterized by variable macular pigmentary and depository changes.[1,2] The term encompasses 5 key phenotypes summarized by Gass *et al*.[3] including, adult-onset foveomacular vitelliform dystrophy, butterfly-shaped pigment dystrophy, reticular dystrophy of the pigment epithelium, multifocal pattern dystrophy simulating fundus flavimaculatus, and fundus pulverulentus. These findings are often attributed to gene mutations including PRPH 2, BEST1, ABCA4, CTNNA1, and IMPG1.[4] Although many

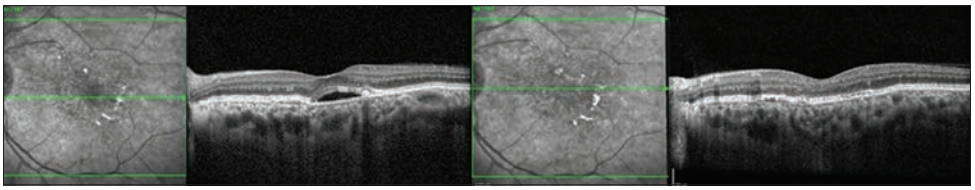

Figure 6: Posttreatment spectral domain optical coherence tomography images showing resolution of subretinal fluid and persistent reflective deposits on IR imaging

eyes having primary pattern dystrophy with vitelliform deposits are misdiagnosed as AMD, CSCR, or nonspecific RPE changes,[5] the converse also do occur. Entities such as pachychoroidopathy could present with findings simulating pattern dystrophy.[6]

The older age of the patient,[7] absence of family history,[7] asymmetrical features,[7] appearance of recurrent new deposition, typical choroidal OCT features, and central migration of the deposits as seen in this case could differentiate this mimic from primary pattern dystrophy. Although the finding of PEDs suggests a primary choroidal disease, PEDs have been reported in some forms of Pattern dystrophy as well.[8]

In pachychoroid eyes, primary RPE dysfunction and poor phagocytosis of shed outer segments resulting from compressed choriocapillaris secondary to dilated outer choroidal vessels lead to vitelliform deposition as was seen at baseline in both eyes. Spontaneous resolution occurs when there is sufficient photoreceptor loss to allow for the normal mechanisms of photoreceptor outer segment turnover to "catch up," whereby RPE phagocytosis of the abnormal subretinal material may occur.[9] This was demonstrable in the right eye in our case. However, the prevalent underlying nonexudative CNVM and later the exudative CNVM could have contributed to recurrent accumulation of vitelliform deposits in the left eye. Thus, unlike other causes of AVL, pachychoroid eyes could have recurrent vitelliform deposits.

This case helps us to understand the relevance of multimodal imaging including IR imaging in eyes with vitelliform deposition that mimic pattern dystrophy. The case also highlights the occurrence of vitelliform lesions in pachychoroid eyes which may be a useful clue when we follow-up these cases as some of these deposits may herald the transformation into exudative CNVM.

Declaration of patient consent

The authors certify that they have obtained all appropriate patient consent forms. In the form the patient(s) has/have given his/her/their consent for his/her/their images and other clinical information to be reported in the journal. The patients understand that their names and initials will not be published and due efforts will be made to conceal their identity, but anonymity cannot be guaranteed.

Financial support and sponsorship

Nil.

Conflicts of interest

There are no conflicts of interest.

REFERENCES

1. Hsieh RC, Fine BS, Lyons JS. Patterned dystrophies of the retinal pigment epithelium. Arch Ophthalmol 1977;95:429-35.
2. Watzke RC, Folk JC, Lang RM. Pattern dystrophy of the retinal pigment epithelium. Ophthalmology 1982;89:1400-6.
3. Gass JD. Stereoscopic Atlas of Macular Diseases: Diagnosis and Treatment. Missouri, MO: Mosby; 1997.
4. Stone EM, Andorf JL, Whitmore SS, DeLuca AP, Giacalone JC, Streb LM, *et al.* Clinically focused molecular investigation of 1000 consecutive families with inherited retinal disease. Ophthalmology 2017;124:1314-31.
5. Ozkaya A, Garip R, Nur Tarakcioglu H, Alkin Z, Taskapili M. Clinical and imaging findings of pattern dystrophy subtypes; Diagnostic errors and unnecessary treatment in clinical practice. J Fr Ophtalmol 2018;41:21-9.
6. Warrow DJ, Hoang QV, Freund KB. Pachychoroid pigment epitheliopathy. Retina 2013;33:1659-72.
7. Hanif AM, Yan J, Jain N. Pattern dystrophy: An imprecise diagnosis in the age of precision medicine. Int Ophthalmol Clin 2019;59:173-94.
8. Puche N, Querques G, Benhamou N, Tick S, Mimoun G, Martinelli D, *et al.* High-resolution spectral domain optical coherence tomography features in adult onset foveomacular vitelliform dystrophy. Br J Ophthalmol 2010;94:1190-6.
9. Freund KB, Laud K, Lima LH, Spaide RF, Zweifel S, Yannuzzi LA. Acquired vitelliform lesions: Correlation of clinical findings and multiple imaging analyses. Retina 2011;31:13-25.

Photo Essay

A white daisy on intraocular lens

ABSTRACT

We report two patients with precipitation of Pseudo-exfoliative material (PXF) material on intraocular lens (IOL), a rare entity, years after uneventful cataract surgery. The PXF material was present on the anterior surface of the IOL optic in a characteristic radiating spoke-like manner, a pattern resembling shape of a white daisy flower. Emphasis is given on differentiating features between PXF deposition on natural lens and PXF deposition on IOL. Furthermore, how opacification of IOL is different from PXF on IOL is briefly explained. In the first case, PXF deposits were not found elsewhere except on anterior IOL surface and in the second patient, pupillary involvement was also noted along with settling on IOL optic. The fellow eyes in both the patients did not have PXF. PXF on IOL is a vital sign and should not be overlooked as it can be the only clue warranting thorough glaucoma evaluation.

Keywords: Intraocular lens opacification, pseudoexfoliation, PXF glaucoma

PHOTOESSAY

Case 1 involves a 73-year-old male with a history of right eye (RE) cataract surgery in 2016. Best corrected visual acuity (BCVA) was 20/20 and IOP was16 mmHg. Slit-lamp biomicroscopy revealed radial striations of pseudo-exfoliative (PXF) deposits on the anterior surface of intraocular lens (IOL) [Figures 1 and 2].

Case 2 involves a 68-year-old male with a history of RE cataract surgery in 2014. BCVA and IOP were 20/200 and 20 mmHg, respectively. Slit-lamp examination revealed PXF deposits on IOL similar to case 1 [Figure 3].

Both the cases had open-angle on gonioscopy, with a cup-to-disc ratio of 0.3:1 and 0.7:1, respectively. Only case 2 had PXF at pupillary margins. Left eye examination was unremarkable in both the patients. They were diagnosed as pseudo-exfoliative syndrome (PXFS) and pseudo-exfoliative open-angle glaucoma, respectively.

PXFS has a prevalence of about 5% after 40 years of age. The incidence of glaucoma at diagnosis of PXFS is 26%.[1] The PXF material is synthesized by nonpigmented ciliary epithelial

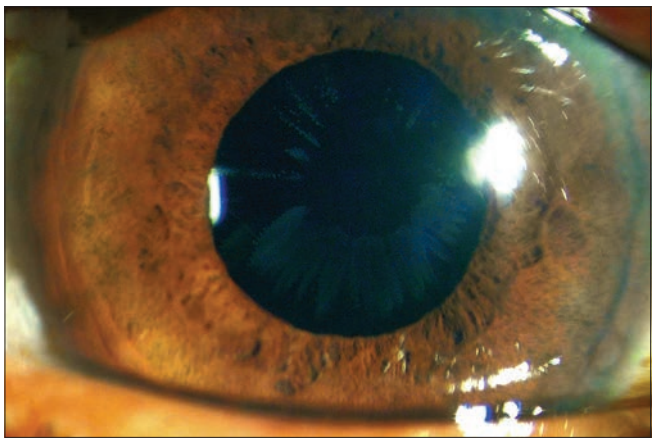

Figure 1: Slit-lamp image of case 1 in direct diffuse illumination showing pseudo-exfoliation deposits in a concentric ring of radiating spoke-like pattern inferiorly and scattered dot-like pattern superiorly in the intermediate zone of anterior surface of hydrophilic-acrylic intraocular lens optic, resembling petals of a white daisy flower

Prateek Jain, Pooja Sah, Anshuman Pattnaik

Department of Community Ophthalmology, Global Hospital Institute of Ophthalmology, Sirohi, Rajasthan, India

Address for correspondence: Dr. Prateek Jain,
Global Hospital Institute of Ophthalmology, Abu Road,
Sirohi - 307 510, Rajasthan, India.
E-mail: docprateekjain@gmail.com

Submitted: 25-Aug-2021 **Revised:** 30-Aug-2021
Accepted: 10-Sep-2021 **Published:** 21-Apr-2022

Access this article online	
Website: www.kjophthal.com	Quick Response Code
DOI: 10.4103/kjo.kjo_184_21	

This is an open access journal, and articles are distributed under the terms of the Creative Commons Attribution-NonCommercial-ShareAlike 4.0 License, which allows others to remix, tweak, and build upon the work non-commercially, as long as appropriate credit is given and the new creations are licensed under the identical terms.

For reprints contact: WKHLRPMedknow_reprints@wolterskluwer.com

How to cite this article: Jain P, Sah P, Pattnaik A. A white daisy on intraocular lens. Kerala J Ophthalmol 2022;34:74-5.



Figure 2: Slit-lamp images of case 1. (a) Direct focal illumination (b) Retro-illumination

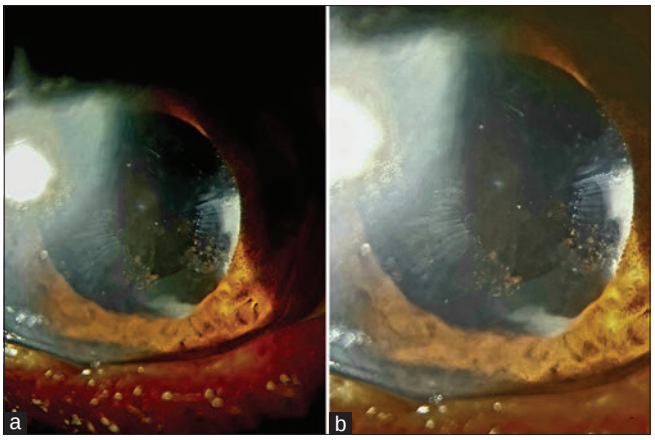

Figure 3: Slit-lamp image of case 2 showing loss of pupillary ruff, mid-peripheral radiating spoke-like PXF deposits (similar to case 1) on anterior surface of PMMA intraocular lens. Residual cortex can be noted lying in the bag. (a) Image at ×10, (b) Image at ×16 magnification

cells, trabecular endothelial cells, vascular endothelial cells of iris, and preequatorial lens epithelial cells.[2]

The settling of PXF on natural lens occurs in "target-sign" pattern with deposits at the central and peripheral zones.[3] The friction between iris and lens prevents its deposition in intermediate zone. Exactly, a reverse pattern is noted in the pseudophakic eye. Only intermediate zone carries PXF owing to greater iris to IOL distance and PXF being washed away by aqueous from central and peripheral zones.[2] Conditions like IOL in the sulcus or zonular weakness bring IOL close to iris and stimulate PXF production by ciliary body followed by its precipitation over IOL.[4] Both of our patients had IOL placed in the bag, thus making this report unique.

It is vital to differentiate PXF on IOL from the opacification of IOL. IOL opacification involves alteration of IOL material whereas PXF deposition occurs on IOL surface only.[5]

PXF on IOL is a rare entity and can be the only sign in diagnosing glaucoma before it progresses to the "point of no-return."

Acknowledgments

The authors acknowledge the guidance of Dr. V C Bhatnagar, Head of Department and Medical Superintendent, Global Hospital Institute of Ophthalmology.

Declaration of patient consent

The authors certify that they have obtained all appropriate patient consent forms. In the form the patient (s) has/have given his/her/their consent for his/her/their images and other clinical information to be reported in the journal. The patients understand that their names and initial s will not be published and due efforts will be made to conceal their identity, but anonymity cannot be guaranteed.

Financial support and sponsorship

Nil.

Conflicts of interest

There are no conflicts of interest.

REFERENCES

1. Yasar E, Yildirim N, Gursoy E, Colak H. Prevalence of pseudoexfoliation syndrome and its association with ocular and systemic diseases. Int J Ophthalmol 2017;10:128-34.
2. Bonafonte Marquez E, Bonafonte Royo S. Bilateral pseudoexfoliation deposits on intraocular lens implants. Case Rep Ophthalmol Med 2015;2015:560508.
3. Laul A, Fabrykowsi M. Tailor your Approach to PXG Management. Review of Optometry; July 15, 2014. Availablefrom: https://www.reviewofoptometry.com/article/tailor-your-approach-to-pxg-management. [Last accessed on 2021May 21].
4. Park KA, Kee C. Pseudoexfoliative material on the IOL surface and development of glaucoma after cataract surgery in patients with pseudoexfoliation syndrome. J Cataract Refract Surg 2007;33:1815-8.
5. Jain P, Pattnaik A, Purohit NB. Appraisal of two fuzzy intraocular lens. Indian J Ophthalmol Case Rep 2021;1:196-7.

Variables and risk

The basic building blocks of biostatistics are called variables. While critically analyzing a study, the first step is to break down the primary outcome measure to find out which variable is being studied. Then, determine whether it is a continuous or categorical variable.

CATEGORICAL VARIABLES

These are the variables that can be counted and hence do not have a unit. For example, the number of corneal abrasions with an infiltrate, stages of diabetic retinopathy, and the number of cases with qualified success after trabeculectomy.

CONTINUOUS VARIABLES

Those variables that can be measured and hence have a unit are continuous variables.

For example, intraocular pressure in mmHg, retinal nerve fiber layer thickness in µm, and visual acuity in logMAR.

Both these types of variables can be described, analyzed, and presented in two important ways:

DESCRIPTIVE STATISTICS

For comparative studies such as randomized control trials or cohort or case–control studies, the descriptive statistics show how the groups (two or more) are as similar to each other as can be achieved.

It is important to note that randomization does not yield perfectly matched groups. If, in a study, the groups are perfectly matched, then that raises a red flag. The degree of matching between the groups is given by a *P* value for the variable.

If there is an observable dissimilarity in the distribution of a given variable between groups, it may mean a selection bias or a break in allocation concealment. If such variable(s) is present, look if an explanation has been provided for, in the discussion of the study and decide if it is a satisfactory explanation or not.

In a multicenter study, look whether one or few centers have a big difference of allocation.

The categorical variables are expressed as percentages or proportions. For ease of statistical purposes, the categorical variables are best described in a dichotomous form, for example., disease is present or absent.

Before the continuous variables are described, first check to see if they have a normal distribution or not.

The easiest way is to draw a histogram of the dataset. The normal distribution shows the typical Bell's Curve.

Statistical software utilizes the Kolmogorov–Smirnov test or the Shapiro–Wilk test for best results to determine if the distribution is normal or not.

If the standard deviation (S.D) is less than half of the mean, then the distribution is assumed to be normal.

The continuous variables are described with a measure of central tendency and a measure of spread. If the distribution is normal, then mean and S.D are used to describe the continuous variable. In a nonnormal distribution also called as nonparametric distribution, the median with interquartile range (IQR) is the preferred description. Median is the value in the middle of the distribution with 50% of values higher than it and 50% of values lower than it. The range of values within which 50% of values reside is called as IQR. The lower band of IQR is called as first quartile (Q1) and the upper band of IQR is called as third quartile (Q3) where 25% of the values are higher than Q3. If there are extreme values in a distribution, also called as outliers, they will distort the range and, therefore, the normal distribution. This can also be assessed by looking how close the mean and the median are to each other.

ANALYTIC STATISTICS

Analytic statistics describe the analysis of statistics which can be done as:

1. Difference between variables
2. Correlation between variables

© 2022 Kerala Journal of Ophthalmology | Published by Wolters Kluwer - Medknow

3. Association between variables.

Let us look at analytic statistics with respect to a disease or a health-related event. The most important term in this regard is a risk.

Risk = No. of people with the given disease or health-related event.

Population of people in that place at a given time:

Often, we are interested in comparing the risk between different groups to look for an association between an intervention and an event. We use a 2 × 2 table.

The risk of development of the event in the intervention group Ri = $\frac{a}{a+b}$

The risk of development of the event in the comparator group Rc = $\frac{c}{c+d}$

The various analytic statistics that can be used with risk are:

Absolute risk difference

It is the difference between the risk in the intervention group and the risk in the comparator group. ARD = Ri-Rc.

Interpretation

If the risk was equal in both groups, then ARD = 0, and hence, there is no association between intervention and event.

If absolute risk difference >0, then there is a positive association and if

ARD <0, then there is a negative association between the intervention and event.

For example, if ARD = −0.064, then we say that there is 6.4% less chance (negative ARD) of the event occurring with the given intervention.

Number needed treat

It is the reciprocal of ARD. Hence, NNT = $\frac{1}{ARD}$

Interpretation

Considering our previous example, where ARD = −0.064, the NNT = 1/0.064 = 15.625 (rounded to 16).

This means that we must treat 16 people with the intervention to prevent the occurrence of the event in one person. Hence, NNT is a more clinically relevant parameter.

Relative risk

It is also known as the risk ratio, and it is the ratio of the risk in the treatment group to the risk in the no treatment (comparator) group.

$$RR = \frac{Ri}{Rc}$$

Interpretation

For example, if relative risk (RR) = 0.40, then we may interpret that the risk of the event occurring in the treatment group is 40% of the risk in the no treatment (comparator) group.

Odds ratio

Before we talk of odds ratio (OR), we must know the meaning of odds.

Hence, odds of an event occurring in a given period of time =

$$\frac{number\ of\ times\ an\ event\ occured}{number\ of\ times\ an\ event\ did\ not\ occur}$$

The odds of raining on a given day or the odds of a horse winning a derby are common terms used in this regard.

The OR is the ratio of odds of the event occurring in the intervention group to the odds in the comparator group.

Interpretation of odds ratio or relative risk

If OR or RR = 1, then there is no association between intervention and the event.

If OR or RR >1, then there is a positive association.

If OR or RR <1, then there is a negative association. Hence, if OR = 0.40, then it can be interpreted as the odds of developing the event is 40% less in the intervention group as compared to the comparator group.

Although OR and RR may appear similar, it is not always so. If the event is very common, then OR and RR are vastly different.

Mean difference

In the case of continuous variables, the measure of association is the mean difference. It is the difference between the mean in the treatment group (mean [T/t]) and the mean in the comparator group (mean [Comp]). It is similar to ARD with respect to interpretation.

MD = Mean (T/t)-mean (Comp).

Financial support and sponsorship

Nil.

Conflicts of interest

There are no conflicts of interest.

Smita Narayanan

Additional Professor, Regional Institute of Ophthalmology, Thiruvananthapuram, Kerala, India

Address for correspondence: Dr. Smita Narayanan, Regional Institute of Ophthalmology, Thiruvananthapuram, Kerala, India.
E-mail: drsmita.narendranath@gmail.com

This is an open access journal, and articles are distributed under the terms of the Creative Commons Attribution-NonCommercial-ShareAlike 4.0 License, which allows others to remix, tweak, and build upon the work non-commercially, as long as appropriate credit is given and the new creations are licensed under the identical terms.

Submitted: 27-Jan-2022 **Revised:** 28-Jan-2022
Accepted: 28-Jan-2022 **Published:** 21-Apr-2022

Access this article online	
Website: www.kjophthal.com	Quick Response Code
DOI: 10.4103/kjo.kjo_16_22	

How to cite this article: Narayanan S. Variables and risk. Kerala J Ophthalmol 2022;34:76-8.

CATARACT SURGERY IN PATIENTS WITH CORNEAL OPACITIES

Citation: Ho YJ, Sun CC, Chen HC. Cataract surgery in patients with corneal opacities. BMC Ophthalmol 2018 Apr 23;18(1):106. DOI: 10.1186/s12886-018-0765-7. PMID: 29685130; PMCID: PMC5913879.

This study concluded that phacoemulsification (PE) and intraocular lens (IOL) implantation in selected cases of coexisting cataracts and corneal opacities are safe. The authors concluded that PE and IOL could provide suboptimal but long-term vision in cases where penetrating keratoplasty is not possible or cases at high risk of graft failure. They concluded that anterior-segment optical coherence tomography (ASOCT) is a simple tool to predict visual outcomes after cataract surgery in corneas with opacity.

The study title is not specific enough and does not provide us with information on the scope or extent of the study. The authors state that the primary aim was to report the visual outcomes and complications in patients undergoing cataract surgery in eyes with coexisting corneal opacities, while the secondary aim was to evaluate whether ASOCT can be used as an alternative objective modality to predict visual prognosis. The authors hypothesized that cataract surgery (PE) with IOL, as an isolated procedure, can provide timely visual rehabilitation in eyes with corneal opacities. They also state that this is the first report to evaluate and compare nontransparent cornea with densitometry and new OCT grading methods. The authors establish that the use of ASOCT assessing eyes with corneal opacity and cataracts is the gap in the literature that they aim to address.

An appropriate study design is essential to answer the research question. The authors mention that they used a retrospective design and a descriptive study. The authors, however, do not provide additional details on the design and state they did a review of the medical case records. The term descriptive is a broad term that can cover several study designs, while the term retrospective is an element of time that can factor into the study design. However, both terms, retrospective and descriptive, do not provide sufficient detail regarding the study design used. Retrospective designs may be simpler to do, less time-consuming, and less costly, especially when cases are fewer but carry a higher risk of confounding and bias compared to a prospective study. Lack of adequate or complete documentation and lack of standardization of measures are other limitations of a retrospective study. However, pragmatically, we must also consider the distribution of the condition of interest and the caseload, and a retrospective may be more feasible than a prospective study where there are constraints of time and caseload.

In this study, the group of interest was people with coexisting cataracts and corneal opacity where Penetrating Kerato Plasty (PKP) cannot be done. This group can be further divided into a group of patients where cataracts can be done and a group where cataract surgery cannot be done. When we compare two groups, to be sure that whatever result we got did not occur by chance, the two groups must have a reasonable number of the study population. The authors mention that they have studied the records of 23 eyes in 19 patients based on the inclusion and exclusion criteria. Each participant underwent a detailed assessment that included collection of demographic details, visual acuity assessments, Lens Opacities Classification System III (LOCS III) grading of the lens, fundus examinations and B scan ultrasonography, grading of the corneal haze by two observers using the corneal haze in accordance with modified VISX protocol, manual demarcation of the boundary of corneal opacification and measurement of size using Image J software (National Institutes of Health, Maryland), estimation of the percentage of opacity occupying central corneal region, assessment of the density of corneal opacity using ASOCT, and measurement of the backscatter of the cornea by cornea densitometry using rotating Scheimpflug camera. The authors do not mention the number of observers who performed the various assessments, the standardization procedures and agreement between observers, and how conflicts in measurements were resolved. These assessments are not usually performed as part of a routine clinical examination, and hence, there is the possibility of a selection bias based on who received these assessments.

The authors mention that all participants underwent a PE with IOL under topical anesthesia with the same techniques but do not mention the number of operating surgeons. Postoperatively, patients were examined on postoperative days 1, 3, and 7, then 1 month, and every 3–4 months thereafter. A complete ophthalmic examination including Uncorrected visual acuity (UCVA), Best corrected visual acuity (BCVA), keratometry, tonometry, slit-lamp examination, endothelial cell density, central corneal thickness, and fundus examination was performed at each follow-up visit.

There are several aspects to consider regarding the methods. These include the sample size, the selection of the study subjects, the assessment of the variables of interest and lack of information on standardization, agreement, and completeness of data, and the possible variability in outcomes based on the skills of the operating surgeon. The authors mention a retrospective, case record-based review as a design but ideally should have considered a pre–postinterventional study design. A pre–postinterventional study design is more suitable as the authors look at changes postintervention in a series of patients.

The authors have assessed the normality of data distribution and chosen Spearman's correlation analysis to report on associations and linear regression to report on the fit of the data. There are several limitations in the presentation of the data. The mean age is provided in the demographic details, but the range of ages or median age is not provided. The authors have included trauma with traumatic cataracts and herpes as causes for corneal opacification. Recurrence of herpes can impact visual outcomes and must be considered as poor visual outcomes can be attributed to an underlying cause of the corneal opacity rather than lens removal. The authors present that nearly 30%–40% had opacities that did not involve the visual axis. The percentage area of opacity involving the central ellipse, density of corneal opacity, and severity was not available for all cases. In Table 2 of the article, the preoperative endothelial cell density is not available for 16 of 23 eyes, and 14 of 23 eyes did not have preoperative corneal thickness assessments. The authors have included two eyes with PKP in the study even though the Inclusion Criteria was to include eyes where it was not possible to do PKP. The authors also included eyes amblyopia and pale disc that affects the final visual outcome.

These results show several limitations. The number of cases is few in the first instance (23 eyes of 19 patients), and a significant proportion of these 23 eyes had incomplete preoperative data. The authors mention the results of Spearman's correlation analysis to report on the association of corneal opacity with visual outcomes.

The manuscript has several limitations that preclude the translation of these results to clinical practice. (1) There is an inadequate description of the study design to assess if that is appropriate to answer the study question. (2) The sample size is inadequate for an association study, and they should have described this as a case series instead. A case series is useful to generate a hypothesis but does not provide conclusive evidence. (3) The small sample size and lack of complete data is a major limitation to explore for associations. They should have instead used the case series approach to generate a hypothesis and design a prospective study. (4) The statistical tests are not appropriate. A correlation analysis is not ideal to measure associations, and a regression model is preferred in such instances. However, it is preferable to defer formal statistical testing of hypothesis in this study considering the small sample size and the incomplete data and the higher chance for erroneous results. (5) Figure C does not show a monotonic relationship, so a correlation analysis is not appropriate.

My interpretation of this article is that it addresses a clinically relevant problem. However, the results of this study cannot be translated to clinical practice due to the limitations in the methodology used to answer the question. The conclusions of the authors are not supported by their data or research methods. We need prospective studies with adequate sample size and appropriate sample size to obtain valid and reliable results. This may have to be a multicenter study considering the limitations of obtaining an adequate sample size from a single center. The study comes under the scope of an interventional study, and a randomized clinical trial is gold standard. Alternate designs such as a pre–postinterventional design and a cohort study design may be considered as a pragmatic alternate.

Financial support and sponsorship

Nil.

Conflicts of interest

There are no conflicts of interest.

Aishwarya Sadanand

Department of Ophthalmology, Kozhikode Medical College, Kozhikode, Kerala, India

Address for correspondence: Dr. Aishwarya Sadanand, Department of Ophthalmology, Kozhikode Medical College, Kozhikode, Kerala, India.
E-mail: sadanandaishwarya@gmail.com

This is an open access journal, and articles are distributed under the terms of the Creative Commons Attribution-NonCommercial-ShareAlike 4.0 License, which allows others to remix, tweak, and build upon the work non-commercially, as long as appropriate credit is given and the new creations are licensed under the identical terms.

Submitted: 20-Jan-2022 **Revised:** 24-Jan-2022
Accepted: 26-Jan-2022 **Published:** 21-Apr-2022

Access this article online	
Website: www.kjophthal.com	Quick Response Code
DOI: 10.4103/kjo.kjo_9_22	

How to cite this article: Sadanand A. Journal Review. Kerala J Ophthalmol 2022;34:79-80.

© 2022 Kerala Journal of Ophthalmology | Published by Wolters Kluwer -Medknow

MULLER CELL CONE-ASSOCIATED FOVEAL DETACHMENT AS A RISK FACTOR FOR VISUAL ACUITY LOSS AFTER GLAUCOMA FILTERING SURGERY

Citation: Chihara E, Chihara T, Matsuzaki S. Muller cell cone-associated foveal detachment as a risk factor for visual acuity loss after glaucoma filtering surgery. Retina. 2021;41:2571-2577 DOI: 10.1097/IAE.0000000000003216.

Short summary of the article: The authors assessed the association of hypotony-associated foveal lesions (FovLs) as a risk factor for long-standing visual loss after filtering surgery with mitomycin C for glaucoma. They concluded that Müller cell cone-associated FovLs lead to long-lasting visual acuity loss after filtering surgery.

An estimated 4.5 million people with moderate-to-severe vision impairment and 3.2 million people have blindness attributable to glaucoma. There are an estimated 12 million people with glaucoma in India and 1.5 million people with blindness attributable to glaucoma in India. Filtering surgery that aims at sustained management of intraocular pressures, thereby visual acuity is a recognized strategy in the management of glaucoma. However, visual acuity loss of four or more lines is found in 14.6% of patients after trabeculectomy with adjunctive mitomycin C, with permanent visual acuity loss reported in 28.3% of cases. Anterior segment complications may lead to short-term visual acuity loss after filtering surgery while posterior segment causes of visual acuity loss are usually long lasting. Hypotony maculopathy (HM) occurred in up to 20% of patients and is identified as a risk factor for visual acuity loss following trabeculectomy. However, visual acuity deterioration is also found in patients who developed hypotony following trabeculectomy without any manifest clinical features of HM. Eyes such as hypotony following trabeculectomy were noted to have 40 μm increase in central retinal thickness. Subclinical level macular abnormalities were noted in more than 50% of eyes with posttrabeculectomy hypotony and the presence of epiretinal membranes (ERM) was also documented in such cases. The authors hypothesized that hypotony-associated FovLs and postsurgical outer retinal changes after trabeculectomy with mitomycin C may lead to postsurgery visual acuity loss and designed a study to determine postsurgical changes in the outer retina assessed using optical coherence tomography (OCT) in those patients who underwent trabeculectomy with mitomycin C, and to assess the effect of ERM on posttrabeculectomy visual acuity deterioration.

There are several study designs that are possible to address these aims. The study involves an intervention, and a randomized clinical trial (RCT) can be considered. However, the study is not looking at a comparison of the effectiveness of interventions, and hence a RCT may not be necessary. Alternate designs that can be considered include a pre–post interventional design that compares presurgical baseline with postsurgical changes in the same subject and an interventional case series design. Both these alternate designs can be either prospective or retrospective. The retrospective design has limitations on selection bias, standardization of assessments, and completeness of data while offering benefits of faster completion of the study. The authors chose to do a retrospective interventional case series to answer the study questions. This may be a pragmatic choice given the relative rarity of the condition and the ability to recruit a reasonable number of cases in a reasonable period. However, the choice of this design limits the interpretation of results only to the generation of a hypothesis and does not allow for a formal statistical testing of hypothesis and generation of conclusive evidence of any association. The lack of association in a case series may be a true lack of association or maybe due to an inadequate sample size.

The authors recruited one eye each of 44 patients for the study. Six of these 44 patients dropped out after 6 months of follow-up and complete details could be analyzed in the remaining 38 patients. The data of the 6 patients who dropped out were treated as missing statistical data in the study. All recruited patients underwent trabeculectomy with mitomycin C and postsurgical assessments were done at 1 week, and 1, 3, 6, and 12 months after surgery. The authors studied the mean retinal thickness at the central area, inner paramacular and outer paramacular area were studied using the spectral domain-OCT. HM was defined as a low intraocular pressure (IOP), ophthalmoscopic radial retinal folds, choroidal folds, tortuous vessels, optic disk edema, and/or the presence of intraretinal fluid and choroidal folds detected using OCT. The presence of ERM, choroidal folds, and foveal detachment was assessed by two independent researchers using crossline and retinal map images from the device and lesions were judged as positive when both researchers agreed on the findings. The authors do not mention the agreement between observers and do not mention if postsurgery assessments are masked to presurgery assessment results. A selection bias is also possible depending on the patient population that accesses care at the study setting (the distribution of severity of cases) and the personnel recruiting cases.

The key variables to answer the research question includes Best corrected Visual Acuity (BCVA) compared to presurgery VA, postsurgery changes in IOP (hypotony) and postsurgery changes in the retina compared to presurgery assessment based on OCT findings. The changes in means can be assessed using parametric tests such as a paired *t*-test or analysis of variance and nonparametric tests such as the Wilcoxon rank-sum test or Mann–Whitney *U*-test. A nonparametric test will be preferable as the distribution will not be normal given the low sample size. Changes in proportions can be assessed using a Fisher's exact test rather than a Chi-square test as we anticipate cell counts <5 in a 2×2 table as the sample size is low. The authors performed nonparametric tests for means and Fisher's exact test for proportions. A regression analysis was performed to explore associations. The use of a regression model is appropriate for associations, although formal testing of hypothesis in a case series must be interpreted with caution due to inadequate sample size. Regression is indicated when one of the variables is an outcome and the other one is a potential predictor of that outcome, in a cause-and-effect relationship. If the outcome is a continuous variable, a linear regression model is indicated, and, if it is binary, a logistic regression is used. The authors also did a nonparametric Spearman correlation for visual acuity and IOP, although this is not essential within the context of their aims. A key aspect to remember while interpreting results is that the study is a case series design, the statistical testing in a case series design is to provide evidence to support the hypothesis or to generate a hypothesis, to determine sample sizes for further studies, and that the results do not provide conclusive evidence of a lack of association.

The authors reported a significant reduction in VA at 3 months ($P < 0.001$) and 12 months ($P = 0.0046$, Wilcoxon signed-rank test). After a large drop in the VA at 3 months, there was a mild recovery of the Early Treatment Diabetic Retinopathy Study letter score from 77.1 ± 14.7 letters to 80.7 ± 11.4 letters at 12 months; however, this difference was not statistically significant ($P = 0.155$, Wilcoxon signed-rank test). The difference in deterioration of the VA between the phakic and pseudophakic eyes was not statistically significant. The association between the deterioration of VA at 3 months or 12 months and presurgical IOP, the number of presurgical medications, lowest postsurgical IOP, and postsurgical IOP at 1 week was not statistically significant in a forward–backward stepwise multiple regression analysis. Five of the 44 patients had foveal detachment and HM was noted in 13 of the 44 eyes. ERM was found in five of the six eyes (83%) with FovLs and in seven of the 38 eyes (18%) without FovLs ($P = 0.0037$, Fisher exact test). Five of the 12 eyes (42%) with ERM developed FovLs; however, only one of the 32 eyes (3%) without ERM developed FovLs ($P = 0.013$). Both HM and FovLs were significant independent risk factors for visual acuity deterioration at the 3rd month, but only FovLs were a significant risk factor for visual acuity deterioration at the 12th month. The authors noted paramacular thickness was highest in eyes with foveal detachment possibly mediated by fluid accumulation in the retina by means of increased choroidal effusions that lead to increased retinal thickness following hypotony. The authors suggest that this increase in retinal thickness could be responsible for lifting the Internal limiting membrane (ILM) leading to the foveal detachment. The damage brought about to the ellipsoid zone by the foveal detachment could persist even if the foveal detachment resolves and this could explain why postsurgical FovLs continue to act as a risk factor for visual acuity deterioration at the 12th month. Eighty-three percent of eyes that had FovLs had an ERM as well and imply that in addition to the traction on the retina brought about by the accumulation of intraretinal fluid in the context of hypotony, the presence of ERM could further exacerbate the traction on the retina and lead to foveal detachment. Choroidal folds may lead to changes in the orientation of photoreceptors (Stiles–Crawford effect) and affect VA. In diabetic maculopathy, the first sign of macular lesions is fluid accumulation in the inner retina and detachment of the photoreceptor occurs in an advanced stage of the disease. By contrast, detachment of the photoreceptor occurs in the early stage of hypotony eyes and tends to diminish over time. This suggests that the main cause of FovLs in hypotonia is not the accumulation of exudates but choroidal effusion and mechanical traction on the photoreceptor.

We must consider the limitations of the study design as we explore the translation of these findings to clinical practice. There were no formal sample size estimates reported and the sample size of the study is small (44 eyes). We cannot be sure the lack of significant associations is a true lack of association. This is a single-center study from a tertiary center and based on a single ethnic population. This limits the representativeness of the study, and we cannot be sure the findings may apply to Asian Indian Eyes. The retrospective study has limitations in terms of bias, standardization of measures, and missing data. The authors do not report on coexisting anterior segment factors that may contribute to visual acuity deterioration following trabeculectomy and if they were adjusted for in the regression analysis. The authors do not report the agreement on OCT reading.

My conclusions from this article are that the case series provides insights for a plausible cause of VA loss following

trabeculectomy with mitomycin C, and the structural, functional, and anatomic basis for this cause of loss of visual acuity is biologically plausible. However, we need to study this further as a larger study in Asian Indian eyes before we translate this to routine clinical practice in India. This may need a multicentric study involving glaucoma practices to obtain a reasonable sample size and to optimize representativeness. An additional consideration in the translation to clinical practice is that translation to individual patient care may be optimized if we assess the diagnostic effectiveness of this sign (FovLs) for visual acuity loss and report likelihood ratios and posttest probabilities besides the measures of association as an odds ratio.

Financial support and sponsorship

Nil.

Conflicts of interest

There are no conflicts of interest.

Allen Mathew

Department of Ophthalmology, Regional Institute of Ophthalmology, Thiruvananthapuram, Kerala, India.

E-mail: allenmathew23@gmail.com

This is an open access journal, and articles are distributed under the terms of the Creative Commons Attribution-NonCommercial-ShareAlike 4.0 License, which allows others to remix, tweak, and build upon the work non-commercially, as long as appropriate credit is given and the new creations are licensed under the identical terms.

Submitted: 23-Jan-2022 **Revised:** 24-Jan-2022
Accepted: 27-Jan-2022 **Published:** 21-Apr-2022

Access this article online	
Website: www.kjophthal.com	Quick Response Code
DOI: 10.4103/kjo.kjo_10_22	

How to cite this article: Mathew A. Journal Review. Kerala J Ophthalmol 2022;34:81-3.

© 2022 Kerala Journal of Ophthalmology | Published by Wolters Kluwer -Medknow

Corneal biopsy

CORNEAL BIOPSY

Corneal biopsy is an effective aid in establishing diagnosis in a variety of corneal pathologies.

INDICATIONS OF CORNEAL BIOPSY

1. Infectious corneal processes
   a. Deep suppurative stromal keratitis with no involvement of anterior stroma
   b. Sight threatening or progressive corneal infiltrate exhibiting one or more of the following
      - Inadequate response to proper antimicrobial therapy
      - Culture negative on repeated corneal scrapings
      - Atypical clinical course.
   c. Infectious crystalline keratopathy if cultures not easily obtained with superficial scraping
   d. Suspicion of slow-growing fastidious organisms which are difficult to culture such as acanthamoeba, atypical mycobacteria, and microsporidium.
2. Neoplastic limbal processes
   a. Suspected conjunctival neoplasms with corneal extension.
3. Corneal dystrophies and degenerations
4. Corneal manifestations of systemic diseases
5. Drug-induced changes in cornea.

PRE PROCEDURE EVALUATION

1. Slit-lamp biomicroscopic examination to assess the depth of infiltrating and surrounding corneal thickness
2. Pachymetry can be used to measure the corneal thickness
3. Confocal microscopic examination can be done to identify the presence or absence of infectious organism and in such cases, corneal biopsy can be avoided
4. Topical antimicrobials should be stopped approximately 24 h before performance of biopsy if culture is planned.[1]

INSTRUMENTATION, ANAESTHESIA, AND TECHNIQUES

Setting

Patient lying in supine position under the operating microscope. If patient is very cooperative, all techniques except trap door may be performed with patient seated at slit lamp biomicroscope. Under aseptic precautions operating eye is draped and if necessary speculum is inserted.

Anesthesia

Preservative-free topical anesthetic agent is instilled and if needed, a cotton tip applicator soaked in lidocaine may be held at limbal position where forceps fixation is performed.

Techniques

Different techniques for corneal biopsy are use based on the size and depth of the infiltrate and presence of thinning.

Excisional biopsy

Excisional biopsy is done in smaller peripheral ulcer where ulcer is excised totally [Figure 1].

Incisional biopsy

In larger ulcers, incisional biopsy is done where microtrephines are used to punch and then tissue is dissected deep to infiltrate and multiple incisional biopsies can be taken [Figure 2].

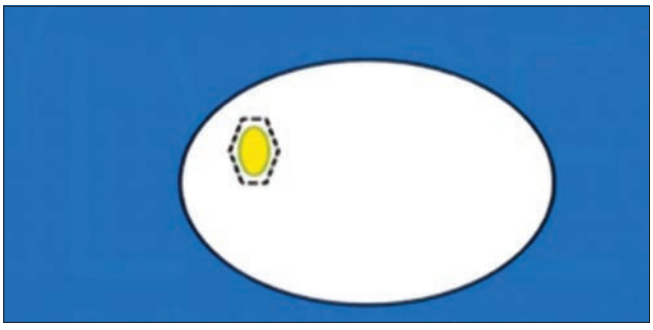

Figure 1: Excisional biopsy



Figure 2: Incisional biopsy

© 2022 Kerala Journal of Ophthalmology | Published by Wolters Kluwer - Medknow



Figure 3: Centrifugal dissection



Figure 4: Lamellar flap biopsy



Figure 5: Trephination using slit lamp biomicroscopy

Centrifugal dissection

In deep and thin ulcers technique of lamellar dissection with centrifugal advancement is used to minimize the risk of perforation [Figure 3].

Lamellar flap biopsy

Used in mid to deep stromal lesions. Stromal tissue anterior to lesions is spared. This helps in decreasing the removal of excess corneal tissue which happens in prelamellar dissection. Incisions are made in surrounding relatively normal cornea and are 3–4 mm long triangular flap dissected at the level of lesion by keeping blade parallel to Descemet's membrane [Figure 4]. Within triangular flap, deeper plane is created from apex to base and a block of tissue is dissected. Bed of dissection is scraped and sent for culture. Flap is reapproximated and sutured with 10.0 nylon suture.[2]

Trephination using slit-lamp biomicroscopy

Topical anesthetic is instilled and a sterile, handheld trephine (2–3 mm dermatological punch) is used at the slit lamp to achieve a partial thickness trephination containing pathological specimen [Figure 5]. The size of the trephine depends on the size of the lesion. Trephine is positioned at the junction of diseased and normal corneal tissue. After the partial thickness trephination, the edge of the lesion in the area of the normal tissue is lifted using 0.12 forceps and dissected off the cornea using a blade.

Femtosecond laser can also be used for corneal biopsWy

SPECIMEN HANDLING AND PROCESSING

Biopsy specimen should be adequate enough to send for both microbiological and histopathological examination, specimen should include at least 1 mm of adjacent clear cornea at the leading edge of the ulcer. Biopsy tissue should be sent as two samples one for microbiological culture in normal saline and one for histopathological examination in 10% formalin.

COMPLICATIONS

- Delayed healing
- Inadvertent perforation
- Visually significant scarring
- Dellen formation
- Astigmatism
- Thinning.

If perforation happens, it results in aqueous humor leakage and/or introduction of infectious organisms into anterior chamber. A simple incision/flap made in cornea is sutured with 10.0 nylon. If not able to maintain deep anterior chamber, may place thin application of cyanoacrylate tissue adhesive over flap followed by bandage contact lens placement. If tissue is necrotic and closure is not possible with sutures/tissue adhesive, then corneal or scleral patch graft can be done.[3]

HOW TO PREVENT PERFORATION?

1. Thorough slit-lamp biomicroscopic examination before the procedure to estimate depth of infiltrate and nearby corneal thickness
2. Ultrasonic pachymetry can be done before lamellar dissection
3. Corneal imaging with optical coherence tomography/

ultrasonography to determine corneal thickness and depth of lesion before dissection.

FOLLOW-UP AND PATIENT INSTRUCTIONS

- Antimicrobial therapy should be restarted after the biopsy
- Treatment is modified according to the results of microbiological and histopathological investigations
- Patient should be instructed not to rub the eye.

Financial support and sponsorship

Nil.

Conflicts of interest

There are no conflicts of interest.

R. B. Radhika Krishnan

Department of Ophthalmology, RIO, TVM, Thiruvananthapuram, Kerala, India

Address for correspondence: Dr. R. B. Radhika Krishnan, Department of Ophthalmology, RIO, TVM, Thiruvananthapuram, Kerala, India.
E-mail: rkrb1781993@gmail.com

REFERENCES

1. Yanoff M, Duker JS. Ophthalmology. Yanoff M, Duker JS: Ophthalmology 5th ed. Edinburgh:Elsevier. 2019;p. 306-7.
2. Alexandrakis G, Haimovici R, Miller D, Alfonso EC. Corneal biopsy in the management of progressive microbial keratitis. Am J Ophthalmol 2000;129:571-6.
3. Weisenthal RW. Basic and Clinical Science Course.Section 8:External Diseases and Cornea American Academy of Ophthalmology 2020-2021..

This is an open access journal, and articles are distributed under the terms of the Creative Commons Attribution-NonCommercial-ShareAlike 4.0 License, which allows others to remix, tweak, and build upon the work non-commercially, as long as appropriate credit is given and the new creations are licensed under the identical terms.

Submitted: 28-Jan-2022 **Revised:** 29-Jan-2022
Accepted: 29-Jan-2022 **Published:** 21-Apr-2022

Access this article online	
Website: www.kjophthal.com	Quick Response Code
DOI: 10.4103/kjo.kjo_19_22	

How to cite this article: Radhika Krishnan RB. Corneal biopsy. Kerala J Ophthalmol 2022;34:84-6.

Dilemma of diagnostic criteria

We read with great interest the excellent article by Gurnani and Kaur titled "Asymptomatic Goldenhar syndrome in an adult."[1] We applaud the efforts of the authors in describing the challenges in detail. However, we would like to highlight an important aspect.

The case has features of Goldenhar syndrome, but if we consider the diagnostic criteria, then only one feature was present out of the minimum two. At least two of the following findings must be present for the diagnosis of this syndrome: unilateral microtia, unilateral mandibular hypoplasia, epibulbar dermoid cysts (unilateral or bilateral), or vertebral malformations.[2] Microtia, unilateral mandibular hypoplasia, and vertebral malformations have not been stated/or were not present?

Financial support and sponsorship
Nil.

Conflicts of interest
There are no conflicts of interest.

Anubhav Chauhan, Deepak Kumar Sharma
Department of Ophthalmology, Shri Lal Bahadur Shastri Government Medical College and Hospital, Mandi, Himachal Pradesh, India

Address for correspondence: Dr. Anubhav Chauhan, Medical Officer(Specialist), Shri Lal Bahadur Shastri Government Medical College and Hospital, Nerchowk, Mandi, Himachal Pradesh, India.
E-mail: chauhan.anubhav2@gmail.com

REFERENCES

1. Gurnani B, Kaur K. Asymptomatic Goldenhar syndrome in an adult. Kerala J Ophthalmol 2021;33:252-3.
2. Ferreira JM, Gonzaga J. Goldenhar syndrome. Rev Bras Oftalmol 2016;75:401-4.

This is an open access journal, and articles are distributed under the terms of the Creative Commons Attribution-NonCommercial-ShareAlike 4.0 License, which allows others to remix, tweak, and build upon the work non-commercially, as long as appropriate credit is given and the new creations are licensed under the identical terms.

Submitted: 08-Dec-2021 **Revised:** 16-Jan-2022
Accepted: 29-Jan-2022 **Published:** 21-Apr-2022

Access this article online	
Website: www.kjophthal.com	Quick Response Code
DOI: 10.4103/kjo.kjo_226_21	

How to cite this article: Chauhan A, Sharma DK. Dilemma of diagnostic criteria. Kerala J Ophthalmol 2022;34:87.

© 2022 Kerala Journal of Ophthalmology | Published by Wolters Kluwer - Medknow

Continuing the service despite the pandemic: Ocular surgery on a COVID-19 patient

Dear Editor,

The first case of novel coronavirus (COVID-19) outbreak in India was reported on January 30, 2020.[1] To date (5.2.22), 3.51 crore people were affected in India. Elective medical care services were shut down with a lot of uncertainty.[2] Ocular surgery on a COVID-19 patient was deferred by two weeks unless there was a risk for potential loss of vision, eye, or life.[3] Ocular injuries if not treated early can lead to sight-threatening complications.[4] This is the report of ocular surgery in COVID patients.

A 5-year-old child presented with left eye subconjunctival foreign body following trauma with a pencil. A globe exploration and foreign body removal under general anesthesia was planned. Although the patient was asymptomatic for COVID-19, due to the ongoing pandemic, a severe acute respiratory syndrome *coronavirus*-2 test was done before surgery.[5] The patient turned positive and surgery was planned in an operation theater designated for COVID patients. After donning level three personal protective equipment (PPE), the outer glove was sterilized with alcohol-based disinfectant, and a sterile gown and sterile gloves were donned.

There was poor control on the microscope's foot pedal because of shoes and PPE; hence, the hand control was used for magnification and focus. Fogging reduced visibility, making the surgery challenging. After conjunctival peritomy, the foreign body (pencil lead) was removed; ensuring that the sclera was intact, the conjunctiva was closed. The conjunctival wound was healthy at 10-day follow-up and the patient was asymptomatic for COVID-19.

Sealing the N95 mask (to prevent air leak to goggles), use of goggles with vent, and cleaning the goggles with the antifog solution could reduce fogging. Prevention of fogging and enhance visibility for good surgical results is imperative for more complicated COVID-positive cases which are likely to present to an ophthalmologist.

Declaration of patient consent

The authors certify that they have obtained all appropriate patient consent forms. In the form the patient (s) has/have given his/her/their consent for his/her/their images and other clinical information to be reported in the journal. The patients understand that their names and initials will not be published and due efforts will be made to conceal their identity, but anonymity cannot be guaranteed.

Financial support and sponsorship

Nil.

Conflicts of interest

There are no conflicts of interest.

Karthikeyan Mahalingam, Somya Kumari, Monika Arora, Ramanjit Sihota

Dr. Rajendra Prasad Centre for Ophthalmic Sciences, All India Institute of Medical Sciences, New Delhi, India

Address for correspondence: Dr. Karthikeyan Mahalingam, Dr. Rajendra Prasad Centre for Ophthalmic Sciences, All India Institute of Medical Sciences, Ansari nagar, New Delhi, India.
E-mail: kalingachit@gmail.com

REFERENCES

1. Cheke RS, Shinde S, Ambhore J, Adhao V, Cheke D. Coronavirus: Hotspot on coronavirus disease 2019 in India. Indian J Med Sci 2020;72:29-34.
2. Reddy JC, Vaddavalli PK, Sharma N, Sachdev MS, Rajashekar YL, Sinha R, *et al.* A new normal with cataract surgery during COVID-19 pandemic. Indian J Ophthalmol 2020;68:1269-76.
3. Sengupta S, Honavar SG, Sachdev MS, Sharma N, Kumar A, Ram J, *et al.* All India Ophthalmological Society – Indian Journal of Ophthalmology consensus statement on preferred practices during the COVID-19 pandemic. Indian J Ophthalmol 2020;68:711-24.
4. Lecuona K. Assessing and managing eye injuries. Community Eye Health 2005;18:101-4.
5. Al-Muharraqi MA. Testing recommendation for COVID-19 (SARS-CoV-2) in patients planned for surgery – Continuing the service and 'suppressing' the pandemic. Br J Oral Maxillofac Surg 2020;58:503-5.

This is an open access journal, and articles are distributed under the terms of the Creative Commons Attribution-NonCommercial-ShareAlike 4.0 License, which allows others to remix, tweak, and build upon the work non-commercially, as long as appropriate credit is given and the new creations are licensed under the identical terms.

Submitted: 06-Jan-2022 **Accepted:** 26-Jan-2022 **Published:** 21-Apr-2022

Access this article online	
Website: www.kjophthal.com	Quick Response Code
DOI: 10.4103/kjo.kjo_2_22	

How to cite this article: Mahalingam K, Kumari S, Arora M, Sihota R. Continuing the service despite the pandemic: Ocular surgery on a COVID-19 patient. Kerala J Ophthalmol 2022;34:88.

© 2022 Kerala Journal of Ophthalmology | Published by Wolters Kluwer - Medknow